




Revista Española de Cirugía Oral y Maxilofacial

www.revistacirugiaoralymaxilofacial.es



Original

Applicability and limitations of lip lift for facial rejuvenation: case series

Andressa Bolognesi Bachesk^{1,2*}, Eder Alberto Sigua-Rodriguez², Marília de Oliveira Coelho Dutra Leal^{1*} and Cláudio Roberto Pacheco Jodas¹

¹Department of Oral and Maxillofacial Surgery. São Leopoldo Mandic College. Campinas/SP, Brasil. ²Department of Oral and Maxillofacial Surgery. Institución Universitaria Colegios de Colombia UNICOC. Bogotá, Colombia

INFORMACIÓN DEL ARTÍCULO

Historia del artículo:

Recibido: 04-12-2023

Aceptado: 15-12-2023

Keywords:

Cosmetic Surgery, lip, cosmetic procedures, rejuvenation.

A B S T R A C T

Introduction: The lips are important structures for facial aesthetics, and methods capable of enhancing their volume and morphology are essential for facial rejuvenation. Lip lift surgery is a treatment option that can shorten lip length, increase the height of the vermilion border, and enhance the exposure of the upper incisor teeth. This article aims to present four case reports with different characteristics that underwent lip lift procedures using the same technique performed by the same surgeon. Additionally, it seeks to elucidate the topic through a literature review.

Material and methods: All cases were approached using the modified bullhorn technique.

Results: Factors such as age, tissue laxity, upper lip length, vermilion border height, and exposure of the upper incisors varied among individuals and are the primary factors in determining the treatment plan.

Discussion: Diagnosis and treatment are discussed because, despite being considered a relatively simple and safe technique that provides a more youthful appearance to the patient, its treatment plan is complex, requiring a thorough clinical evaluation to determine the amount of skin to be excised.

Aplicabilidad y limitaciones del levantamiento de labios para el rejuvenecimiento facial: serie de casos

R E S U M E N

Introducción: Los labios son estructuras importantes para la estética facial, y los métodos capaces de potenciar su volumen y morfología son fundamentales para el rejuvenecimiento facial. La cirugía de levantamiento de labios es una opción de tratamiento que puede acortar la longitud de los labios, aumentar la altura del borde bermellón y mejorar la exposición de los dientes

Palabras clave:

Cirugía estética, labio, procedimientos cosméticos, rejuvenecimiento.

*Correspondence:

E-mail: andressabachesk@gmail.com (Andressa Bolognesi Bachesk).

<http://dx.doi.org/10.20986/recom.2024.1493/2023>

1130-0558/© 2023 SECOM CyC. Publicado por Inspira Network. Este es un artículo Open Access bajo la licencia CC BY-NC-ND (<http://creativecommons.org/licenses/by-nc-nd/4.0/>).

incisivos superiores. Este artículo tiene como objetivo presentar cuatro reportes de casos con diferentes características que fueron sometidos a procedimientos de *lifting* de labios, utilizando la misma técnica realizada por el mismo cirujano. Además, se busca dilucidar el tema a través de una revisión de la literatura.

Material y métodos: Todos los casos fueron abordados mediante la técnica del megáfono modificado. *Resultados:* Factores como la edad, la laxitud del tejido, la longitud del labio superior, la altura del borde bermellón y la exposición de los incisivos superiores varían entre los individuos y son los factores principales para determinar el plan de tratamiento.

Discusión: Se discute el diagnóstico y el tratamiento porque, a pesar de considerarse una técnica relativamente sencilla y segura que proporciona una apariencia más juvenil al paciente, su plan de tratamiento es complejo, requiriendo una evaluación clínica exhaustiva para determinar la cantidad de piel a extirpar.

INTRODUCTION

Lips are anatomical structures of great aesthetic importance, providing connotations of youth and beauty, but the consequences of aging can significantly alter lip volume and morphology¹. Expected implications include lengthening and flattening of the philtrum and a decrease in lip thickness, horizontal flattening and inversion of the vermilion border, and reduced exposure of the upper incisor teeth at rest and during a smile^{2,3}. With the growing demand for aesthetic procedures, the search for techniques for lip rejuvenation has increased considerably⁴. Currently, there are various possible approaches to improving the appearance of the lips, with fat or hyaluronic acid fillers being the most used techniques. However, these procedures have limitations, and in some patients, they no longer deliver the expected results. In this context, surgical procedures have become necessary to achieve better outcomes^{5,6}.

The lip lift is a technique characterized by the partial removal of tissue from the philtrum, capable of reducing the length of the upper lip and increasing the height and eversion of the vermilion border. As a result, it is possible to increase the exposure of the upper incisor teeth and restore the curvature of the philtrum, which ensures a more youthful appearance for the patient⁷⁻⁹. According to the literature, individuals indicated for lip lift surgery are those with an increased philtrum length, with values greater than 20 mm; increased total lip length, with values greater than 22 mm; upper incisor teeth with exposure of less than 1-2 mm; ideally under 60 years of age; a history of favorable scarring; and good quality and elasticity of the skin¹⁰⁻¹⁴.

Within this approach, there are variations in technique, primarily differentiated by the incision design. In this regard, the bullhorn-type variant has proven to be safe and effective in its aesthetic results^{5,12}. Therefore, the aim of this study is to describe four clinical cases treated with this lip lift technique. Additionally, through a literature review, we aim to elucidate this surgical approach, its indications, and its characteristics. Thus, the article can be useful for clinical surgeons to plan surgery for diverse patients who commonly seek the procedure.

METHODS

The procedures in all four cases were performed by the same surgeon following the same surgical technique, using the standard bullhorn approach. Incision markings were made with a fine tip marking pen, drawn at the base of the nose and extending from one nostril wing to the other. The lateral margins of the incision extended superiorly to three-quarters of the vertical height of the nostril wing. The lower incision line was created using a caliper, in a linear, uniform fashion, parallel to the upper incision, and connected at the ends with tapered edges. Vertical reference markings were made to facilitate symmetric wound closure.

All cases were performed in an outpatient setting under local anesthesia, with infiltration of 2 % lidocaine combined with 1:100,000 epinephrine, including bilateral blocking of the infraorbital nerves and additional infiltrative anesthesia. Following the pre-marked design, the upper incisions were initiated using a No. 15 scalpel blade directed perpendicular to the skin, with depth extended to the subcutaneous tissue. This was also done for the lower incisions. The skin and subcutaneous tissue were excised in a wedge shape, overlying the orbicularis oris muscle, in a bullhorn shape. Subsequently, subcutaneous dissection directed inferiorly to the upper lip vermilion was performed, including the full thickness of the skin. Careful hemostasis of the area was then achieved through compression. Sutures were placed in layers, following the reference markings made earlier. Wounds were closed sequentially from the center to the sides, using 4.0 polyglactin sutures in the deep subcutaneous and muscular tissue. Polyglactin 5.0 sutures were used for closing the superficial subcutaneous tissue, and 6.0 mono nylon interrupted sutures were used for the skin.

All patients were provided with the same postoperative care instructions and received the same medication prescription. Prior to the procedure, they were administered 1 g of cephalexin, combined with 4 mg of dexamethasone and 1 g of dipyrrone as antibiotic prophylaxis. For the postoperative period, they were prescribed 500 mg of cephalexin every 6 hours for 7 days, 4 mg of dexamethasone every 12 hours for 3 days, 1 g of dipyrrone every 6 hours for 3 days, and an antibiotic ointment containing Collagenase and chloramphenicol to be applied to the sutured area for 7 days. Patients were

instructed to apply cold compresses to the operated area for 2 days, avoid sun exposure, restrict lip movement for 15 days, and refrain from physical activity for 7 days. Nylon sutures were removed 7 days after the procedure, and Cica-plast® Baume ointment was prescribed for use in the wound area for an additional 3 months.

CASE SERIES

Case report 1

Female patient, Caucasian, 51 years old, systemically healthy, presented with an aesthetic concern of an aged smile with limited dental exposure and a desire to increase lip volume and eversion. Clinically, it was observed that the upper lip had an elongated length of 25 mm, with 8mm of upper vermilion height and 17 mm of philtrum height. Dental exposure of the upper incisors at rest was negative (Figure 1A), and while smiling, it measured 3 mm (Figure 1B).

The treatment plan consisted of performing a lip lift surgery with the excision of 6 mm of tissue (Figure 1C and 1D). After 7 days, the sutures were still in place, showing no signs of infection, with a favorable scar appearance (Figure 2A and 2B). At the 20-day postoperative mark, the patient exhibited exposure of three knots of 5.0 polyglactin thread, which had been used for subcutaneous tissue closure, and its removal was necessary (Figure 2C). After 30 days, the patient maintained a good scar appearance, without signs of infection, and no additional interventions were required. After 12 months, the patient remains satisfied with a favorable aesthetic outcome, showing dental exposure of 2.5 mm at rest and 6 mm while smiling, with a balanced proportion between the upper and lower lips, and the upper vermilion measuring 9 mm in height (Figure 3).

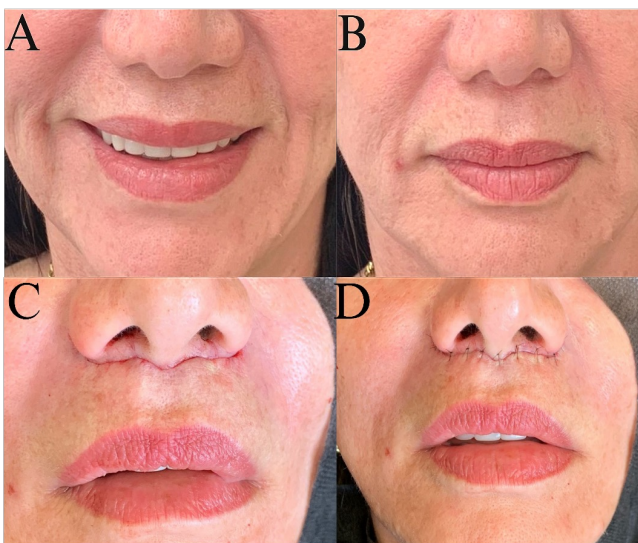

Figure 1. A: frontal photograph of the patient smiling. B: and with relaxed lips. C: intraoperative photography after subcutaneous tissue closure. D: final appearance of the sutures, showing tooth exposure with relaxed lips.

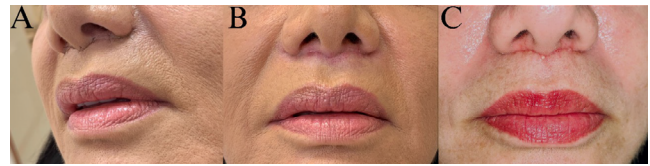

Figure 2. Post-operative photographs. A: 7 days in left 3/4 view. B: 7 days in frontal view, after cleaning the region. C: 20 days, with inflammatory reaction due to exposure of the suture thread.

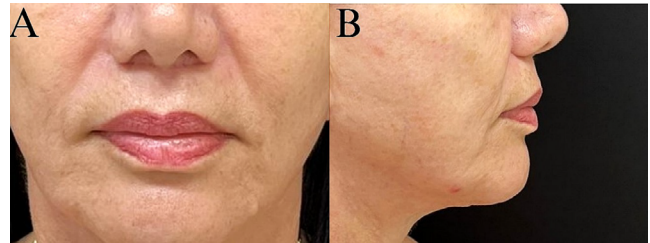

Figure 3. 12-month post-operative photographs. A: frontal view. B: side view.

Case report 2

A caucasian female patient, 65 years old, with a history of hypertension, sought medical attention with complaints of facial aging, absence of dental exposure while smiling, and thin lips. Initially, she expressed interest in undergoing lip augmentation with hyaluronic acid. Upon physical examination, it was observed that the upper lip had an elongated length, measuring 23 mm in height, with 4 mm of upper vermilion height and 19 mm of philtrum height. The patient had asymmetric lip micropigmentation, which was in the process of fading. Dental exposure of the upper incisors at rest was negative at -2 mm (Figure 4A), and while smiling, it was 0 mm, meaning that her teeth were not visible when she smiled (Figure 4B). It was diagnosed that the patient had an unsatisfactory upper dental prosthesis of the implant-supported bridge type, which had been in place for 12 years. This prosthesis was made of porcelain and had an edge-to-edge bite with the lower teeth, and an inverted smile curve, which was possibly one of the reasons for the lack of dental exposure.

The proposed treatment plan included replacing the upper dental prosthesis to achieve aesthetic and functional improvement, along with a lip lift surgery to reduce the length of the upper lip. Due to the degree of the patient's aging, which included mild inversion of the oral commissures, it was planned to excise 5 mm of tissue from the philtrum to prevent a potential "sad" facial appearance (Figure 4C). Initially, the patient chose to undergo only the facial surgery, despite being aware of the limitations of the results (Figure 4D). After 7 days, she had intact sutures, reduced edema, and limited lip movement but already with a visible improvement in the appearance of the nasolabial angle (Figure 5). After 21 months, the patient has a favorable scar appearance, with no visible scarring, no signs of infection, dental

exposure of 1 mm at rest and 3 mm while smiling, and a vermillion height of 7 mm (Figure 6).

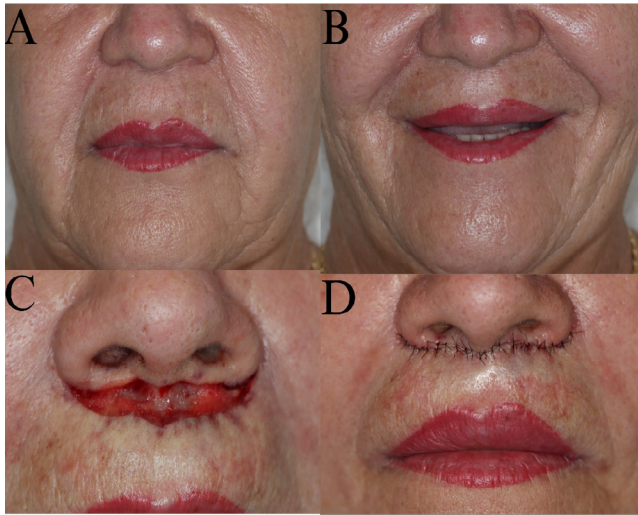

Figure 4. A: frontal photograph of the patient with relaxed lips. B: and smiling. C: intraoperative photography after tissue resection. D: final appearance of the procedure.

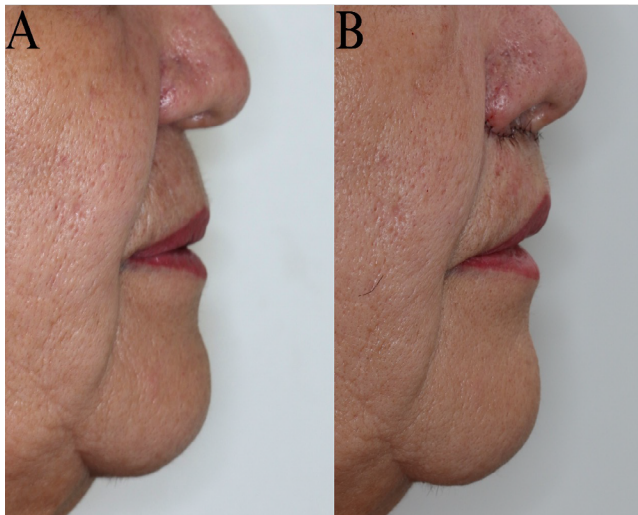


Figure 5. Photographs in lateral view. A: pre-operative. B: 7 days post-operative.

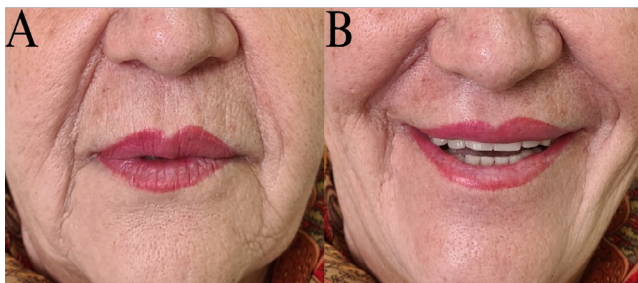

Figure 6. Photographs 21 months after surgery. A: relaxed lips. B: in smile.

Case report 3

A caucasian female patient, 68 years old, with a history of hypertension, had aesthetic concerns about an aged appearance, limited dental exposure, and a desire to increase lip volume. She had a history of multiple hyaluronic acid injections in her lips to improve the aesthetics of the region but did not achieve the desired results. Clinically, she exhibited significant skin laxity, and the upper lip had an elongated length, measuring 26 mm in height, with 2 mm of upper vermillion height and 24 mm of central philtrum height. There was also lip asymmetry, with the left philtrum being 2 mm longer than the right. The exposure of the upper incisors at rest was negative (Figure 7A), and while smiling, it was 3 mm (Figure 7B). Laboratory tests were conducted, and the results were within normal limits.

The treatment plan involved performing a lip lift surgery with the excision of 8 mm of tissue from the central philtrum and an asymmetric design to remove an additional 2 mm from the left lateral portion, along with other cosmetic treatments for skin improvement (Figure 7C and 7D). After 7 days, the sutures remained intact, with no signs of infection, a favorable scar appearance, localized edema, and bruising throughout the upper lip. Regular follow-up was maintained, and after 12 months from the procedure, the patient achieved a satisfactory aesthetic outcome. There was a visible scar at the base of the nose, but no signs of hypertrophic scars or keloids. The patient had no aesthetic complaints, good lip proportion, dental exposure of 2,5 mm at rest and 8 mm while smiling, and an upper vermillion length of 6 mm (Figure 8).

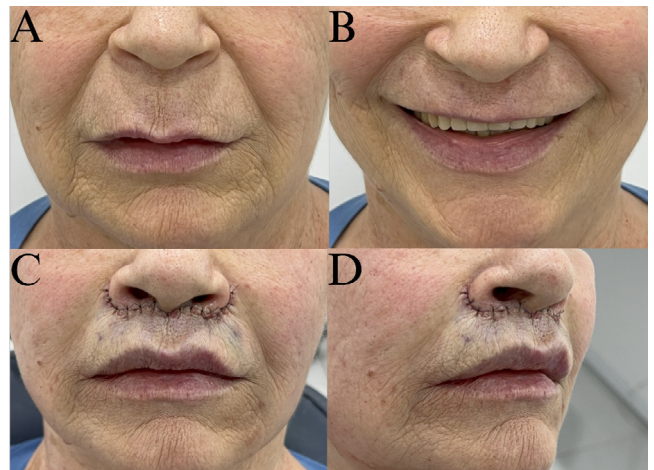

Figure 7. Frontal photographs of the patient. A: with relaxed lips. B: smiling. C: initial post-operative view in frontal view. D: in right view 3-4.

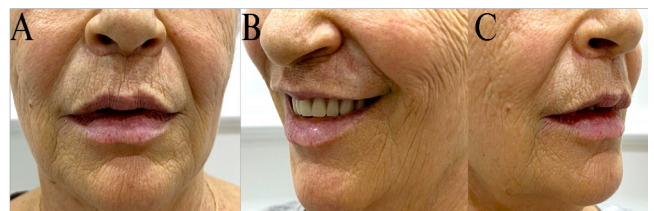


Figure 8. Photographs 12 months after surgery. A: frontal view. B: left 3/4 view in smile. C: right 3/4 view with relaxed lips.

Case report 4

A male patient, of mixed race, 28 years old, systemically healthy, had a complaint of not exposing his anterior teeth when smiling, even after undergoing orthognathic surgery. The patient sought postoperative care nine months after bi-maxillary orthognathic surgery, which involved maxillary advancement and extrusion. However, achieving adequate incisor exposure was still not possible. It was proposed to the patient to undergo a new LeFort I procedure to further reposition the maxilla with the aim of increasing vertical height, but the patient chose not to pursue this treatment. It was also proposed to perform a lip lift surgery to improve local exposure, and due to its minimally invasive nature, the patient opted for this treatment.

Upon clinical examination, it was observed that the upper lip had a length of 23 mm in height, with 7 mm of upper vermillion height and 16 mm of philtrum height. The dental exposure of the upper incisors at rest was 0 mm (Figure 9A), and while smiling, it was 4 mm.

The treatment plan involved performing a lip lift surgery with the excision of 4 mm of tissue, as a larger amount was not possible due to the limited amount of existing philtrum tissue (Figure 9B). At the 36-month postoperative mark, the patient remains in good overall condition, with a discreet scar. He maintains dental exposure of 2 mm at rest and 6mm while smiling (Figure 9C).

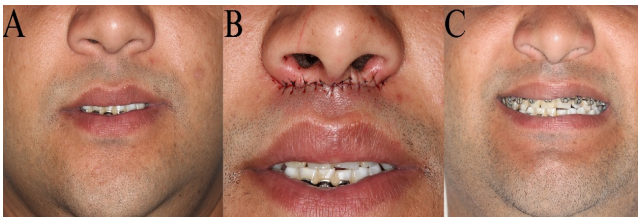

Figure 9. Frontal photographs in A: pre-operative with relaxed lips. B: immediate post-operative period, showing tooth exposure. C: 36 months post-operative, in smile.

DISCUSSION

The literature indicates that in a young face, the average length of the upper lip ranges from 18 to 22 mm, and the height of the vermillion should be between 6 to 9 mm^{10,11}. The philtrum should exhibit symmetrical and prominent columns, with its relationship to vermillion height being less than 3 mm⁵. In an aged lip with upper lip ptosis, these proportions tend to be lost^{1,6}. In the four cases presented, the patients had upper lip lengths equal to or greater than 23 mm, but one of the patients was young despite having an aged appearance. Regarding the height of the vermillion, three patients had values below the ideal range. Although patients 1 and 4 had an appropriate height, they still had indications for the procedure due to other reasons. Thus, we observe that age and vermillion height are not sole determining factors but complementary to other clinical considerations.

Aesthetically, the exposure of upper incisors at rest ranges from 1 to 5 mm. Ideally, this value should be 3 to 4 mm in women, and 1 to 3 mm in men, and during a smile, the entire length of the incisors should be visible^{5,12,14}. In the reported cases, the main complaint of the patients was the absence of dental visibility. All four individuals had negative dental exposure, giving them an “aged” appearance. However, it’s worth noting that patients with dentofacial deformities can also exhibit these characteristics due to maxillary deficiencies⁵, not necessarily elongated lips. In case 4, the patient had both diagnoses and even though he had undergone previous orthognathic surgery, he did not achieve the desired aesthetic outcome. A lip lift surgery was proposed to adjust the lip length, aiming to improve dental exposure within his limitations. With the technique used, an average proportion was observed: for every 1 mm of tissue resection, there was an increase of 0,5 mm in dental exposure.

Authors indicate that the amount of tissue to be excised depends on the degree of philtrum elongation, the desired amount of eversion and lip shortening, and possible asymmetries of the upper lip. This measure is determined through prior facial analysis, considering philtrum height, vermillion height, and exposure, the proportion between the upper and lower lips, lip projection, and incisor exposure^{13,14}. Furthermore, variables such as skin thickness, skin laxity, bone remodeling, and muscle function can influence the outcome and should be considered. Excisions generally range from 4 to 11 mm, with an average of 5 to 7 mm^{6,12,14}, and resection beyond 11 mm is not recommended as it increases wound tension and healing time⁵. In older patients, such as cases 2 and 3, the presence of tissue laxity, both in the lips and the face, can limit the amount of tissue resection. Large incisions can lead to an unsatisfactory aesthetic result, with a “sad” appearance or a “rabbit” or “cleft lip” appearance due to lateral inversion of the mouth corner^{5,11,12,14-16}. Additionally, scarring tends to be less aesthetically pleasing, with a higher risk of visible clinical appearance. Among the cases reported, despite the pleasant aesthetic outcome, the scar in the older patient (case 3) was the most visible. Therefore, the decision to undergo a lip lift and the amount of tissue resection in such cases should be more careful and conservative. Thus, we observe that the treatment plan should be based on multifactorial analyses rather than fixed reference values.

Regarding complications, due to the rich vascularity of the lip region, hematoma and edema are possible complications of a lip lift. A gummy smile, a sad appearance, and lip asymmetry can occur in cases of excessive tissue resection. Additionally, infection, hypertrophic scarring, and keloid formation have been reported¹². Among the reported cases, only one case (case 1) experienced complications with the suture due to delayed exposure (after 15 days) of the polyglactin thread placed in the subcutaneous tissue, necessitating its removal. Case 3, likely due to her age and systemic changes, presented with persistent edema and hematomas, which resolved spontaneously. Two patients maintained dental exposure below the ideal range due to treatment limitations. Case 4 had a previously under-corrected dentofacial deformity, and case 2 had an unsatisfactory complete denture. This shows that dentures with inadequate proportions, leading to a decrease in the patient’s vertical dimension, are

direct causes of unsatisfactory aesthetic outcomes in dental exposure and consequently, an aged appearance, requiring correction to improve the patient's appearance.

This article, as it is a case series report, has limitations regarding the sample size of individuals. For this reason, it is not possible to generalize the results obtained with specific conclusions for the cases studied. More studies are needed to advance the literature on this subject.

CONCLUSION

The modified bullhorn lip lift surgery has proven to be both safe and aesthetically favorable in the four patients treated, making it a viable option in cases where less invasive techniques do not provide satisfactory results. Despite being technically straightforward, its treatment plan is more complex, necessitating a thorough clinical evaluation to determine the amount of skin to be excised. Various factors, such as age, the presence of dentofacial deformities, and unsatisfactory prostheses, can be limiting factors for the success of the treatment. Other studies are needed, with a larger sample of individuals, to corroborate these findings.

CONFLICT OF INTEREST

The authors declare that they have no conflicts of interest to disclosure.

PUBLICATION ETHICS

This article does not contain any studies with human participants or animals performed by any of the authors.

Informed consent was obtained from patients.

REFERENCES

- Guerrissi JO. Surgical treatment of the senile upper lip. *Plast Reconstr Surg.* 2000;106(4):938-40. DOI: 10.1097/00006534-200009040-00036.
- Santanchè P, Bonarrigo C. Lifting of the upper lip: personal technique. *Plast Reconstr Surg.* 2004;113(6):1828-35. DOI: 10.1097/01.prs.0000117661.07141.70.
- Hudson DA. An analysis of unsolved problems of face-lift procedures. *Ann Plast Surg.* 2010;65(2):266-9. DOI: 10.1097/SAP.0b013e3181c2a7bb.
- Linkov G, Wick E, Kallogjeri D, Chen CL, Branham GH. Perception of upper lip augmentation utilizing simulated photography. *Arch Plast Surg.* 2019;46(3):248-54. DOI: 10.5999/aps.2018.01319.
- Talei B. The Modified Upper Lip Lift: Advanced Approach with Deep-Plane Release and Secure Suspension: 823-Patient Series. *Facial Plast Surg Clin North Am.* 2019;27(3):385-98. DOI: 10.1016/j.fsc.2019.04.004.
- Waldman SR. The subnasal lift. *Facial Plast Surg Clin North Am.* 2007;15(4):513-6, viii. DOI: 10.1016/j.fsc.2007.08.003.
- Cardim VLN, Silva AS, Salomons RL, Dornelles RFV, Blom JOS, Silva AL. "Double duck" nasolabial lifting. *Rev Bras Cir Plást.* 2011;26(3):466. DOI: 10.1590/S1983-51752011000300017.
- Moragas JS, Vercruyse HJ, Mommaerts MY. "Non-filling" procedures for lip augmentation: a systematic review of contemporary techniques and their outcomes. *J Craniomaxillofac Surg.* 2014;42(6):943-52. DOI: 10.1016/j.jcms.2014.01.015.
- Paixão M, Montedonio J, Filho WQ, Pouza CET, Almeida AEF. Upper lip lifting associated with mechanical dermabrasion. *Surg. Cosmet. Dermatol.* 2011;3(3):249-53.
- Jeter TS, Nishioka GJ. The lip lift: an alternative corrective procedure for latrogenic vertical maxillary deficiency: report of a case. *J Oral Maxillofac Surg.* 1988;46(4):323-5. DOI: 10.1016/0278-2391(88)90019-5.
- Lee DE, Hur SW, Lee JH, Kim YH, Seul JH. Central Lip Lift as Aesthetic and Physiognomic Plastic Surgery: The Effect on Lower Facial Profile. *Aesthet Surg J.* 2015;35(6):698-707. DOI: 10.1093/asj/sjv068.
- Li YK, Ritz M. The modified bull's horn upper lip lift. *J Plast Reconstr Aesthet Surg.* 2018;71(8):1216-30. DOI: 10.1016/j.bjps.2018.04.003.
- Raphael P, Harris R, Harris SW. Analysis and classification of the upper lip aesthetic unit. *Plast Reconstr Surg.* 2013;132(3):543-51. DOI: 10.1097/PRS.0b013e31829accb6.
- Raphael P, Harris R, Harris SW. The endonasal lip lift: personal technique. *Aesthet Surg J.* 2014;34(3):457-68. DOI: 10.1177/1090820X14524769.
- Spiegel JH. The modified bullhorn approach for the lip-lift. *JAMA Facial Plast Surg.* 2019;21(1):69-70. DOI: 10.1001/jamafacial.2018.08
- Tonnard PL, Verpaele AM, Ramaut LE, Blondeel PN. Aging of the upper lip: Part II. Evidence-based rejuvenation of the upper lip- A review of 500 consecutive cases. *Plast Reconstr Surg.* 2019;143(5):1333-42. DOI: 10.1097/PRS.0000000000005589.