




Revista Española de
Cirugía Oral y
Maxilofacial

www.revistacirugiaoralmaxilofacial.es



Original

Comparison of the outcomes of unilateral orbital fracture repair with and without surgical navigation system: our experience in La Paz University Hospital

Celia Sánchez Gallego-Albertos, Jorge Guiñales Díaz de Cevallos, José Luis del Castillo Pardo de Vera, José Luis Cebrián Carretero y Miguel Burgueño García

Department of Maxillofacial Surgery, La Paz University Hospital. Madrid, Spain

ARTICLE INFORMATION

Article history:

Received: 30 de marzo de 2020

Accepted: 23 de septiembre de 2020

Keywords:

Orbital fracture, facial fracture, intraoperative navigation, planification, plate positioning, orbital volume.

ABSTRACT

Introduction: Restoration of normal orbital volume and globe position following traumatic injury is often difficult. Intraoperative navigation has emerged as a tool to allow the visualization of the implant position intraoperatively, by means of the planification in the preoperative computed-tomographic scan (CT scan).

Objectives: The aim of this study was to compare the postoperative changes in orbital volume between two groups of study: one group that underwent surgical intervention before the implementation of intraoperative navigation (control group), and other group of patients which had undergone surgery with the aid of a navigation system (Software iPlan CMF version 3.0.5, Brainlab®, Feldkirchen, Germany) (navigation group). Another endpoint of our study was to determine if the presurgical planification and intraoperative navigation aided to position the implant. For that purpose, we determined the implant position with respect to the orbital floor and medial orbital wall and compared it between both groups of study. As secondary endpoints, we compared the rate of postoperative outcomes and reintervention rate between both groups.

Materials and methods: A retrospective cohort study was designed. We selected a total of 35 consecutive orbital operations for unilateral orbital fractures performed between 2015 and 2018 at the Department of Oral and Maxillofacial Surgery in La Paz Hospital (Madrid), Spain. We collected information regarding: demographic data, cause of the fracture, time elapsed between diagnosis and surgical treatment, symptoms at diagnosis (diplopia, globe projection, ocular motility impairment), radiological findings (affected wall, muscular entrapment, herniation of the periorbital structures), and outcomes after surgical treatment (diplopia, globe position, ocular motility impairment, reintervention). By means of the iPlan CMF software, the orbital volume was determined in the preoperative and postoperative CT scan. The plate position was determined by measuring the distance between the plate and the orbital rim,

*Correspondence:

e-mail: celiasga22@gmail.com (Celia Sánchez Gallego-Albertos).

DOI: [10.20986/recom.2020.1135/2020](https://doi.org/10.20986/recom.2020.1135/2020)

1130-0558/© 2020 SECOM. Publicado por Inspira Network. Este es un artículo Open Access bajo la licencia CC BY-NC-ND (<http://creativecommons.org/licenses/by-nc-nd/4.0/>).

the distance between the plate and the residual posterior intact bony ledge and the distance between the plate and the medial orbital wall. Measurements were performed automatically in the three planes of space, although we used the sagittal plane to measure the distance between the plate and the orbital rim and between the plate and the residual posterior intact bony ledge. To measure the distance between the plate and the medial orbital wall we used the axial plane.

Results: After surgery, we observed that abnormal globe position was significantly less frequent in the navigation group than in the control group ($p = 0.029$). The reoperation rate was 11 % in the navigation group and 35% in the control group ($p = 0.071$). Mean orbital volume of the unaffected orbit was $29.32 \pm 2.64 \text{ cm}^3$ in the navigation group and $28.64 \pm 2.68 \text{ cm}^3$ in the control group. Mean orbital volume of the affected orbit was $34.19 \pm 3.67 \text{ cm}^3$ in the navigation group and $32.78 \pm 3.09 \text{ cm}^3$ in the control group. Mean reconstructed orbital volume was $29.47 \pm 2.75 \text{ cm}^3$ in the navigation group and $28.88 \pm 3.72 \text{ cm}^3$ in the control group. Mean volume reduction and the mean difference in volume between unaffected and reconstructed side did not show significant differences between both groups. The mean distance from plate to orbital floor at the residual posterior intact bony ledge showed significant differences ($p = 0.001$), being inferior in the navigation group.

Conclusions: The use of intraoperative navigation in orbital fractures is effective in improving plate positioning in the residual posterior intact bony ledge of the floor of the orbit, reducing complications such as enophthalmos compared to conventional surgery. Furthermore, the use of intraoperative navigation seems to decrease the rate of reintervention compared to conventional surgery. The restoration of orbital volume seems to be well addressed by both methods.

Comparación de los resultados en cirugía de fractura de órbita unilateral con y sin sistema de navegación quirúrgica: experiencia en el Hospital Universitario La Paz

R E S U M E N

Palabras clave:

Fractura de órbita, fractura facial, navegación intraoperatoria, planificación prequirúrgica, volumen orbitario, posicionamiento de la placa.

Introducción: La restauración del volumen orbitario normal y la posición del globo ocular después de una fractura orbitaria puede ser difícil. La navegación intraoperatoria ha surgido como una herramienta que permite visualizar la posición del implante intraoperatoriamente mediante la planificación en la tomografía computarizada (TC) preoperatoria.

Objetivos: El objetivo de este estudio fue comparar los cambios posoperatorios en el volumen orbitario entre dos grupos de estudio: un grupo que se sometió a intervención quirúrgica antes de la implementación de la navegación intraoperatoria (grupo de control), y otro grupo de pacientes que habían sido intervenidos con la ayuda de un sistema de navegación (Software iPlan CMF versión 3.0.5, Brainlab®, Feldkirchen, Alemania) (grupo de navegación). Otro criterio de valoración de nuestro estudio fue determinar si la planificación prequirúrgica y la navegación intraoperatoria facilitó a la hora de colocar la malla orbitaria. Para ello, determinamos la posición de la malla con respecto al suelo orbitario y la pared orbitaria medial y la comparamos entre ambos grupos de estudio. Como criterios de valoración secundarios, comparamos los síntomas oculares posoperatorios y la tasa de reintervención entre ambos grupos.

Materiales y métodos: Se diseñó un estudio de cohortes retrospectivo. Seleccionamos un total de 35 pacientes intervenidos por fracturas orbitarias unilaterales entre 2015 y 2018 en el Servicio de Cirugía Oral y Maxilofacial del Hospital Universitario La Paz (Madrid), España. Se recogió información sobre: datos demográficos, causa de la fractura, tiempo transcurrido entre el diagnóstico y la cirugía, síntomas al diagnóstico (diplopía, proyección del globo ocular, alteración de la motilidad ocular), hallazgos radiológicos (pared afectada, atrapamiento muscular, herniación grasa), y síntomas posquirúrgicos (diplopía, posición del globo ocular, alteración de la motilidad ocular), así como necesidad de reintervención. Mediante el software iPlan CMF se determinó el volumen orbitario en el TC preoperatorio y posoperatorio. La posición de la malla se determinó midiendo la distancia entre la malla y el borde orbitario, la distancia entre la malla y el reborde óseo intacto posterior residual y la distancia entre la

mallá y la pared orbitaria medial. Las mediciones se realizaron de forma automática en los tres planos del espacio, aunque utilizamos el plano sagital para medir la distancia entre la mallá y el borde orbitario y entre la mallá y el reborde óseo posterior. Para medir la distancia entre la mallá y la pared orbitaria medial utilizamos el plano axial.

Resultados: Después de la cirugía, observamos que la posición anormal del globo ocular fue significativamente menos frecuente en el grupo de navegación que en el grupo control ($p = 0,029$). La tasa de reintervención fue del 11 % en el grupo de navegación y del 35 % en el grupo de control. El volumen orbitario medio de la órbita sana fue $29,32 \pm 2,64 \text{ cm}^3$ en el grupo de navegación y $28,64 \pm 2,68 \text{ cm}^3$ en el grupo control. El volumen orbitario medio de la órbita afectada fue $34,19 \pm 3,67 \text{ cm}^3$ en el grupo de navegación y $32,78 \pm 3,09 \text{ cm}^3$ en el grupo control. El volumen orbitario reconstruido medio fue de $29,47 \pm 2,75 \text{ cm}^3$ en el grupo de navegación y $28,88 \pm 3,72 \text{ cm}^3$ en el grupo control. La reducción media del volumen y la diferencia media de volumen entre el lado sano y el reconstruido no mostraron diferencias significativas entre ambos grupos. La distancia media de la placa al suelo orbitario en el reborde óseo posterior residual mostró diferencias significativas ($p = 0,001$), siendo inferior en el grupo de navegación.

Conclusiones: El uso de la navegación intraoperatoria en fracturas orbitarias es eficaz para mejorar el posicionamiento de la placa en el reborde óseo residual posterior del suelo orbitario, reduciendo complicaciones como el enoftalmos, en comparación con la cirugía convencional. Además, el uso de la navegación intraoperatoria parece disminuir la tasa de reintervención en comparación con la cirugía convencional. La restauración del volumen orbitario parece ser adecuada a través de ambos métodos.

INTRODUCTION

Orbital fractures are frequently associated with complications, such as persistent diplopia, enophthalmos and decreased globe motility¹. There is evidence that exact bony reconstruction and repositioning of orbital soft tissues will correct, or at least considerably improve clinical symptoms². Nevertheless, restoration of normal orbital volume and globe position following traumatic injury is often difficult. In orbital fracture surgery the visibility is often reduced, and the surgical field is small. Due to this, verifying proper implant position during the operation is often hard. Intraoperative navigation has emerged as a tool to allow the visualization of the implant position intraoperatively, by means of the planification in the preoperative CT scan¹⁻⁴. Navigation-assisted orbital reconstruction was introduced by Gellrich et al. in 2002⁵, and in recent years, many studies have demonstrated the feasibility of this technique^{6,7}.

The aim of this study was to compare the postoperative changes in orbital volume between two groups of study: one group that underwent surgical intervention before the implementation of intraoperative navigation (control group), and other group of patients which had undergone surgery with the aid of a navigation system (navigation group). Another endpoint of our study was to determine if the presurgical planification and intraoperative navigation aided to position the implant. For that purpose, we determined the implant position with respect to the orbital floor and medial orbital wall and compared it between both groups of study. As secondary endpoints, we compared the rate of postoperative outcomes and reintervention rate between both groups.

MATERIALS AND METHODS

A retrospective cohort study was designed. We selected a total of 35 consecutive orbital operations for unilateral orbital

fractures performed between 2015 and 2018 at the Department of Oral and Maxillofacial Surgery in La Paz Hospital (Madrid), Spain. The inclusion criteria were: 1) adult patients with unilateral orbital fracture involving the orbital floor and/or the medial wall with defect size larger than 2 cm^2 , extending into the posterior third of the orbit; 2) associated diplopia, or ocular motility impairment, or abnormal globe position (enophthalmos clinically evident [$>2 \text{ mm}$] by estimating the projection of the eyes by viewing from above and below)⁸; 3) preoperative and postoperative CT scan with 0.625- to 1.0- mm slice thickness; 4) preoperative and postoperative surgical records; 5) minimum of 6 months follow-up. Patients who did not fulfilled these criteria were excluded.

We collected information regarding: demographic data, cause of the fracture, time elapsed between diagnosis and surgical treatment, symptoms at diagnosis (diplopia, globe position, ocular motility impairment), radiological findings (affected wall, muscular entrapment, herniation of the periorbital structures), and outcomes after surgical treatment (diplopia, globe position, ocular motility impairment, reintervention).

We divided the sample into two groups:

1. The navigation group (with the aid of presurgical planification and intraoperative navigation) consisted of a consecutive cohort of 18 patients that fulfilled the inclusion criteria. These patients underwent surgery between 2016-2018, after the implementation of the navigation system. In this group of patients, the postoperative CT scans were done 24 h after the surgery.
2. The control group (without the aid of presurgical planification and intraoperative navigation) consisted of a consecutive cohort of 17 that fulfilled the inclusion criteria. These patients underwent surgery prior to the implementation of the navigation system in our department (2015-2016). In this group of patients, the postoperative CT scans were done one week after the surgery.

Surgical technique

All patients were operated on under general anaesthesia. Preoperative antibiotic prophylaxis (2 g amoxicillin with clavulanic acid) was given perioperatively (2 g) and postoperatively (1 g/8 h) for 7 days. A transconjunctival incision was used in all cases. The bony perimeter of the fracture was isolated.

In the control group, a pre-bent titanium orbital mesh was used (Synthes). The mesh was placed freehand under direct vision and fixed with two monocortical screws to the inferior orbital rim. Forced duction testing was performed to confirm normal ocular mobility in all patients. The conjunctiva was closed with resorbable 5/0 uninterrupted suture.

In the navigation group, a navigation system Software iPlan CMF (version 3.0.5, Brainlab®, Feldkirchen, Germany) was used for presurgical planning and intraoperative control of orbital contours and mesh positioning. The preoperative CT scan was loaded into the navigation computer. Mirroring of the unaffected orbit into the fractured side was created. This template was used for navigation during surgery, and navigation was used to verify both the posterior ledges of the fracture and the position and shape of the implant. A pre-bent titanium orbital mesh was used (Synthes). Additionally, to make sure a correct plate positioning during surgery, we carried out the printing of a stereolithographic model through our 3D printer (UP studio) (Figure 1) and we adapted the pre-bent titanium orbital mesh presurgically. The stereolithographic model impression was carried out only in the navigation group (Figure 2).

Measurement of the orbital volume

By means of the iPlan CMF software, the orbital volume of the affected, unaffected and reconstructed side was determined with the *smart brush* tool, by means of which the limits of the orbit were determined manually (including the herniated soft tissue in the affected side) and were corrected by coronal and axial position (Figures 3 and 4). Volume measurements were reported in cubic centimetres.




Figure 1. Preparation of our stereolithographic model through our 3D printer (UP studio).

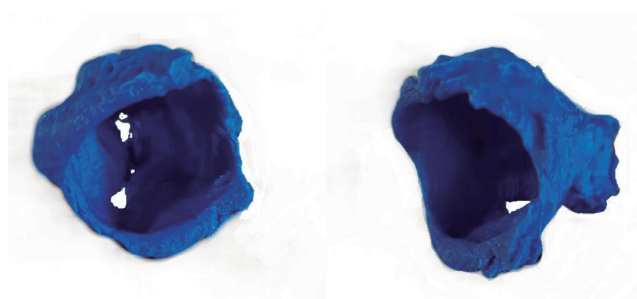


Figure 2. Stereolithographic model.

Measurement of implant positioning

By using the *image fusion* tool of the iPlan CMF software, the preoperative and postoperative CT scans were overlapped automatically. The plate position was determined by measuring three points:

1. Distance between the plate and the orbital rim (Figure 5);
2. Distance between the plate and the residual posterior intact bony ledge (Figure 6);
3. Distance between the plate and the medial orbital wall. This distance was only determined in those cases involving the medial orbital wall.

By using the iPlan CMF software, measurements are performed automatically in the three planes of space, although we used the sagittal plane to measure the distance between the plate and the orbital rim and between the plate and the residual posterior intact bony ledge. To measure the distance between the plate and the medial orbital wall we used the axial plane. Distance was measured in millimeters.

Statistical analysis

To see if both groups were similar, a χ^2 test for qualitative variables was used. A T-test for independent factors was performed to compare means across the 2 groups.

RESULTS

35 orbital operations performed in the department of Oral and Maxillofacial surgery in La Paz Hospital between 2015 and 2018 were selected. Clinical and demographic characteristics of the sample are summarized in Table I. 18 cases were performed between January 2016 and December 2018, using the navigation system (navigation group) and 17 cases were performed before January 2016 without it (control group). The time elapsed between the diagnosis and the surgery was 14 days in the control group and 15 days in the navigation group. The average age was 45 years old in the control group and 40 years old in the navigation group. Patient demographics, cause of injury, fracture characteristics, reintervention and CT scan characteristics are summarized in Table I.

In the control group, of the 12 patients with diplopia at diagnosis, 7 patients recovered and 5 persisted with diplopia in the postoperative period. 2 patients in the control group devel-

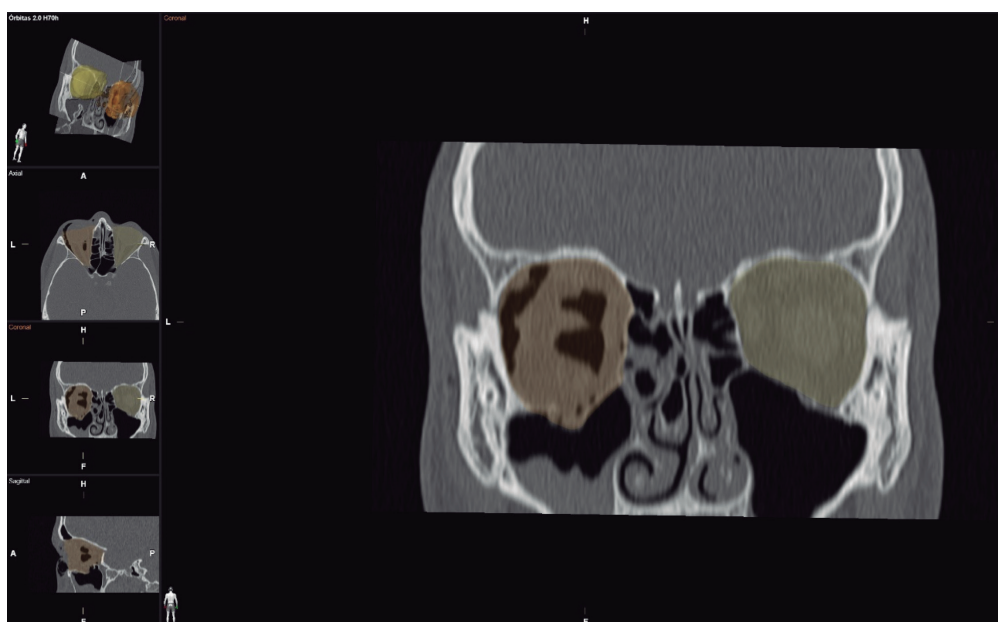


Figure 3. Measurement of the orbital volume of the affected side with the smart brush tool, including the herniated soft tissue in the affected side.

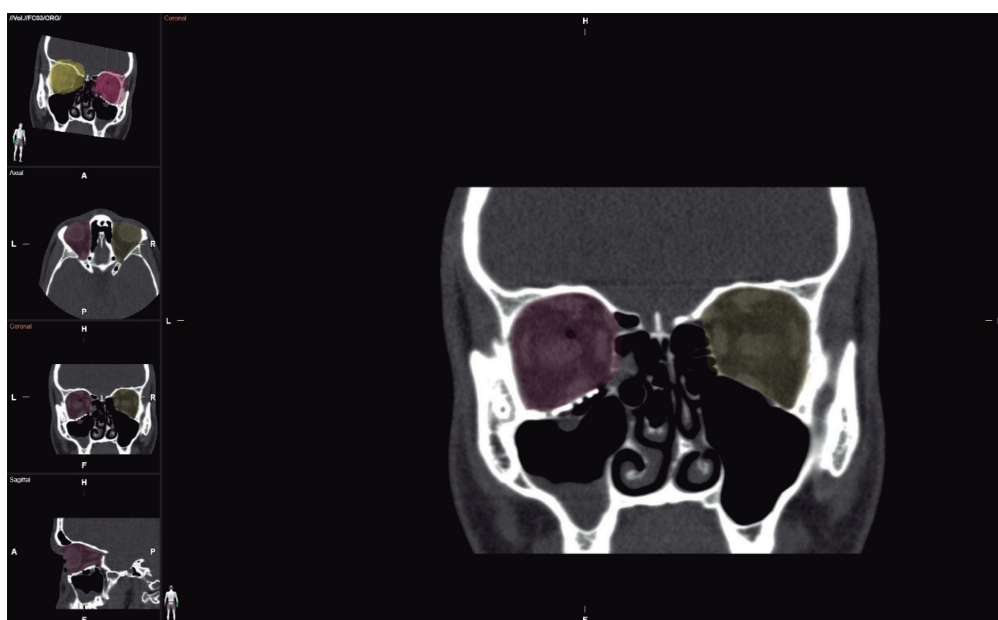

Figure 4. Measurement of the orbital volume of the reconstructed side with the *smart brush* tool.

oped diplopia in the postoperative period. In the navigation group, of the 8 patients with diplopia at diagnosis, 5 patients recovered and 3 persisted with diplopia in the postoperative period. 1 patient in the navigation group developed diplopia in the postoperative period. In the control group, of the 4 patients with abnormal globe position at diagnosis, 1 patient recovered and 3 persisted with abnormal globe position in the postoperative period. 1 patient in the control group developed abnormal globe position in the postoperative period. In the navigation group, all the 7 patients with abnormal globe position recov-

ered. In the control group, of the 8 patients with ocular motility impairment at diagnosis, 7 patients recovered and 1 persisted with ocular motility impairment in the postoperative period. 1 patient in the control group developed ocular motility impairment in the postoperative period. In the navigation group, of the 7 patients with ocular motility impairment at diagnosis, 6 patients recovered and 1 persisted with ocular motility impairment in the postoperative period (Table II). Both groups were homogeneous ($p > 0.05$) in terms of ocular motility impairment, diplopia, and globe position outcomes before surgery.

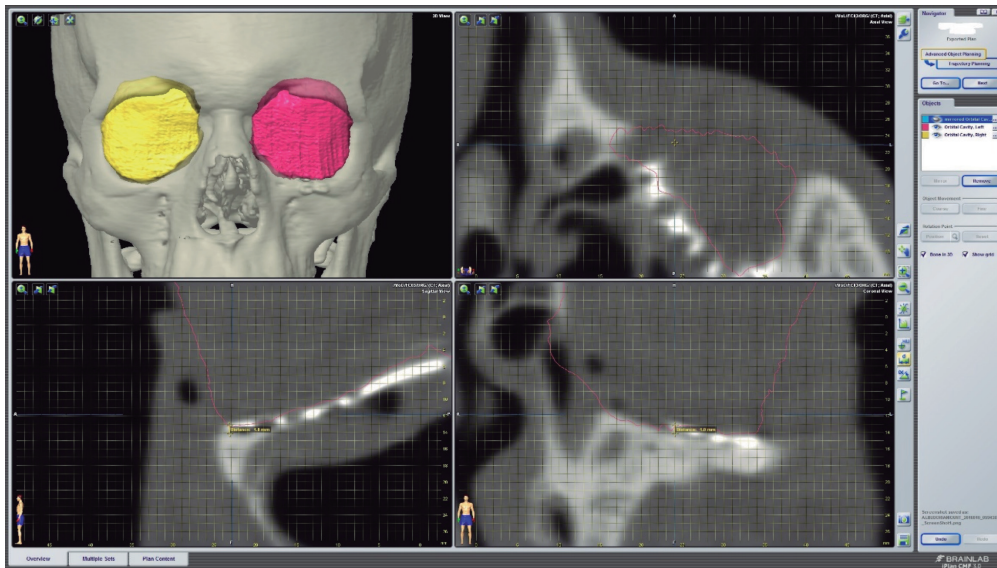


Figure 5. Distance between the plate and the orbital rim.
Only the sagittal plane was used for measurement.

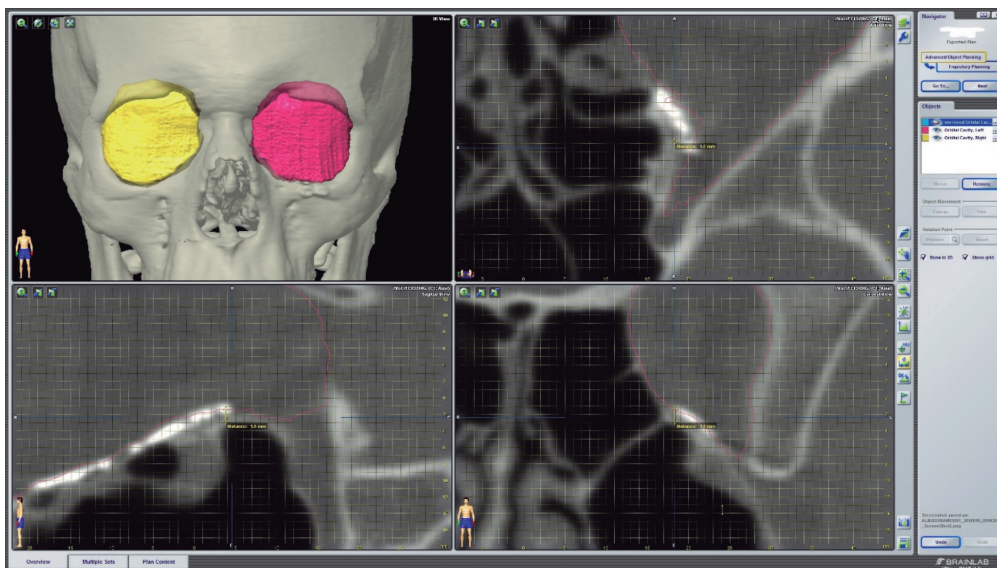


Figure 6. Distance between the plate and the residual posterior intact bony ledge.
Only the sagittal plane was used for measurement.

After surgery, we observed that abnormal globe position was significantly less frequent in the navigation group than in the control group ($p = 0.029$), as no patients persisted with abnormal globe position after surgery in the navigation group (Table III).

In the control group, 6 patients required reintervention, and in the navigation group only 2 patients required reintervention (Table III). The reoperation rate was 11% in the navigation group and 35% in the control group ($p = 0.071$). Of the 6 patients requiring a secondary operation in the control group, 4 were due to persistence of diplopia and abnormal globe projection and 2 were due to persistence of diplopia. Of the 2 patients requiring secondary operation in the navigation group, one

was due to persistence of diplopia and the other one required a blepharoplasty due to postoperative palpebral retraction.

When we analysed the measurements of the orbital volume of the whole sample, we saw that the mean orbital volume of the affected side was significantly bigger than the mean volume of the reconstructed side (mean volume reduction 4.32 cm^3 , $p < 0.00001$), and that the mean orbital volume of the reconstructed side did not differ significantly from the mean orbital volume of the unaffected side (difference in volume between unaffected side and reconstructed side -0.19 cm^3 , $p = 0.57$). Nevertheless, when we compared both groups separately, the mean volume reduction and the mean difference in volume between unaffected and reconstructed side did not show significant

differences. Mean orbital volume of the unaffected orbit was $29.32 \pm 2.64 \text{ cm}^3$ in the navigation group and $28.64 \pm 2.68 \text{ cm}^3$ in the control group. Mean orbital volume of the affected orbit was $34.19 \pm 3.67 \text{ cm}^3$ in the navigation group and $32.78 \pm 3.09 \text{ cm}^3$ in the control group. The mean reconstructed orbital volume was $29.47 \pm 2.75 \text{ cm}^3$ in the navigation group and $28.88 \pm 3.72 \text{ cm}^3$ in the control group (Table IV).

Table I. Summary of patient demographics, cause of injury, fracture characteristics, time until surgery, presence of radiological muscular incarceration and periorbital fat herniation.

N		CONT		NAVI	
		% of cont	N	% of navi	
Number of patients		17	100 %	18	100 %
Sex	Male	11	64.7 %	11	61.1 %
	Female	6	35.3 %	7	38.9 %
Mean age, yr		45		40	
Cause	Assault	9	52.9 %	8	44.4 %
	MVA	3	17.6 %	6	33.3 %
	Fall	5	29.4 %	4	22.2 %
	Isolated floor	15	88.2 %	11	61.1 %
Type of fracture	Floor+medial wall	2	11.8 %	4	22.2 %
	Isolated medial wall	0	0.0 %	3	16.7 %
Time until surgery, days		14		15	
Radiological muscular incarceration	No	13	76.5 %	18	100.0 %
	Yes	4	23.5 %	0	0.0 %

NAVI: navigation group. CONT: control group. MVA: Motor Vehicle Accident

Table II. Presence or absence of diplopia, motor ocular restriction and normal or abnormal globe position before and after surgery in the navigation and control groups

N		CONT		NAVI	
		% of cont	N	% of navi	
Preoperative diplopia	No	5	29.4 %	10	55.6 %
	Yes	12	70.6 %	8	44.4 %
Postoperative diplopia	No	10	58.8 %	14	77.8 %
	Yes	7	41.2 %	4	22.2 %
Preoperative globe projection	Normal	13	76.5 %	11	61.1 %
	Abnormal	4	23.5 %	7	38.9 %
Postoperative globe projection	Normal	13	76.5 %	18	100.0 %
	Abnormal	4	23.5 %	0	0.0 %
Preoperative ocular restriction	No	9	52.9 %	11	61.1 %
	Yes	8	47.1 %	7	38.9 %
Postoperative ocular restriction	No	15	88.2 %	17	94.4 %
	Yes	2	11.8 %	1	5.6 %

NAVI: navigation group. CONT: control group.

Table III. Ocular motility impairment, globe projection, diplopia outcomes after surgery, and need for reintervention in control group and navigation group. In the navigation group we observed no patients with abnormal globe position after surgery ($p = 0.029$).

		CONT	NAVI	P- sig
Ocular motility impairment	No	15	17	0.512
	Yes	2	1	
Globe projection	Normal	13	18	0.029*
	Abnormal	4	0	
Diplopia	No	10	14	0.227
	Yes	7	4	
Reintervention	No	11	16	0.071
	Yes	6	2	

NAVI: navigation group. CONT: control group.

Table IV. The distance from plate to orbital floor at the distal part showed significant differences between control and navigation group.

	CONT		NAVI		P-sig	Difference between means	Difference between SD
	Mean	SD	Mean	SD			
Unaffected side (cm^3)	28.64	2.68	29.32	2.64	0.46	-0.67	0.90
Affected side (cm^3)	32.78	3.09	34.19	3.67	0.23	-1.40	1.14
Reconstructed side (cm^3)	28.88	3.72	29.47	2.75	0.59	-0.59	1.10
Volume reduction (cm^3)	3.90	2.22	4.71	2.77	0.34	-0.81	0.85
Difference in volume between unaffected side and reconstructed side (cm^3)	-0.23	2.58	-0.14	1.31	0.90	-0.08	0.68
Distance plate- orbital floor (distal) (mm)	3.65	1.67	1.69	1.32	0.001	1.96	0.50
Distance plate- orbital floor (orbital margin) (mm)	0.75	0.66	0.53	0.57	0.290	0.29	0.20
Distance plate- medial wall (mm)	2.00	0.14	1.72	1.62	0.828	0.27	1.20

NAVI: navigation group. CONT: control group.

The mean distance from plate to orbital floor at the distal part was $3.65 \pm 1.67 \text{ cm}^3$ in the control group and $1.69 \pm 1.32 \text{ cm}^3$ in the navigation group. The mean distance from plate to the orbital floor at the orbital margin was $0.755 \pm 0.66 \text{ cm}^3$ in the control group and $0.53 \pm 0.57 \text{ cm}^3$ in the navigation group. The distance from plate to the medial orbital wall was $2 \pm 0.14 \text{ cm}^3$ in the control group and $1.7 \pm 1.62 \text{ cm}^3$ in the navigation group. The distance from plate to orbital floor at the residual posterior intact bony ledge showed significative differences ($p = 0.001$) (Table IV).

DISCUSSION

This retrospective study demonstrated a better control of the positioning of the plate at the residual posterior intact bony ledge of the floor of the orbit in the navigation group compared with the control group. These differences were statistically significative ($p = 0.001$). The clinical evaluation showed that there was a statistically significant increase in globe projection between the preoperative and postoperative periods in the navigation group compared with the control group ($p = 0.039$). Furthermore, a greater volume reduction in the navigation group (4.71 cm^3) compared with the control group (3.90 cm^3) was achieved, although this difference was not statistically significative ($p = 0.34$). The need for secondary operation was lower in the navigation group compared with the control group, as only one patient required reexploration for implant repositioning in this group. The reoperation rate was 11% in the navigation group and 35% in the control group ($p = 0.71$). This was not statistically significant, partly because of the small sample size.

Novelli et al.⁹ reported a correspondence between the postoperative reconstruction mesh position and the presurgical virtual planning with a margin of error of less than 1.3 mm. In a cadaveric study of Jansen et al.¹⁰ implant position improved significantly for translation (2.6 mm), yaw and roll in the group with preoperative planning. Zimmerer et al.¹¹ showed that with intraoperative navigation, the precision of orbital volume reconstruction increased significantly. We achieved an improvement in plate positioning in the navigation group, and this improvement was more evident at the the residual posterior intact bony ledge of the floor of the orbit, where an average error of 1.69 mm was found in contrast to the 3.65 mm observed in the control group ($p = 0.001$). In our study, stereolitographic models and patient specific implants bended presurgically were used in the navigation group. An overlap in the use of individualized implants and navigation may make it difficult to attribute the improved precision to a single factor, although some studies found no significative differences between the use of patient-specific implants molded from the preinjury STL model, titanium mesh sheets bent freehand, and preformed titanium meshes¹².

Reconstruction of the orbital floor posterior to the eyeball equator is the most important aspect for correcting enophthalmos¹³⁻¹⁵. As mentioned above, we have demonstrated a better control of plate positioning in the posterior orbital floor with navigation-aided surgery, and this could explain our better results in terms of orbital globe projection in the navigation group compared to the control group ($p = 0.039$). We assessed

orbital globe projection clinically, by estimating the projection of the eyes by viewing from above and below, as performed in other studies⁸, and we considered an abnormal globe projection to the enophthalmos perceived clinically ($> 2 \text{ mm}$).

According to the literature, there are different methods for the measurement of orbital volumes^{16,17}. The major difficulty in comparing data is the definition of the anterior border of the bony orbit and the delimitation of the herniated periorbital tissue into the maxillary or ethmoidal sinuses¹⁸⁻²⁰. We observed that the brainlab software by itself could not only calculate properly the contour of the herniated soft tissue, but also it was hard to delineate the anterior bony orbit manually without having a reference. To avoid this potential bias, we performed the measurement of the contour of the bony orbit manually (by using the *smart brush* tool). Doing the measurements this way we could delineate the limits of the herniated soft tissue avoiding the error produced if we did it automatically. Some studies have reported that navigation aided surgery significantly improves the restoration of the orbital volume, and that specifically the use of a navigation system leads to a greater volume reduction than in the conventional surgery. In our study, we observed that both groups were similar in terms of mean orbital volume of the unaffected and affected sides, and that with both methods a similar volume of the reconstructed side was achieved (Table IV). By comparing the difference in volume between unaffected and reconstructed side we can observe that both groups achieved an adequate orbital volume in the reconstructed side (control group -0.23 cm^3 ; navigation group -0.14 cm^3) (Table IV). We observed a greater volume reduction in the navigation group (4.71 cm^3) compared with the control group (3.90 cm^3), but nevertheless these differences were not statistically significative ($p = 0.34$) (Table IV). Maybe, one of the reasons for obtaining this result was the different protocol for performing the postoperative CT scan in both groups, as in the control group the postoperative CT scan was made one month postoperatively, and in the navigation group it was made the day after the surgery.

There is a paucity of literature comparing the computer-aided techniques with conventional techniques with which to analyse outcomes. Zavattero et al.² reported a lower rate of severe postoperative diplopia in the navigation group. Their orbital volume analysis showed that reconstructed orbital volume in the navigation group was closer to unaffected orbital volume compared with the control group. Markiewicz et al.³ reported a retrospective cohort study of 23 subjects that assessed the reliability and effectiveness of intraoperative navigation in restoring normal orbital volume in traumatic and postablative defects. Their sample was composed by patients with complex orbital fractures affecting several walls and associated to other facial fractures, and by some patients with orbital tumours. The results of their study validate that intraoperative navigation is not only effective in restoring orbital and globe dimensions in post-traumatic defects, but also in post-ablative defects. Randall et al.⁶ also observed a reduced postoperative diplopia in the navigation group. and the effectiveness was maximal for fractures that involved 3 or 4 walls or the posterior one-third of the orbital floor. The need for revision surgery was also reduced in this cohort. Essig et al.⁷ found that the orbital volume of the affected side was significantly bigger in orbital fractures with involvement of

the posterior third of the orbital floor and in comminute fractures. They observed a significant reduction of orbital volume in the navigation group and non-significant reduction in conventional group.

Our study has some limitations, as we did not construct a multivariate model for analysis. Therefore, potential confounders that could modify treatment outcomes were not identified. Also, enophthalmos was addressed only clinically. Some differences existed between both groups, as all the surgeries were not performed by the same surgeon, and due to the different times when the surgery was performed: first, stereolithographic models and patient specific implants bended presurgically were used in the navigation group, and not in the control group; and second, the postoperative CT scan was not made at the same moment in both groups, which was probably the reason for not obtaining differences between the navigation group and the control group in terms of orbital volume reduction.

CONCLUSIONS

The results of this study suggest that using intraoperative navigation in orbital fractures is effective in improving plate positioning in the residual posterior intact bony ledge of the floor of the orbit, reducing complications such as enophthalmos compared to conventional surgery. Furthermore, the use of intraoperative navigation seems to decrease the rate of reintervention compared to conventional surgery. In our study, the restoration of orbital volume seems to be well addressed by both methods, as by comparing the difference in volume between unaffected and reconstructed side, both groups achieved an adequate orbital volume in the reconstructed side.

REFERENCES

- Brucoli M, Arcuri F, Cavenaghi R, Benech A. Analysis of complications after surgical repair of orbital fractures. *J Craniofac Surg*. 2011;22(4):1387-90. DOI: 10.1097/SCS.0b013e31821cc317.
- Zavattero E, Ramieri G, Rocca F, Gerbino G. Comparison of the Outcomes of Complex Orbital Fracture Repair with and without a Surgical Navigation System. *Plast Reconstr Surg*. 2017;139(4):957-65. DOI: 10.1097/PRS.0000000000003229.
- Markiewicz M, Dierks E, Bell R. Does intraoperative navigation restore orbital dimensions in traumatic and post-ablative defects? *J Craniomaxillofac Surgery*. 2012;40(2):142-8. DOI: 10.1016/j.jcms.2011.03.008.
- Markiewicz M, Dierks E, Potter B, Bell R. Reliability of Intraoperative Navigation in Restoring Normal Orbital Dimensions. *J Oral Maxillofac Surg*. 2011;69(11):2833-40. DOI: 10.1016/j.joms.2010.12.043.
- Gellrich NC, Schramm A, Hammer B, Rojas S, Cufi D, Lagrèze E, et al. Computer assisted secondary reconstruction of unilateral posttraumatic orbital deformity. *Plast Reconstr Surg*. 2002;110(6):1417-29. DOI: 10.1097/01.PRS.0000029807.35391.E5.
- Bly RA, Chang SH, Cudejkova M, Liu JJ, Moe KS. Computer guided orbital reconstruction to improve outcomes. *JAMA Facial Plast Surg*. 2013;15(2):113-20. DOI: 10.1001/jamafacial.2013.316.
- Essig H, Dressel L, Rana M, Rana M, Kokemueller H, Ruecker M, et al. Precision of posttraumatic primary orbital reconstruction using individually bent titanium mesh with and without navigation: A retrospective study. *Head Face Med*. 2013;9:18. DOI: 10.1186/1746-160X-9-18.
- Bevans S, Moe K. Advances in the Reconstruction of Orbital Fractures. *Facial Plast Surg Clin North Am*. 2017;25(4):513-35. DOI: 10.1016/j.fsc.2017.06.014.
- Novelli G, Tonellini G, Mazzoleni F, Bozzetti A, Sozzi D. Virtual surgery simulation in orbital wall reconstruction: Integration of surgical navigation and stereolithographic models. *J Craniomaxillofac Surg*. 2014;42(8):2025-34. DOI: 10.1016/j.jcms.2014.09.009.
- Jansen J, Schreurs R, Dubois L, Maal TJJ, Gooris PJJ, Becking AG. The advantages of advanced computer-assisted diagnostics and three-dimensional preoperative planning on implant position in orbital reconstruction. *J Craniomaxillofac Surg*. 2018;46(4):715-21. DOI: 10.1016/j.jcms.2018.02.010.
- Zimmerer R, Ellis E, Aniceto G, Schramm A, Wagner M, Grant M, et al. A prospective multicenter study to compare the precision of posttraumatic internal orbital reconstruction with standard preformed and individualized orbital implants. *J Craniomaxillofac Surg*. 2016;44(9):1485-97. DOI: 10.1016/j.jcms.2016.07.014.
- Strong EB, Fuller SC, Wiley DF, Zumbansen J, Wilson MD, Metzger MC. Preformed vs intraoperative bending of titanium mesh for orbital reconstruction. *Otolaryngol Head Neck Surg*. 2013;149(1):60-6. DOI: 10.1177/0194599813481430.
- Bell R, Markiewicz M. Computer-Assisted Planning, Stereolithographic Modeling, and Intraoperative Navigation for Complex Orbital Reconstruction: A Descriptive Study in a Preliminary Cohort. *J Oral Maxillofac Surg*. 2009;67(12):2559-70. DOI: 10.1016/j.joms.2009.07.098.
- Manson PN, Clifford CM, Su CT, Iliff NT, Morgan R. Mechanisms of global support and posttraumatic enophthalmos: I. The anatomy of the ligament sling and its relation to intramuscular cone orbital fat. *Plast Reconstr Surg*. 1986;77(2):193-202.
- Andrews B, Surek C, Tanna N, Bradley J. Utilization of computed tomography image-guided navigation in orbit fracture repair. *Laryngoscope*. 2013;123(6):1389-93. DOI: 10.1002/lary.23729.
- Bentley RP, Sgouros S, Natarajan K, Dover MS, Hockley AD. Normal changes in orbital volume during childhood. *J Neurosurg*. 2002;96(4):742-6. DOI: 10.3171/jns.2002.96.4.0742.
- Jansen J, Schreurs R, Dubois L, Maal T, Gooris P, Becking A. Orbital volume analysis: validation of a semi-automatic software segmentation method. *International Journal of Computer Assisted Radiology and Surgery*. 2015;11(1):11-8. DOI: 10.1007/s11548-015-1254-6.
- Deveci M, Oztürk S, Sengezer M, Pabuşcu Y. Measurement of orbital volume by a 3-dimensional software program: An experimental study. *J Oral Maxillofac Surg*. 2000;58(6):645-8. DOI: 10.1016/s0278-2391(00)90157-5.
- Schuknecht B, Carls F, Valavanis A, Sailer HF. CT assessment of orbital volume in late post-traumatic enophthalmos. *Neuroradiology*. 1996;38(5):470-5. DOI: 10.1007/BF006072.
- Bite U, Jackson IT, Forbes GS, Gehring DG. Orbital volume measurements in enophthalmos using three-dimensional CT imaging. *Plast Reconstr Surg*. 1985;75(4):502-8. DOI: 10.1097/0006534-198504000-00009.