

Case report

Large dermoid cyst of the floor of the mouth. An emphasis on differential diagnosis

S. Martins, T. Neto, J. Soares y R. Balhau

Maxillofacial Surgery Department, Centro Hospitalar de São João, Porto, Portugal

INFORMACIÓN DEL ARTÍCULO

Historia del artículo:

Recibido el 19 de enero de 2019

Aceptado el 19 de marzo de 2019

Palabras clave:

Dermoid cyst, ranula, floor of the mouth, intraoral approach.

Keywords:

Quiste dermoide, ránula, suelo de boca, abordaje intraoral.

RESUMEN

This article presents the case report of a giant lateral dermoid cyst in the floor of mouth surgically excised by intraoral approach, initially misdiagnosed by imaging studies as a ranula. Other cases of dermoid cysts preoperatively diagnosed ranulae are present in literature, but none directly compares their clinical, radiological and therapeutic aspects. This article will also discuss these aspects in order to possibly aid in their correct diagnosis and management.

Quiste dermoide grande del suelo de la boca. Énfasis en el diagnóstico diferencial

ABSTRACT

Este artículo presenta el caso clínico de un gran quiste dermoide lateral en el suelo de la boca, extirpado quirúrgicamente por abordaje intraoral, inicialmente diagnosticado erróneamente por estudios de imagen como una ránula. Otros casos de quistes dermoides diagnosticados preoperatoriamente como una ránula están presentes en la literatura, pero ninguno compara directamente sus aspectos clínicos, radiológicos y terapéuticos. Este artículo también tratará estos aspectos para, posiblemente, ayudarles en su diagnóstico y manejo correctos.

*Autor para correspondencia:

Correo electrónico: spmrtns@gmail.com (Sara Pereira Martins).

DOI: [10.20986/recom.2019.1040/2019](https://doi.org/10.20986/recom.2019.1040/2019)

1130-0558/© 2019 SECOM. Publicado por Inspira Network. Este es un artículo Open Access bajo la licencia CC BY-NC-ND (<http://creativecommons.org/licenses/by-nc-nd/4.0/>).

INTRODUCTION

Oral dermoid cysts and ranulae are uncommon, frequently misdiagnosed, and often inadequately treated^{1,2}. A dermoid cyst is defined as a closed, epithelium-lined cavity that contains dermal adnexal structures. On the other hand, a ranula is described as a mucocele that occurs in the floor of the mouth, arising from the sublingual gland. When this swelling in the floor of the mouth also dissects through the mylohyoid muscle and produces swelling within the neck it is referred to as plunging ranula³.

Oral dermoid cysts and ranulae both present as painless, soft and compressible lesions, and due to their common anatomical location, may be indistinguishable during clinical examination. However, it is essential to note that the therapeutic options differ considerably for each lesion. Differential diagnosis is the first step towards proper treatment, which is crucial to prevent recurrence and sequelae.

This article presents a large, lateral, dermoid cyst in the floor of mouth, initially misdiagnosed by imaging studies as a ranula. Clinical, radiological and therapeutic aspects of oral dermoid cysts and ranulae will also be discussed to aid in the correct diagnosis and management of these lesions.

CASE REPORT

A 15-year-old male presented with a 6-month history of a slowly growing swelling in the right side of the floor of the mouth. He had no other signs or symptoms and no relevant medical history. Examination showed a soft, non-tender, and non-fluctuant mass with normal overlying mucosa (Figure 1A). Computed tomography (CT) and magnetic resonance imaging (MRI) demonstrated similar results of a well-defined thin walled cystic formation with 7 cm in maximal diameter in the right sublingual space (Figure 1 D-F). Both reports concluded that the findings were consistent with a ranula, and consequently marsupialization was planned. An intraoral incision was used but as an encapsulated lesion with a yellowish thick creamy material was detected submucosally, planned procedure was modified to complete enucleation of the lesion (Figure 1B). Histopathology report stated characteristics compatible with a dermoid cyst. Recovery was uneventful and at reevaluation, 12 months postoperatively, there was no recurrence (Figure 1C).

DISCUSSION

Several pathologic conditions can cause masses in the floor of the mouth. Cases of dermoid cysts preoperatively diagnosed ranulae are present in literature^{1,2,4-6}. This may be due to their similar clinical presentation, as both are painless, soft and compressible lesions, which can cause tongue fullness, with subsequent difficulty with swallowing, speech and breathing^{4,7}. However, ranulae usually present with a blue, dome-shaped swelling, located lateral to the midline. This helps distinguish them from midline dermoid cysts. In the case presented, the dermoid cyst was present at the right side in the floor of the

mouth. This might have been a contributing factor to the initial misdiagnosis, as lateral dermoid cysts are rare⁸.

Imaging studies are important to assist in the differential diagnosis, but may be difficult with dermoid cysts and ranulae, as both appear as thin-walled, cystic lesions, which are hypodense on CT and can present with high-intensity on T2-weighted images on MRI⁹. Nevertheless, each have certain distinguishing characteristics, such as the "sack of marbles" appearance that is pathognomonic for dermoid cysts, caused by areas of fat attenuation on CT¹⁰. Additionally, plunging ranulae may demonstrate a thin "tail" of fluid from the collapsed sublingual space that appears to dive into the submandibular space on imaging; this sign can occasionally be seen on CT and MR imaging, and can be an important diagnostic clue when visualized^{9,10}. In the present case, the appearance on CT and MRI imaging reports misdiagnosed the lesion as a ranula.

It is important to make the correct clinical diagnosis, as therapeutic options differ considerably between ranulae and dermoid cysts. Treatment for ranulae consists of removal of the feeding sublingual gland and/or marsupialization¹¹. In contrast, the only effective treatment for dermoid cysts is surgical removal with complete enucleation³. A diversity of opinions remain on the whether enucleation of dermoid cysts via extraoral or intraoral approach should be preferred, with anatomical location and size as the most significant considerations¹². It has been suggested that dermoid cysts larger than 6 cm in diameter and located sublingually should be excised with extraoral approach, whereas in lesions less than 6 cm in diameter, found above the mylohyoid muscle, an intraoral approach is more suitable and should be preferred because of its cosmetic results¹². In the case presented, a successful intraoral surgical excision of a dermoid cyst measuring 7 cm maximal diameter is shown.

Differential diagnosis of masses in the floor of the mouth such as vascular anomalies, thyroglossal duct cyst, infectious processes, lymphatic malformation, and tumors should also be considered^{2,7}. Due to the history, clinical presentation and radiologic aspects of our case, other diagnosis were ruled out and marsupialization of a ranula was planned as treatment. Intraoperative features of a true cystic lesion with an interior of a yellowish thick creamy material ultimately led to the correct diagnosis of dermoid cyst, later confirmed with histological examination.

CONCLUSION

Dermoid cysts and ranulae are commonly misdiagnosed due to their scarcity and relatively similar clinical presentations. An overview of the characteristics of both dermoid cysts and ranulae is presented below (Table I). This article aims to show practical differences to assist in their correct diagnosis and management. In conclusion and most importantly, intraoperative features should be taken in account for adequate management, as in the present case.

CONFLICTS OF INTEREST

The authors report no conflicts of interest.

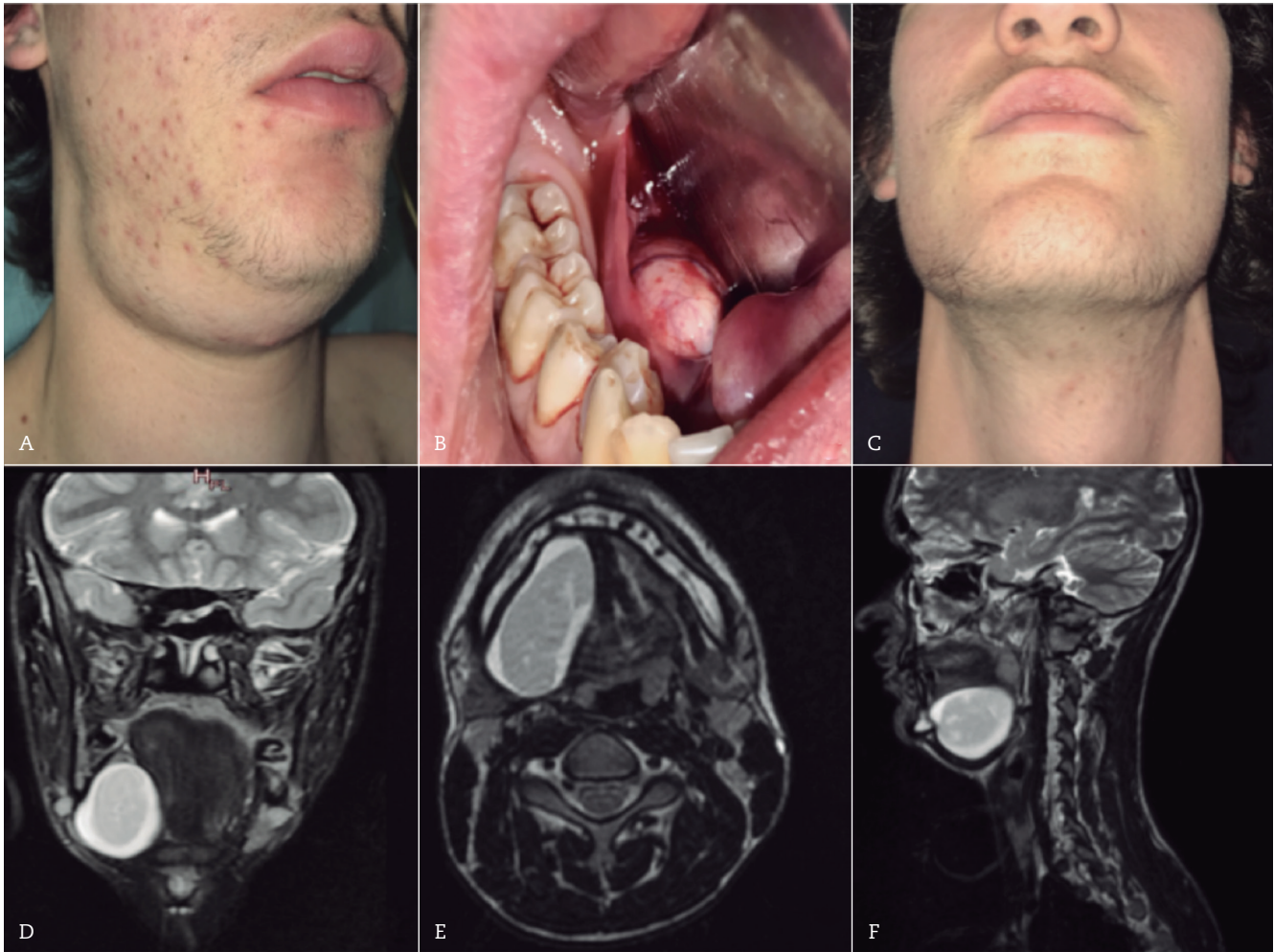


Figure 1. A: preoperative clinical photograph showing double chin appearance; B: intraoperative photograph showing a cystic lesion of floor of the mouth during intraoral approach; C: 1 week postoperative clinical photograph; D: preoperative MRI images of the large lesion in the right sublingual space - Coronal slice; E: axial slice; F: sagittal slice.

Table I. Overview of the salient features present in dermoid cysts and ranulae		
Dermoid cysts and Ranulae Main Features		
	Dermoid Cyst	Ranula
Clinical Presentation		Painless, soft and compressible lesions
May present yellow hue seen through the skin	Blue coloration, but deeper lesions may be normal in color	
Typically located on the midline	Usually is located lateral to the midline	
Imaging	CT	Thin walled, hypodense, unilocular mass Pathognomonic “sack of marbles” appearance caused by multiple hypo-attenuating fat nodules Without areas of fat attenuation
	MRI	High-intensity on T2-weighted images T1-weighted imaging demonstrates a variable signal depending on fat content Plunging ranulas often exhibit a slight extension of the lesion into the sublingual space, known as a “tail sign”
Macroscopic aspects visible during surgery	Encapsulated lesion with soft, yellow material, often with cutaneous elements such as hair in the interior	Collected mucin, lacking epithelial lining (mucocele)
Treatment	Complete enucleation	Removal of the feeding sublingual gland and/or marsupialization

FUNDING

The present investigation has not received specific grants from agencies of the public sector, commercial sector or non-profit entities.

REFERENCES

1. Puricelli E, Barreiro B, Quevedo AS, Ponzoni D. Occurrence of dermoid cyst in the floor of the mouth: the importance of differential diagnosis in pediatric patients. *J Appl Oral Sci.* 2017;25(3):341-5. DOI: 10.1590/1678-7757-2016-0411.
2. Vieira EM, Borges AH, Volpato LE, Porto AN, Carvalhosa AA, Botelho G, et al. Unusual dermoid cyst in oral cavity. *Case Rep Pathol.* 2014;2014:389752. DOI: 10.1155/2014/389752.
3. Neville BW, Damm DD, Allen CM, Chi AC. *Oral and Maxillofacial Pathology.* 4th ed. St. Louis: Elsevier; 2016.
4. Linnard H, Newman L, Barrett AW. Dermoid cyst of the submandibular gland: case report. *Br J Oral Maxillofac Surg.* 2017;55(9):983-4. DOI: 10.1016/j.bjoms.2017.06.018.
5. Lee MA, Lee CS, Sim CX, Nagadia R. Sublingual dermoid cyst: Case report and a review of the clinical, radiological and histological aspects of this rare condition. *Oral Surg.* 2018;11(2):147-52. DOI: 10.1111/ors.12320.
6. Verma S, Kushwaha JK, Sonkar AA, Kumar R, Gupta R. Giant sublingual epidermoid cyst resembling plunging ranula. *Natl J Maxillofac Surg* 2012;3(2):211-3. DOI: 10.4103/0975-5950.111386.
7. Schwanke TW, Oomen KP, April MM, Ward RF, Modi VK. Floor of mouth masses in children: proposal of a new algorithm. *Int J Pediatr Otorhinolaryngol.* 2013;77(9):1489-94. DOI: 10.1016/j.ijporl.2013.06.016.
8. Longo F, Maremonti P, Mangone GM, De Maria G, Califano L. Midline (dermoid) cysts of the floor of the mouth: report of 16 cases and review of surgical techniques. *Plast Reconstr Surg.* 2003;112(6):1560-5. DOI: 10.1097/01.PRS.0000086735.56187.22.
9. Patel H, Mayl J, Chandra B, Pritchett C, Chandra T. Dermoid of the oral cavity: case report with histopathology correlation and review of literature. *J Radiol Case Rep.* 2016;10(12):19-27. DOI: 10.3941/jrcr.v10i12.2995.
10. Kurabayashi T, Ida M, Yasumoto M, Ohbayashi N, Yoshino N, Tetsumura A, et al. MRI of ranulas. *Neuroradiology.* 2000;42(12):917-22. DOI: 10.1007/s002340000341.
11. Patel MR, Deal AM, Shockley WW. Oral and plunging ranulas: what is the most effective treatment? *Laryngoscope.* 2009;119(8):1501-9. DOI: 10.1002/lary.20291.
12. El-Hakim IE, Alyamani A. Alternative surgical approaches for excision of dermoid cyst of the floor of mouth. *Int J Oral Maxillofac Surg.* 2008;37(5):497-9. DOI: 10.1016/j.ijom.2007.12.004.