



Artículo especial

Patterns of maxillofacial injuries due to motorcycle-related road traffic accidents: a descriptive study

Waleed Khalil Ismael¹ and Mohammed Muwafaq Abed*²

¹Consultant, Head of the Department of Oral and Maxillofacial Surgery, Al Yarmouk Teaching Hospital, Baghdad, Iraq. ²Department of Oral and Maxillofacial Surgery, Al Yarmouk Teaching Hospital, Baghdad, Iraq

ARTICLE INFORMATION

Article history:

Received: 03-01-2025

Accepted: 11-05-2025

Keywords:

Motorcycle accidents, maxillofacial injuries, facial bone fractures.

A B S T R A C T

Introduction: Maxillofacial trauma is a common injury resulting from various causes, with motorcycle-related road traffic accidents being a significant factor. Motorcycles are a widely used mode of transportation and are frequently involved in collisions that cause facial bone fractures and soft tissue damage. This study aimed to investigate the patterns of maxillofacial injuries associated with motorcycle accidents.

Patients and methods: A total of 105 patients were enrolled in this study. All patients had suffered maxillofacial injuries due to motorcycle accidents. The variables analysed included age, helmet wearing, intoxication, maximum motorcycle speed, types of tissue injury, anatomical site, facial fracture patterns, types of soft tissue injury, concomitant injuries, types of treatment, and types of anaesthesia.

Results: All patients were men. Three patients died before receiving maxillofacial treatment, leaving 102 patients available for statistical analysis. Ages ranged from 16 to 60 years, with an average of 27 years and a standard deviation of ± 9.95 . Most of the patients (87.25 %) did not wear helmets and rode motorcycles at a maximum speed of 120 km/h or less (65.69 %). Of these patients, 25.5 % were intoxicated. The majority of patients (61.76 %) presented combined soft and hard tissue facial injuries. Of the 63 patients with facial fractures, the most common site was the midface, occurring in 30 patients (47.62 %), while the most common type of soft tissue injury was laceration. Concomitant injuries were present in 43 patients (42.16 %), most of whom had head injuries.

Conclusions: Motorcycle crashes predominantly involved young male riders and commonly resulted in a wide range of facial fractures. The usage of helmets among motorcyclists remained limited due to factors such as a lack of enforced legislation, economic constraints, and rider negligence. High-speed motorcycle collisions frequently resulted in severe and complex injuries involving both soft and hard tissues.

*Correspondence:

E-mail: mohammed.muwafaq5@gmail.com (Mohammed Muwafaq Abed).

<http://dx.doi.org/10.20986/recom.2025.1592/2025>

1527-2024/© 2024 SECOM CyC. Publicado por Inspira Network. Este es un artículo Open Access bajo la licencia CC BY-NC-ND (<http://creativecommons.org/licenses/by-nc-nd/4.0/>).

Patrones de lesiones maxilofaciales por accidentes de tráfico relacionados con motocicletas: un estudio descriptivo

R E S U M E N

Palabras clave:

Accidentes de motocicleta, lesiones maxilofaciales, fracturas de huesos faciales.

Introducción: Los traumatismos maxilofaciales son unas lesiones comunes que se deben a diversas causas, siendo los accidentes de tráfico relacionados con motocicletas un factor significativo. Las motocicletas son un medio de transporte ampliamente utilizado y con frecuencia se ven involucradas en colisiones que causan fracturas óseas faciales y daños a los tejidos blandos. Este estudio tuvo como objetivo investigar los patrones de lesiones maxilofaciales asociadas con accidentes de motocicleta.

Pacientes y métodos: Se incluyeron 105 pacientes en este estudio. Todos los pacientes sufrieron lesiones maxilofaciales debido a accidentes de motocicleta. Las variables analizadas incluyeron edad, uso de casco, intoxicación, velocidad máxima de la motocicleta, tipo de lesión tisular, localización anatómica, patrones de fractura facial, tipo de lesión de tejidos blandos, lesiones concomitantes, tipo de tratamiento y tipo de anestesia.

Resultados: Todos los pacientes eran hombres. Tres pacientes fallecieron antes de recibir el tratamiento maxilofacial, por lo que hubo 102 pacientes disponibles para el análisis estadístico. Las edades oscilaron entre los 16 y los 60 años, con una media de 27 años y una desviación estándar de $\pm 9,95$. La mayoría de los pacientes (87,25 %) no usaban casco y conducían motocicletas a una velocidad máxima de 120 km/h o menos (65,69 %). De estos pacientes, el 25,5 % estaban intoxicados. La mayoría de los pacientes (61,76 %) presentaban lesiones faciales combinadas de tejidos blandos y duros. De los 63 pacientes con fracturas faciales, la localización más frecuente fue el tercio medio facial, con 30 pacientes (47,62 %), mientras que la lesión más frecuente de tejidos blandos fue la laceración. Se presentaron lesiones concomitantes en 43 pacientes (42,16 %), la mayoría de los cuales presentaron traumatismos craneoencefálicos.

Conclusiones: Los accidentes de motocicleta afectan predominantemente a conductores varones jóvenes y suelen provocar una amplia variedad de fracturas faciales. El uso del casco entre los motociclistas sigue siendo limitado debido a factores como la falta de legislación, las limitaciones económicas y la negligencia del conductor. Las colisiones de motocicletas a alta velocidad con frecuencia provocan lesiones graves y complejas que afectan tanto a los tejidos blandos como a los duros

INTRODUCTION

Road traffic accidents (RTA) cause nearly 1.2 million deaths and 50 million injuries worldwide every year. They have injured 50 million people worldwide and interrupted the lives of thousands, especially during the first decades of life¹. There is a significant variation between countries, which may be due to differences in the strictness with which laws and regulations are implemented².

Motorcycles (MC) are a common means of transport, as they are relatively small and lightweight, but less stable than other vehicles. They also lack safety features such as seatbelts, which increases the risk of facial injury. These vehicles are known as the most dangerous because their riders have a 34-fold higher risk of death and an eight-fold higher risk of injury than people driving other types of vehicles for each mile that the vehicle travels³. The situation is further compounded by many other risk factors, including the condition and nature

of the roads, traffic flow, and poor visibility at night, as well as human factors such as the attitude and behaviour of riders on the roads, speeding, ignoring safety measures such as wearing crash helmets and protective clothing, and the abuse of alcohol and drugs before riding².

Motor vehicle crashes (MVC) are the main cause of maxillofacial injuries in many regions around the world. Most maxillofacial fractures occur in men aged 21 to 30, with male predominance⁴. This study aims to investigate the patterns of maxillofacial injuries related to MC accidents and the anatomical sites of facial fractures and concomitant injuries.

PATIENTS AND METHODS

This descriptive, prospective study was conducted between January 2023 and August 2024 at the Maxillofacial Surgery Department of Al-Yarmouk Teaching Hospital in Iraq. It

formed part of the requirements for the Maxillofacial Surgery fellowship under the auspices of the Iraqi Board for Medical Specialisations. The study was approved by the Research Ethics Committee and written informed consent was obtained from all participants.

A total of 105 Iraqi male patients, aged between 16 and 62 years, were enrolled in the study. All patients had sustained maxillofacial injuries resulting from motorcycle collisions (MCC), with or without fractures to other parts of the body. The inclusion criteria for this study were patients who suffered maxillofacial injuries due to MCC, with or without concomitant injuries. Patients with maxillofacial injuries due to causes other than MCC that affect parts of the body other than the maxillofacial region were excluded.

Clinical examination. The primary survey included assessing airway and abnormal breathing. All significantly injured patients were assumed to have a cervical spine injury until proven otherwise. The survey also included an examination for external bleeding and a rapid neurological assessment to determine the level of consciousness using the Glasgow Coma Scale. A full body examination (from head to toe) was carried out. Clinical signs of soft tissue injuries and bone fractures were investigated, including extra-oral signs such as gross visual asymmetry, ecchymosis, lacerations, and abrasions, and intra-oral signs such as injuries to the oral mucosa, soft and hard palate, and occlusal disturbances, as can be observed in Figure 1.

Radiographic examination. When fractures of the maxillofacial region were suspected, radiographic imaging was requested to confirm and characterise the fracture type, location, and pattern. In this study, the imaging modalities were plain radiographs, CBCT, and CT scans, as shown in Figure 2.

RESULTS

One hundred and two male patients were included in this study. Their ages ranged from 16 to 60 years, with an average age of 26.99 years, a standard deviation of 9.95 years, and a median age of 24 years. According to the median age, they were divided into two groups: ≤ 24 years (51.96 %) and >24 years (48.04 %). Of these patients, 12.75 % were wearing helmets, while 87.25 % did not. Regarding alcohol intoxication, 25.5 % of the patients were intoxicated at the time of the accident, compared to 74.5 % who were not. Regarding maximum MC speed, 65.69 % of the patients travelled at 120 km/h or less, while 34.31 % travelled at more than 120 km/h, doubling the likelihood of an RTA with an increased maximum speed of MC.

Types of tissue injury. Most patients (61.76 %) presented with a combination of soft and hard tissue injuries, while 38.24 % had only soft tissue injuries and none had solitary hard tissue injuries.

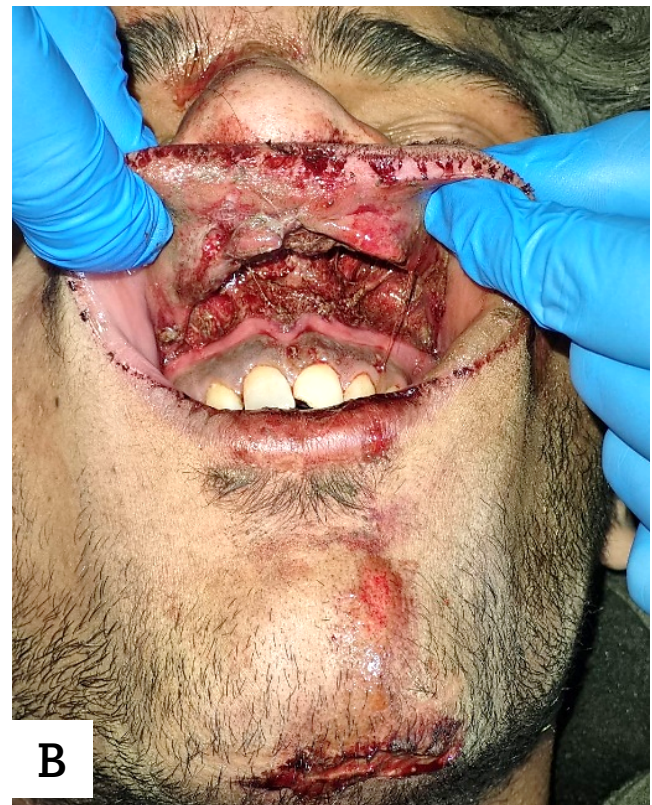
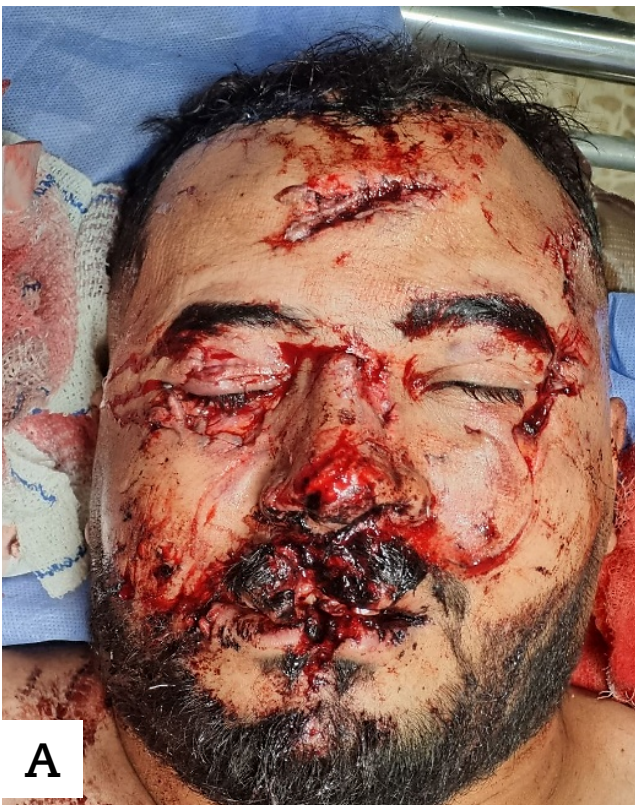
Figure 1. A: patient with a motorcycle RTA presenting with a crushed upper lip, a laceration to the forehead, and a laceration to the left lateral eye, as well as a nasal fracture. B: an open lacerated wound in the upper vestibule filled with dust and tar.

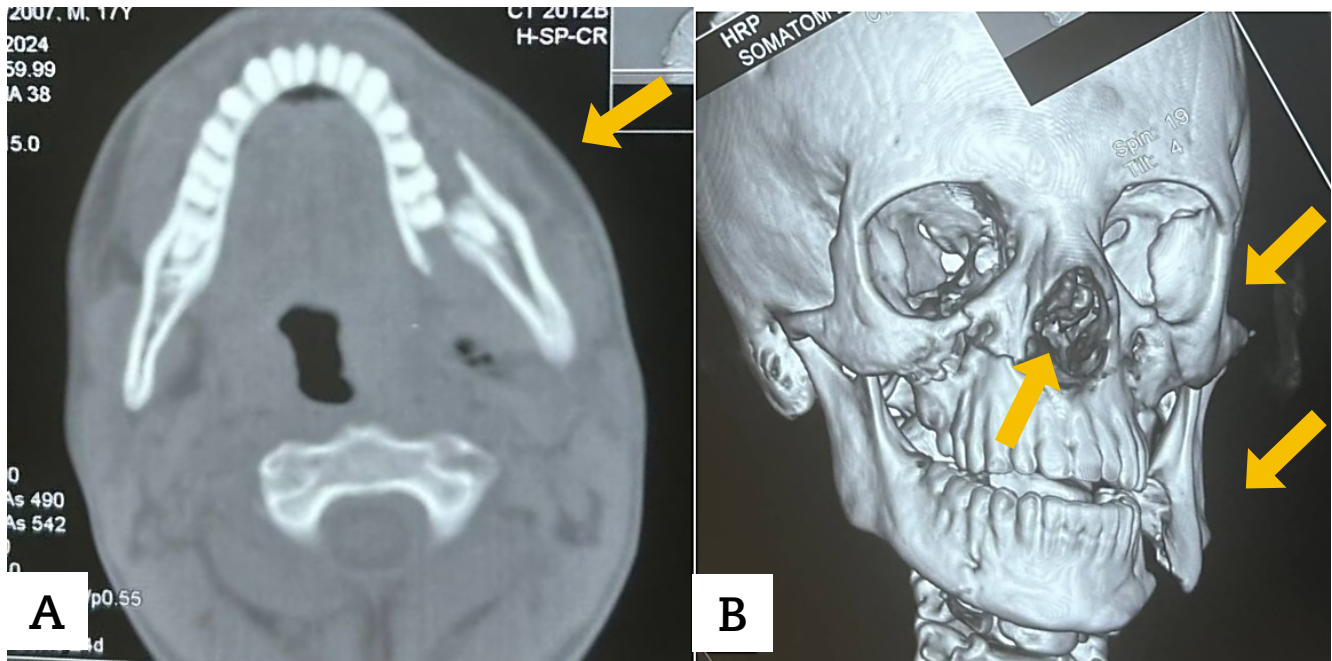


Figure 2. A: CT scan showing an unfavourable fracture of the left side of the mandible in axial view (arrow). B: 3D reconstruction showing multiple facial fractures (arrows).

Anatomical site and anatomical location of fractures. Facial bone fractures were found in 63 patients. Of these, 36.51 % had a single lower third fracture, 47.62 % had a middle third fracture only, and 15.87 % had a combination of the two. The distribution of victims of MCC according to the anatomical location of the mandibular fracture and the types of midface fracture is shown in Table I.

Table I. Distribution of fractures according to anatomical site and location.		
Anatomical site of the fracture		
Site/ Patients	N of patients	%
Middle third	30	47.62
Mandible	23	36.51
Combination	10	15.87
Total	63	100
Anatomical location of the mandible fracture (n=53)		
Anatomical site	N of fractures	%
Condyle	21	39.63
Body	11	20.75
Parasymphysis	8	15.09
Alveolar bone	6	11.33
Symphysis	5	9.43
Angle	2	3.77
Types of middle and upper face fractures (n=68)		
Anatomical site	N of fractures	%
Zygomaxillary complex	21	30.87
Maxilla	11	16.18
Orbit	10	14.71
Nasal	10	14.71
Alveolar bone	10	14.71
Naso-orbito-ethmoidal	4	5.88
Frontal	2	2.94

Pattern of facial fractures according to anatomical site. Among riders, the pattern of facial bone fractures consists of either linear or comminuted fractures. This study included 121 fractures at various anatomical sites, as shown in Table II.

Types of soft tissue injuries. Of the 102 patients, 46.08 % had lacerations, 32.35 % had abrasions, and 21.57 % had a combination of soft tissue injuries.

Concomitant injuries. 42.16 % presented with concomitant injuries, compared to 57.84 % without. The distribution of other injuries is shown in Table III.

Table II. Pattern of facial fractures according to the anatomical site.		
Anatomical site	Linear	Comminuted
Mandible (n = 53)	47 (88.7 %)	6 (11.3 %)
Mid- and upper third (n = 68)	19 (27.9 %)	49 (72.1 %)
Total (n = 121)	66 (54.5 %)	55 (45.5 %)

Table III. Distribution of other injuries associated with MCC.		
Site	Injuries (n = 74)	%
Head injuries	22	29.73
Tibia	16	21.62
Forearm	15	20.26
Fibula	8	10.8
Femur	5	6.76
Pelvis	4	5.4
Ribs	3	4.05
Clavicle	1	1.38

Facial fractures. Of the patients with facial bone fractures, 63 (61.76 %) were treated surgically. 19.05% were treated with closed reduction, while 80.95 % were treated with open reduction and internal fixation (ORIF).

Correlation between helmet-wearing and independent variables. Table IV shows the correlation between the helmet-wearing patients at the time of the accident and the study variables for 102 patients.

Table IV. Correlation between helmet-wearing and independent variables.

Variables	Wearing Helmet		P.Value
	Yes	No	
Median age (n = 102)	n = 13	no = 89	
≤ 24 Yrs	7 (53.8 %)	46 (51.7 %)	0.884 (NS) Chi-Square
> 24 Yrs	6 (46.2 %)	43 (48.3 %)	
Intoxication (n = 102)	n = 13	n = 89	
Yes	2 (15.4 %)	24 (27.0 %)	0.371 (NS) Chi-Square
No	11 (84.6 %)	65 (73.0 %)	
Type of Tissue Injury (n = 102)	n = 13	n = 89	
Soft tissue alone	7 (53.8 %)	32 (36.0 %)	0.215 (NS) Chi-Square
Combination (hard and soft tissue)	6 (46.2 %)	57 (64.0 %)	
Anatomical Site of Fracture (n = 63)	n = 6	n = 57	
Mandible	4 (66.6%)	18 (31.6%)	0.197 (NS) Chi-Square
Middle Third	1 (16.7%)	29 (50.9%)	
Combination	1 (16.7%)	10 (17.5%)	
Pattern of Facial Fracture (n = 121)	n = 10	n = 111	
Linear	7 (70 %)	59 (53.1 %)	0.305 (NS) Chi-Square
Comminuted	3 (30 %)	52 (46.9 %)	
Type of Soft Tissue Injury (n = 102)	n = 13	n = 89	
Laceration	8 (61.5 %)	39 (43.8 %)	0.347 (NS) Chi-Square
Abrasions	2 (15.4 %)	31(34.8 %)	
Combination	3 (23.1 %)	19 (21.4 %)	
Concomitant Injury (n = 102)	n = 13	n = 89	
Yes	4 (30.7 %)	39 (43.8 %)	0.373 (NS) Chi-Square
No	9 (29.3 %)	50 (56.2 %)	
Fracture Treatment (n = 63)	n = 6	n = 57	
Closed Reduction	0	12 (21.0 %)	0.585 (NS) Fisher`s exact
ORIF	6 (100 %)	45 (79.0 %)	

Tests: Chi-squared P-value and Fisher's exact. P = probability value. NS = non-significant.

Correlation between maximum speed and independent variables. Table V shows that the maximum speed of the MC is correlated with the other study variables among the 102 patients.

Table V. Correlation between the maximum speed of motorcycles and the study variables.

Variables	Maximum Speed		P.Value
	≤ 120 km/h	> 120 km/h	
Median age (n = 102)	n = 67	n = 35	
≤ 24 Yrs	36 (53.7 %)	17 (48.6 %)	0.62 (NS)
> 24 Yrs	31 (46.3 %)	18 (51.4 %)	
Intoxication (n = 102)	n = 67	n = 35	
Yes	18 (26.9 %)	8 (22.9 %)	0.659 (NS)
No	49 (73.1 %)	27 (77.1 %)	
Helmet (n = 102)	n = 67	n = 35	
Yes	7 (10.4 %)	6 (17.1 %)	0.336 (NS)
No	60 (89.6 %)	29 (82.9 %)	
Type of Tissue Injury (n=102)	n = 67	n = 35	
Soft tissue alone	28 (41.8 %)	11 (31.4 %)	0.306 (NS)
Combination (hard and soft tissue)	39 (58.2 %)	24 (68.4 %)	
Anatomical Site of Fracture (n = 63)	n = 39	n = 24	
Mandible	12 (30.8 %)	11 (45.8 %)	0.412 (NS)
Middle Third	21 (53.8 %)	9 (37.5 %)	
Combination	6 (15.4 %)	4 (16.7 %)	
Pattern of Facial Fracture (n = 121)	n = 75	n = 46	
Linear	51 (68 %)	15 (32.6 %)	0.0002
Comminuted	24 (32 %)	31 (67.4 %)	
Type of Soft Tissue Injury (n = 102)	n = 67	n = 35	
Laceration	31 (46.3 %)	16 (45.7 %)	0.09 (NS)
Abrasions	22 (32.8 %)	11 (31.4 %)	
Combination	14 (20.9 %)	8 (22.9 %)	
Concomitant Injury (n = 102)	n = 67	n = 35	
Yes	28 (41.8 %)	15 (42.9 %)	0.917 (NS)
No	39 (58.2 %)	20 (57.1 %)	
Fracture Treatment (n = 63)	n = 39	n = 24	
Closed Reduction	8 (20.5 %)	4 (16.7 %)	0.706 (NS)
ORIF	31 (79.5 %)	20 (83.3 %)	

Test: Chi-squared P-value. P = probability value. NS = non-significant.

Mortality. Three patients died in the emergency room before receiving maxillofacial treatment. All three patients shared some variables. All of them did not wear helmets and presented with a combination of hard and soft tissue injuries, as well as concomitant injuries, especially head injuries, although only one of them had a fracture of the facial bones.

DISCUSSION

Age. The patients in this study were aged between 16 and 60 years old, with an average age of 26.99 years and a median age of 24 years. It is possible that these results are due to the fact that most of the patients enrolled in this study were students or young, active individuals involved in daily transportation and outdoor activities. These results are consistent with those of an earlier study by Ariawan et al. (2024)⁵, who reported a mean age of 26.7 years, but inconsistent with those of Adebayo et al. (2023)⁶, who reported a mean age of 32.8 years.

Gender. This study showed a preponderance of males over females in all cases (100% male). This may be because, in our society, men are more likely to use MC for transportation and work, increasing their exposure to potential accidents. These results are consistent with those of a previous study by Mousavi-Shalmai et al. (2023)⁷, which found that this type of accident occurred more frequently in men (95.2 %) than in women (4.8 %).

Helmet wearing. In the current study, few patients were wearing helmets (12.75 %), compared to 87.25 % who were not. We assumed that these results were due to economic issues in areas with limited per capita income, as well as the hot climate, which may lead to a decrease in the number of riders wearing helmets while driving MC. In this study, the type and age of the helmets were not considered. The results of this study are aligned with those obtained by Zahoor et al. (2023)⁸. However, our results conflict with those of Ariawan et al.⁵, who found that 54.5 % of riders were not wearing helmets, compared to 45.5 % who were.

Intoxication. According to Noorali et al. (2023)¹, 20.3 % of patients involved in MCC were under the influence of alcohol at the time of the MVC, compared to 79.3 % who were sober. Therefore, this study is consistent with those previous results, which can be interpreted in two main ways. Firstly, alcohol consumption is often discouraged or prohibited due to religious beliefs or health concerns. This cultural context leads to fewer people consuming excessive amounts of alcohol. The second aspect is that some alcohol drinkers are aware that the likelihood of accidents increases when driving under the influence of alcohol.

Types of tissue injury. Most of the patients in this study had a combination of soft and hard maxillofacial tissue injuries (61.76 %). These results were due to direct impact with hard, stiff surrounding objects at the time of the accident while travelling at medium to high speed on a MC, resulting in a force of impact that was higher than the resistance of the facial bones and leading to fractures and soft tissue injuries. The remaining 38.24 % presented isolated soft tissue injuries, which may have been caused by low-speed accidents or falls on softer surfaces, such as grass or mud. These results are consistent with those obtained by Noorali et al. (2023)¹, who found that

combination tissue injuries were more prevalent than single soft tissue injuries. However, they contradict the findings of Hasnah and Iqbal (2011)⁹.

Anatomical site and location of fractures. Approximately half of patients with facial bone fractures have fractures in the middle third of the face. This is due to the anterior projection of the thin bones of the middle third compared to the mandible. Most of these riders would expose their midface, thinking that it would facilitate breathing and improve sight and hearing. The distribution of results varied among the studies, each showing a different pattern, such as that reported by Júnior et al. (2012)¹⁰, Obimakinde et al. (2018)¹¹, and Kapoor and Kalra (2012)¹². This variety may be due to the difference in the geographic regions in which these studies were conducted, given that each region has different traffic rules, social habits, and economic levels.

Pattern of facial fractures. Of the 63 patients with maxillofacial bone fractures, 121 fracture sites were identified. The fracture pattern was linear in 54.5 % of the cases and comminuted in 45.5 % of the cases. These results are consistent with those of Júnior et al. (2012)¹⁰, who reported a higher incidence of linear fractures than comminuted fractures.

Types of soft tissue injuries. A study conducted by Arif et al. (2019)¹³ examined different types of facial soft tissue injuries associated with MCC. They found that soft tissue abrasions (36.2 %) were more prevalent than lacerations (28.7 %), which aligns with the two main types of soft tissue injuries identified in our study. However, that study did not examine the occurrence of these injuries in the same patient. These results contradict those of Noorali et al. (2023)¹, who found that the most common soft tissue injuries were lacerations (46.08 %), followed by abrasions (32.35 %) and a combination of the two (21.57 %).

Concomitant injuries. In our study, 57.84 % had no concomitant injuries, while 42.16 % had injuries to the skull or body. The most common injury was to the head (29.73 %), followed by a tibial fracture (21.26 %).

Treatment. Of the patients, 38.24 % required only soft tissue treatment, either suturing or conservative, while 61.76 % were treated surgically, either with closed reduction (19.05 %) or ORIF (80.95 %). These findings are consistent with those of Abhinav et al. (2019)¹⁴.

Correlation between helmet-wearing and other variables. The present study found no statistically significant difference in helmet use according to age group, alcohol intoxication, or maxillofacial injury. This indicates that helmets alone do not provide sufficient protection in high-speed collisions. However, patients not wearing helmets sustained more severe injuries, including fractured bones and soft tissue injuries. Additionally, the poor quality of some helmets, which broke and splintered during accidents, contributed to further facial trauma. These results are supported by the study by Kong et al. (2013)¹⁵. In contrast, Zahoor et al. (2023)⁸ found that helmeted patients in MCC experienced significantly fewer maxillofacial injuries than those without helmets at the time of the RTA. This may be due to the quality of helmets minimising the severity of injuries.

Correlation between the maximum speed of motorcycles and other variables. There was no statistically significant difference in maximum speed and variables such as age group, intoxication, and helmet use, except for the pattern of facial

fractures. In fact, the maximum speed of MC had a statistically significant effect on the pattern of facial fractures and MCC. Patients riding two-wheeled vehicles at a maximum speed greater than 120 km/h were more likely to sustain comminuted and complex facial fractures than those riding at a maximum speed below 120 km/h. Although the effect of maximum speed on the occurrence and types of soft tissue injury and concomitant injury was not statistically significant, these injuries were more prevalent and severe in patients riding at high speeds. Regarding the complexity and severity of facial fractures only, the findings are consistent with those of an earlier study by Deliverska (2016)¹⁶.

Mortality. Of the 105 patients brought to the emergency room due to MCC, only three (2.86 %) died during ABCs of emergency care before receiving maxillofacial treatment.

Limitations of the study. The main limitations of this study were the small sample size, the short study period, and the fact that it was a unicentric study conducted in one hospital.

CONCLUSIONS

MCCs primarily affect young men and lead to a variety of facial fractures. The use of helmets among riders was very limited due to the absence of legislation, financial status, and rider carelessness. Even among those who wore helmets, many used the half-type helmet, which did not protect the whole face, or poor-quality helmets. High-speed MCC were associated with severe and complex injuries to soft and hard tissues in most cases. Middle-third fractures were the most common type of fracture, with zygomaticomaxillary complex fractures being the most common among other midfacial bones. Lacerations were the most common soft tissue injury in patients with MCC, and most cases involving concomitant injuries were due to head trauma.

FUNDING

There is no funding to declare.

REFERENCES

- Noorali IS, Attyia MA, Alsunbuli MM. Patterns of maxillofacial injuries caused by motorcycle accidents. *Intl Arch Otorhinolaryngol.* 2023;27(2):309-15. DOI: 10.1055/s-0042-1744256.
- Hameed F, Gul W, Ali I, Hanif T. Pattern of maxillofacial injuries due to motorcycle-related road traffic accidents at a tertiary care hospital in Karachi, Pakistan. *Ann Jinnah Sindh Med Uni.* 2017;3(2):80-5.
- Acheampong AO, Newman-Nartey M, Obiri-Yeboah S, Mensah J, Amuasi A, Sabbah D, Olesu J, et al. Motorcycle related oral and maxillofacial injuries seen at Komfo Anokye Teaching Hospital, Kumasi-Ghana. *Surgical Science.* 2019;10(3):106-12. DOI: 10.4236/ss.2019.103014
- Al-Hassani A, Ahmad K, El-Menyar A, Abutaka A, Mekkodathil A, Peralta R, Al Khalil M, et al. Prevalence and patterns of maxillofacial trauma: a retrospective descriptive study. *Eur J Trauma Emerg Surg.* 2022;48(4):2513-9. DOI: 10.1007/s00068-019-01174-6.
- Ariawan D, Dharmawan DK, Gondosudiro R, Julia V, Sulistyani LD, Ruslin M, et al. Characteristics of Maxillofacial Trauma in Motorcycle Accidents at a Regional General Hospital in Indonesia: A Five-year Retrospective Study using the Facial Injury Severity Scale (FISS) and Maxillofacial Injury Severity Score (MFISS). *Open Dent J.* 2024;18(1). DOI: 10.2174/0118742106308518240604052429.
- Adebayo ET, Fomete B, Adelusi EA, Ahaji LE, Nnawuhie UC. Maxillofacial injuries due to motorcycle accidents from sub-urban Nigeria. *J Oral Maxillofac Surg Med Pathol.* 2023;35(1):30-5. DOI: 10.1016/j.ajoms.2022.07.014.
- Mousavi-Shalmaei SM, Hosseinnia M, Mohtasham-Amiri Z, Rad EH, Khodadadi-Hassankiadeh N. Helmet use and jaw and tooth injuries in motorcyclists admitted to a referral hospital. *J Maxillofac Oral Surg.* 2023;22(3):1-6. DOI: 10.1007/s12663-023-01934-3.
- Zahoor S, Mohsin Majeed AN, Rashid N, Fareed S, Mustafa N. Pattern of Maxillofacial Injuries in Patients of Motor Bike Accidents with Helmet and without Helmet. *InMed Forum Month.* 2023;34:5.
- Hashim H, Iqbal S. Motorcycle accident is the main cause of maxillofacial injuries in the Penang Mainland, Malaysia. *Dental Traumatol.* 2011;27(1):19-22. DOI: 10.1111/J.1600-9657.2010.00958.X
- Júnior SM, Santos SE, Kluppel LE, Asprino L, Moreira RW, De Moraes M. A comparison of motorcycle and bicycle accidents in oral and maxillofacial trauma. *J Oral Maxillofac Surg.* 2012;70(3):577-83. DOI: 10.1016/j.joms.2011.03.035.
- Obimakinde OS, Olajuyin OA, Rabi TB, Olanrewaju OJ. Crash characteristics and pattern of motorcycle related facial bone fractures in a sub-urban Nigerian teaching hospital. *Niger J Surg.* 2018;24(2):71-5. DOI: 10.4103/njs.NJS_39_17.
- Kapoor P, Kalra N. A retrospective analysis of maxillofacial injuries in patients reporting to a tertiary care hospital in East Delhi. *Int J Crit Illn Inj Sci.* 2012;2(1):6-10. DOI: 10.4103/2229-5151.94872.
- Arif MZ, Rajanikanth BR, Prasad K. Soft tissue injuries of the maxillofacial region occurring from motorcycle accidents. *J Maxillofac Oral Surg.* 2019;18(3):432-9. DOI: 10.1007/s12663-018-1149-5.
- Abhinav RP, Selvarasu K, Maheswari GU, Taltia AA. The patterns and etiology of maxillofacial trauma in South India. *Ann Maxillofac Surg.* 2019;9(1):114-7. DOI: 10.4103/ams.ams_233_18.
- Kong DY, Kim HJ, Kang TK, Oh SC, Cho SJ, Choi SW, Ryu SY. The association between facial fracture patterns and traumatic head injury in injured motorcycle riders according to helmet use status. *Hong Kong J Emerg Med.* 2013;20(4):204-9. DOI: 10.1177/102490791302000403.
- Deliverska E. Maxillofacial fractures in patients with multiple injuries and polytrauma. *J IMAB-Annual Proceed Sci Papers.* 2016;22(2):1120-6. DOI: 10.5272/jimab.2016222.1120.