

BIBLIOGRAFÍA

1. Seibert JS. Reconstruction of deformed, partially edentulous ridges, using full thickness onlay grafts. Part I. Technique and wound healing. *Compend Contin Educ Dent.* 1983;4: 437-53.
2. Muñoz J. Como identificar, prevenir y tratar las complicaciones en implantología. Madrid: Ripano; 2012.
3. Lew D, Clark R, Shahbazian T. Use of a soft tissue expander in alveolar ridge augmentation: A preliminary report. *J Oral Maxillofac Surg.* 1986;44:516-9.
4. Abrahamsson P, Wälivaara D, Isaksson S, Andersson G. Periosteal expansion before local bone reconstruction using a new technique for measuring soft tissue profile stability: A clinical study. *J Oral Maxillofac Surg.* 2012;70:e521-30.
5. Lew D, Shroyer J, Unhold P. The use of tissue expanders in the correction of avulsive injuries of the mandible: Report of two cases. *J Oral Maxillofac Surg.* 1988;46:892-9.

Carlos Acosta Behrends^{a,*}
y Marisol Pérez Gasque Builla^b

^a Cirujano Oral y Maxilofacial e Implantólogo, Universidad Nacional Autónoma de México, México, D.F., México

^b Periodoncista e Implantóloga, Profesora de la Alta Especialidad en Implantología Oral Quirúrgica y Protésica de la Universidad Nacional Autónoma de México, México, D.F., México

* Autor para correspondencia.

Correos electrónicos: carloslacbeh@gmail.com,
carloslacbeh@hotmail.com (C. Acosta Behrends).
1130-0558/

© 2015 SECOM. Publicado por Elsevier España, S.L.U. Este es un artículo Open Access bajo la licencia CC BY-NC-ND (<http://creativecommons.org/licenses/by-nc-nd/4.0/>).

<http://dx.doi.org/10.1016/j.maxilo.2015.09.001>

Oral cysticercosis in the paediatric patient: Report of six cases



Cisticercosis oral en el paciente pediátrico: informe de seis casos

Introduction

Cysticercosis is a current public health problem related to the poor hygienic-environmental conditions. Developing countries have the highest incidence of this disease, and also countries where there are large amounts of immigrants, who are carriers of *Taenia solium*.^{1,2} In Mexico approximately 2% of autopsies performed in patients from public hospitals show evidence of cysticercosis.³ At present, it is estimated that at least 50 millions worldwide are carriers of cysticercosis, half of which are symptomatic, and that approximately 50-80% of them are at risk of die of this disease if they do not receive specialized attention.⁴

Poor health conditions and a lack of measures for health control are the predisposing factors for this disease. Cysticercosis is acquired by ingesting the *T. solium* eggs through the intake of contaminated water and food. The activated embryo penetrates the intestinal wall of the host until they reach lymphatic and blood capillaries, which in turn spread them through the circulatory system to several organs and tissues. It is estimated that after 10 weeks, the egg becomes a cysticercus and may survive for several years in the tissues of the intermediary host (human or pig).⁵ In human beings, cysticerci are mainly located in the central nervous system, producing neurocysticercosis, but it may also be located in a wide variety of tissues, including the muscles, heart, eyes, and skin.⁵ To the best of our knowledge, only 118 cases of oral cysticercosis have been reported up to date in

the international literature.⁵⁻¹⁰ Treatment of oral cysticercosis consists of surgical excision of the nodule. Histological examination confirms diagnosis. We present a series of 6 patients with this infection and underline the importance of searching for these parasites in other possible affected organs.

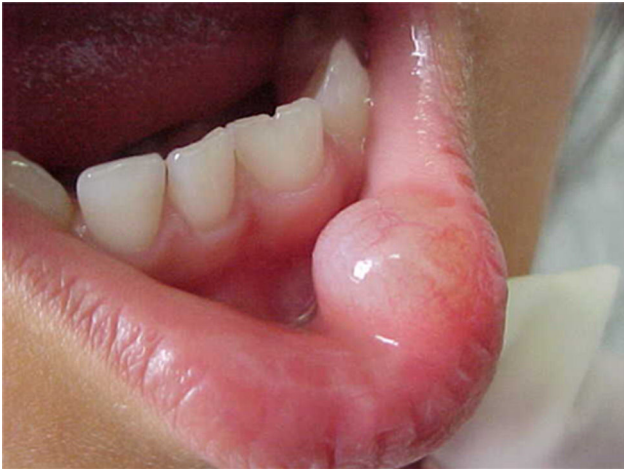Report of cases

Six cases of cysticercosis affecting the oral cavity are presented. They were diagnosed and treated in the Maxillofacial Surgery Department of the Instituto Nacional de Pediatría (Mexico City). The cases presented in this paper were treated from 1999 to 2013. **Table 1** shows a summary of the salient clinical features of the affected patients. There were three male and three female whose ages ranged from 1 to 8 and 5 to 14 years, respectively. All the lesions appeared as well defined, mobile and painless submucosal nodules (**Fig. 1**). Three were located in the dorsum of the tongue, 1 in the ventral surface of the tongue, 1 in the lower lip and 1 within the buccal mucosa. Diameter ranged from 0.5 cm to 2 cm. All the cases underwent surgical excision (**Figs. 2 and 3**). The presumptive clinical diagnoses of these lesions were salivary gland mucocele in 5 cases and lipoma in the other case.

Histologically, viable cysticerci were detected in two cases. These showed an external dense fibrous capsule that surrounded a delicate, double-layered membrane composed by an

Table 1 – Clinical findings in the present series of 6 cases of oral cysticercosis.

Case	Age	Sex	Location	Size (cm)	Clinical diagnosis
1	1 year	M	Right dorsum of tongue	1	Mucocele
2	6 years	M	Left dorsum of tongue	1	Mucocele
3	8 years	M	Lower lip mucosa	0.7	Mucocele
4	5 years	F	Right dorsum of tongue	1	Mucocele
5	7 years	F	Left ventral region of the tongue	0.5	Mucocele
6	14 years	F	Right cheek	2	Lipoma

**Figure 1 – Clinical appearance of an intraoral labial enlargement resembling a mucocele.**

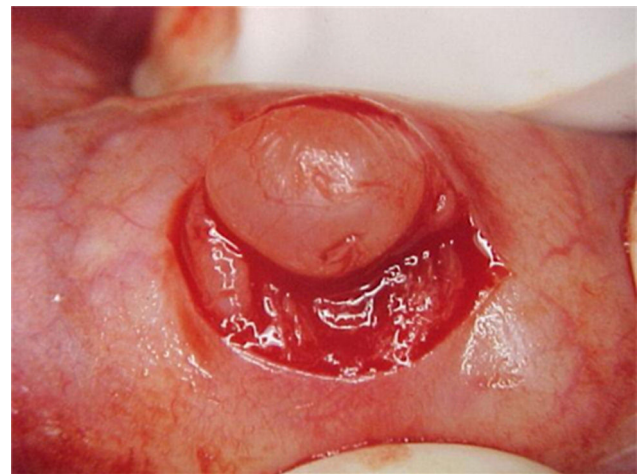
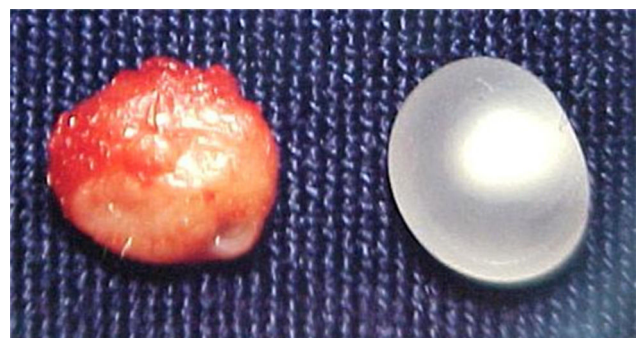
outer acellular eosinophilic layer and an inner, sparsely cellular lining. The outer part of the capsule contained a mild to moderate inflammatory cell infiltrate, in which lymphocytes, plasma cells and histiocytes predominated. On the inner aspect the inflammatory infiltrate exhibited aggregates of neutrophils and eosinophils, which were more abundant in the four cases of degenerated cysticerci. The cyst in all cases contained the larval form of *T. solium*, whose cephalic extremity (scolex) had a structure similar to that of the adult cestode, with distinct suckers and a crown of hookers (rostellum). Caudal to the scolex is the duct-like invagination segment consisting of a free duct with a digitiform coating lined by an histic membrane. The four cases with degenerative changes exhibited colloid degeneration of their structure and abundant granular mineralization (Fig. 4).

Discussion

Oral lesions due to cysticercosis are very rare, in spite of the high prevalence of neurocysticercosis worldwide. In the largest Latin-American study of oral cysticercosis reported by Delgado et al.,⁵ the most frequently affected site was the tongue, followed by the buccal mucosa, lower lip, and the upper lip. In that study there were 16 cases retrieved from Peru, Guatemala and Mexico; of these, there were only two pediatric patients, which coincides with the rest of the literature with respect to the fact that the number of pediatric patients is lower as compared to adults affected by this disease. According to our review of the English and Spanish literature, only 31 (25%) out of 124 cases reported to date that presented complete

information about age, gender and specific location (including the present series) have occurred in this age group.⁵⁻²⁵ Of these, 14 were males and 17 females. Age ranged from 1 to 12 years, with most cases (19) located on the tongue.

The differential diagnosis of oral cysticercosis depends on the location of the lesion. Nodules located on lips and cheeks may be misdiagnosed as mucocele, fibroma, lipoma, or a salivary gland adenoma, while the nodules located within the tongue may simulate fibroma, granular cell myoblastoma or a submucous mesenchymal tumor.^{5,6,10,12,13,14,17} In most cases pediatric oral cysticercosis has been misdiagnosed clinically as mucocele, as it happened in 5 out of the 6 cases included in the present series, with the exception of a case which showed a 2 cm lesion within the cheek, which was clinically diagnosed as lipoma. Mucocele rarely exceeds 1.5 cm in

**Figure 2 – Surgical excision of the lesión under local anesthesia. Safety margins were not necessary.****Figure 3 – Macroscopic view of the lesion and the capsule and surrounding tissue.**

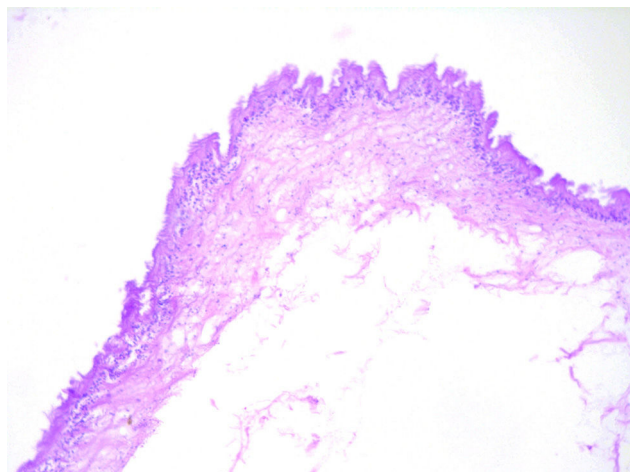


Figure 4 – Cysticercus eosinophilic lining surrounded by a thin collagenous capsule with scant lympho-histiocytic foci.

larger diameter, and the clinical presentation depends on its depth and the degree of keratinization of the covering mucosa. All these characteristics are similar to those described in our patients; however, cysticercosis has a firmer consistency as compared to mucocles and the lipomas; thus, this feature must suggest the possibility of a cysticercus. The importance of its recognition lies in that sometimes lesions clinically diagnosed as mucocles or other apparently benign lesions are surgically excised without histopathological confirmation of the diagnosis. Although cysticercosis has to be confirmed by histopathological examination, some authors suggest that the use of other diagnostic tools such as fine needle aspiration may be also useful. This method has demonstrated the identification of some parts of the parasite in a high percentage of the cases.^{11,20,26,27,28,29} Laboratory findings in patients with cysticercosis reveal that the Enzyme-Linked Immuno-Sorbent Assay (ELISA) is positive to *Cysticercus cellulosae*.⁵

Treatment of oral cysticerci is based on symptoms and depends on the affected anatomical zone. Praziquantel and Albendazole are potent anthelmintic drugs used in the treatment of cysticercosis, replacing Niclosamide, which was the drug of choice for the treatment of the disease for a long period. Drugs should be used especially in cases where surgical treatment is risky or impossible, as in neurocysticercosis. Treatment may be unnecessary in asymptomatic individuals, but most cases are treated when the lesion is clearly evident, interferes with function or if it is traumatized. In the oral tissues, treatment of choice is surgical excision of the lesion as well as to perform a detailed study in each case in order to exclude the presence of the tapeworm in other sites.^{5,8,20} The six pediatric patients we presented with cysticercosis in oral cavity were asymptomatic, with well defined lesions, mobile, painless and firm in consistency. Such lesions were completely removed without complications, because the surgical site was easily accessible.

This infection could cause neurocysticercosis, which in turn predisposes to cancer, gliomas, astrocytomas and oligodendrogliomas.³⁰⁻³²

Conclusions

We can state that it is important to consider the diagnosis of cysticercosis in oral solitary nodular lesions presenting in patients living in endemic areas, since we know that Mexico has a great deal of cases with this disease in other regions of the body. This paper emphasizes the role of the dentist in the detection of a disease that can have more serious involvement, as well as the importance of routine histological examination of every lesion excised from the oral cavity.

Ethical disclosures

Protection of human and animal subjects. The authors declare that the procedures followed were in accordance with the regulations of the relevant clinical research ethics committee and with those of the Code of Ethics of the World Medical Association (Declaration of Helsinki).

Confidentiality of data. The authors declare that they have followed the protocols of their work center on the publication of patient data.

Right to privacy and informed consent. The authors have obtained the written informed consent of the patients or subjects mentioned in the article. The corresponding author is in possession of this document.

Source of funding

None declared.

Conflict of interest

The authors declare no conflict of interest.

BIBLIOGRAFÍA

1. Flisser A. Neurocysticercosis in Mexico. *Parasitol Today*. 1988;4:131-7.
2. Nash TE, Neva FA. Recent advances in the diagnosis and treatment of cerebral cysticercosis. *N Engl J Med*. 1984;311:1492-6.
3. Larralde C, Padilla A, Hernandez M, Govezensky T, Sciotto E, Gutiérrez G, et al. Seroepidemiología de la cisticercosis en México. *Salud Publica Mex*. 1992;34:197-210.
4. Kraft R. Cysticercosis: an emerging parasitic disease. *Am Fam Physician*. 2007;76:91-6.
5. Delgado-Azañero WA, Mosqueda-Taylor A, Carlos-Bregni R, Del Muro-Delgado R, Díaz-Franco MA, Contreras-Vidaurre E. Oral cysticercosis: a collaborative study of 16 cases. *Oral Surg Oral Med Oral Pathol Oral Radiol Endod*. 2007;103:528-33.
6. Lee KH, Cepeda L, Miller M, Siegel DM. Mucocles not – oral cysticercosis and minor salivary gland adenocarcinoma: two case reports. *Dermatol Online J*. 2009;15:8.
7. Aggarwal S, Wadhwa N. Swelling on the tongue: a rare presentation of oral cysticercosis. *Diagn Cytopathol*. 2009;37:236-7.

8. Subramanian B, Krishnaraj S, Agrawal K, Soundararagavan J. Cysticercosis of the oral cavity: an often misdiagnosed entity. *J Laryngol Otol.* 2008;122:1005-7.
 9. Jay A, Dhanda J, Chiodini PL, Woodrow CJ, Farthing PM, Evans J, et al. Oral cysticercosis. *Br J Oral Maxillofac Surg.* 2007;45:331-4.
 10. Ribeiro AC, Luvizotto MC, Soubhia AM, de Castro AL. Oral cysticercosis: case report. *Oral Surg Oral Med Oral Pathol Oral Radiol Endod.* 2007;104:e56-8.
 11. Mazhari NJ, Kumar N, Jain S. Cysticercosis of the oral mucosa: aspiration cytologic diagnosis. *J Oral Pathol Med.* 2001;30:187-9.
 12. Rao PLNG, Radhakrishna K, Kapadia RD. Cysticercosis of the tongue. *Int J Pediatr Otorhinolaryngol.* 1990;20:159-61.
 13. de Souza PEA, Barreto DC, Fonseca LM, de Paula AM, Silva EC, Gomez RS. Cysticercosis of the oral cavity: report of seven cases. *Oral Dis.* 2000;6:253-5.
 14. Romero de León E, Aguirre A. Oral cysticercosis. *Oral Surg Oral Med Oral Pathol Oral Radiol Endod.* 1995;79:572-7.
 15. Timosca G, Gavrilita L. Cysticercosis of the maxillofacial region: a clinicopathologic study of five cases. *Oral Surg Oral Med Oral Pathol.* 1974;37:390-400.
 16. Ostrofsky MK, Baker MA. Oral cysticercosis: three case reports. *J Dent Assoc S Afr.* 1975;30:535-7.
 17. Lustmann J, Copelyn M. Oral cysticercosis: review of the literature and report of two cases. *Int J Oral Surg.* 1981;10:371-5.
 18. Hansen LS, Allard RHB. Encysted parasitic larvae in the mouth. *J Am Dent Assoc.* 1984;108:632-6.
 19. Navarrete F, Vázquez-Fritz C, Cedillo S, Portilla J. Cisticercosis lingual. *Bol Med Hosp Infant.* 1974;31:101-4.
 20. Saran RK, Rattan V, Rajwanshi A, Nijkawan R, Gupta SK. Cysticercosis of the oral cavity: report of five cases and a review of the literature. *Int J Paediatr Dent.* 1998;8:273-8.
 21. Webb DJ, Seidel J, Correll RW. Multiple nodules on the tongue of a patient with seizures. *J Am Dent Assoc.* 1986;112:701-2.
 22. Mahindra S, Daljit R, Sohail MA, Maheshwari HB. Cysticercosis in the practice of otolaryngology. *Acta Otolaryngol.* 1981;92:189-91.
 23. Sooknundun M, Kacker SK, Kapilla K. Cysticercosis of the oral cavity – a clinicopathological study of ten and a half years. *J Indian Dent Assoc.* 1986;58:257-9.
 24. Puppin D Jr, Cavegn BM, Delmaestro D. Subcutaneous cysticercosis of the tongue mimicking a tumor. *Int J Dermatol.* 1993;32:818-9.
 25. Gupta SC, Gupta SC. Cysticercosis of the tongue. *Ear Nose Throat J.* 1995;74:174-8.
 26. Handa U, Garg S, Mohan H. Fine needle aspiration in the diagnosis of subcutaneous cysticercosis. *Diagn Cytopathol.* 2008;36:183-7.
 27. Verma K, Kapila K. Fine needle aspiration diagnosis of cysticercosis in soft tissue swellings. *Acta Cytol.* 1989;33:663-6.
 28. Mittal A, Das A, Iyer N, Nagaraj J, Gupta M. Masseter cysticercosis – a rare case diagnosed on ultrasound. *Dentomaxillofac Radiol.* 2008;37:113-6.
 29. Sidhu R, Nada R, Palta A, Mohan H, Suri S. Maxillofacial cysticercosis: uncommon appearance of a common disease. *J Ultrasound Med.* 2002;21:199-202.
 30. Del Brutto OH, Castillo PR, Mena IX, Freire AX. Neurocysticercosis among patients with cerebral gliomas. *Arch Neurol.* 1997;54:1125-8.
 31. Herrera LA, Benita-Bordes A, Sotelo J, Chavez L, Olvera J, Rascon A, et al. Possible relationship between neurocysticercosis and hematological malignancies. *Arch Med Res.* 1999;30:154-8.
 32. Del Brutto OH, Dolezal M, Castillo PR, García HH. Neurocysticercosis and oncogenesis. *Arch Med Res.* 2000;31:151-5.
- Rubi López Fernández^{a,*}, Jorge Téllez Rodríguez^a, Daniel Carrasco-Daza^{a,†}, Julio Sotelo-Morales^b, Adalberto Mosqueda-Taylor^c
- ^a Instituto Nacional de Pediatría, Cirugía Maxilofacial, departamento de Estomatología, México, DF, Mexico
^b Instituto Nacional de Neurología y Neurocirugía, Servicio de Neurología, México, DF, Mexico
^c Departamento de Atención a la Salud, Universidad Autónoma Metropolitana Xochimilco, México, DF Mexico
- * Corresponding author.
 E-mail address: dra_rubylopez@yahoo.com.mx (R.L. Fernández).
[†] Fallecido
 1130-0558/
 © 2015 SECOM. Published by Elsevier España, S.L.U. This is an open access article under the CC BY-NC-ND license (<http://creativecommons.org/licenses/by-nc-nd/4.0/>).
<http://dx.doi.org/10.1016/j.maxilo.2015.04.010>