



Caso clínico

Painful traumatic trigeminal neuropathy. Diagnosis and treatment: about two clinical cases

Christian Droguett Tidy^{1*}, Jorge Lolas Millard² y Constanza Labbé Martínez²

¹Department of Oral and Maxillofacial Surgery. Hospital del Trabajador. Oral and Maxillofacial Surgeon. Specialist in Pain Management. Faculty of Medicine. Universidad de Chile. Santiago, Chile. ²Department of Oral and Maxillofacial Surgery, Universidad de los Andes, Santiago, Chile

ARTICLE INFORMATION

Article history:

Received: 17 de noviembre de 2020

Accepted: 27 de marzo de 2021

Keywords:

Neuropathic pain, traumatic painful trigeminal neuropathy, maxillofacial trauma.

A B S T R A C T

Neuropathic pain is originated as a direct consequence of an injury or disease that affects the somatosensory system, which is a chronic, debilitating condition that affects a significant number of patients. The causes of neuropathic pain are diverse, and trauma is one of them. In this article the Painful Traumatic Trigeminal Neuropathy (PTTN) is reviewed. Two clinical cases are presented. The first is a 43-year-old female with PTTN, who was diagnosed nine months after reduction and osteosynthesis of a left zygomaticomaxillary fracture. The second case corresponds to a 62-year-old male who presented with a left suborbital PTTN also after a zygomaticomaxillary fracture and its reduction and osteosynthesis surgery. In the first case, the patient achieved a 70 % of reduction in pain after 6 months of treatment using multimodal analgesia with pregabalin, carbamazepine and amitriptyline. The second patient achieved complete resolution of pain with multimodal therapy using carbamazepine, amitriptyline, and lidocaine patches after two months of treatment. Therapy through multimodal analgesic scheme provides a favorable prognosis, however achieving a total resolution of the patient's pain is a difficult objective to achieve, and a significant reduction of 30% or more in the patient's VAS is considered a success of the effectiveness of the therapy.

Neuropatía trigeminal traumática dolorosa. Diagnóstico y tratamiento: a propósito de dos casos

R E S U M E N

El dolor neuropático es originado como consecuencia directa de una lesión o enfermedad que afecta al sistema somatosensorial, lo cual es una condición crónica, debilitante, que afecta a un número significativo de pacientes. Las causas de dolor neuropático son diversas y el trauma es

Palabras clave:

Dolor neuropático, neuropatía trigeminal traumática dolorosa, trauma maxilofacial.

*Correspondence:

E-mail: drcdroguett@gmail.com (Christian Droguett Tidy).

DOI: [10.20986/recom.2021.1226/2020](https://doi.org/10.20986/recom.2021.1226/2020)

1130-0558/© 2021 SECOM CyC. Publicado por Inspira Network. Este es un artículo Open Access bajo la licencia CC BY-NC-ND (<http://creativecommons.org/licenses/by-nc-nd/4.0/>).

una de ellas. En este artículo se revisa la neuropatía trigeminal traumática dolorosa (PTTN). Se presentan dos casos clínicos. La primera es una mujer de 43 años con PTTN que fue diagnosticada nueve meses después de la reducción y osteosíntesis de una fractura cigomatomaxilar izquierda. El segundo caso corresponde a un varón de 62 años que consultó con una PTTN suborbitaria izquierda también tras una fractura cigomatomaxilar y su cirugía de reducción y osteosíntesis. En el primer caso clínico la paciente logró una reducción de un 70 % de su sintomatología a los 6 meses de tratamiento mediante terapia farmacológica multimodal con pregabalina, carbamazepina y amitriptilina. El segundo paciente logró una resolución completa del dolor con carbamazepina, amitriptilina y parches de lidocaína, después de 2 meses. La terapia mediante esquema analgésico multimodal proporciona un pronóstico favorable, sin embargo, lograr una resolución total del dolor del paciente es un objetivo difícil de lograr, y una reducción significativa del 30 % o más en la EVA del paciente se considera un éxito de la efectividad de la terapia.

INTRODUCTION

Neuropathic pain can be caused by damage produced at any point in the nociceptive pathway, from the nociceptors to the cortical neurons of the brain¹. Depending on the location of the damage, neuropathic pain can be classified as central or peripheral; according to its distribution as localized or diffuse; According to its etiology, it is classified as metabolic, secondary to ischemia, secondary to inflammation, paraneoplastic, neurodegenerative or traumatic^{2,3}.

Painful Traumatic Trigeminal Neuropathy (PTTN) occurs in 3.3 % of patients with trigeminal nerve injury. In patients with fractures of the zygomatic-maxillary complex, anesthesia or hypoesthesia is frequently observed at examination of territory corresponding to the innervation of infraorbital nerve. However, the development of persistent neuropathic pain occurs only in 3.3 % of cases^{1,2}.

Injury to a nerve delivers negative symptoms in an early stage such as anesthesia, hypoesthesia, or hypoalgesia. Later, it presents positive symptoms such as formication paresthesia, which corresponds to abnormal activity of Ab fibers, and pain. The latter can be spontaneous or provoked, which can be of a burning nature, which suggests discharges of type C nociceptors, or lancinating, which suggests ectopic discharges originating in the axon of the A delta fiber^{1,3}.

PTTN, unlike essential trigeminal neuralgia, usually presents as a persistent pain although it may have paroxysmal attacks on a painful basis; it is normally of a burning nature, although it may also have a lancinating component, and reaches a moderate to severe intensity³. Patients usually complain of swelling, heat or cold, and erythema in the area that hurts^{4,5}. It shares other characteristic of all neuropathic pain, such as having a strict distribution to the affected dermatome and presenting allodynia and/or hyperalgesia.

According to the International Headache Society there are the following diagnostic criteria for PTTN:

1. Unilateral facial and/or oral pain that meets criterion 3.
2. History of identifiable trauma to the trigeminal nerve, with positive and/or negative clinical signs, these evidences of trigeminal nerve dysfunction.
3. Causality is demonstrated by the following two criteria:
 - a) The pain follows the same distribution of the affected trigeminal nerve branch.

- b) The pain occurs between the third and sixth month after the trauma.

4. Absence of explanation for another diagnosis⁶.

The management of neuropathic pain should be early and multimodal in nature, considering all therapeutic alternatives, both pharmacological and non-pharmacological⁷.

The management of PTTN generally follows the recommendations for peripheral neuropathic pain, where membrane stabilizers and tricyclic antidepressants are the main drugs⁸ (Tables II, III and III).

A small number of patients may have very little or no response to pharmacological treatment and neurosurgical procedures appear as an alternative to this group of patients. These include radiofrequency rhizotomy, stereotaxic radiosurgery, open section of trigeminal nerve roots, and deep cerebral or cortical electrostimulation, but reports have shown disparate results for different conditions of neuropathic and non-neuropathic pain of the face⁹.

CASE REPORTS

First case of a 43-year-old female (Figure 1.A) patient with a left zygomatic fracture, for which she underwent surgery for reduction and osteosynthesis. Nine months later, the patient consulted for pain assessed according to the *visual-analog-scale* (VAS) as 8 on the left side of the face, which described it as lancinating in the skin of the left genial region and the left side of the upper lip. At the touch of the area she reported 10 in VAS, and hypoesthesia of the left suborbital skin, left side of the upper dentoalveolar region. The finding of mechanical allodynia manifested by touch of the innervation territory corresponding to the left infraorbital nerve was evident.

The postoperative control image (Figure 1.B) showed a single osteosynthesis plate located in the zygomaticoalveolar-buttes on the same side. Was diagnosed as a PTTN that affected the left suborbital nerve. With this, treatment with pregabalin was started with an initial dose of 75mg/day, after two weeks has had decrease in the severity of pain of 2 points in VAS was achieved, the dose was increased to 75 mg every 12 hours and carbamazepine 200mg per day was added to take as a single intake at the end of the day. After one month, the patient experienced pain relief that reached 50 % reduction in the value of VAS. Five months later a pain relief of 50 %

Table I. First-line drugs for the treatment of PTTN in the maxillofacial territory.

First-line of treatment	Subclass	Mechanism of action	Recommended drug	Use in neuropathic pain	Dosage in PTTN
Anticonvulsivants	GABA derivatives	Membrane stabilizers decreasing excitatory transmission over $\alpha 2d$ Subunit of Ca^{+2} Channel Voltage Dependent	Gabapentin	Relief allodynia, hyperalgesia, burning, lancinating pain	1800 to 3600 mg/day (3 doses) Initial dose: 600 - 800mg every 8 hours Start of action: 2 weeks Maximum effect: 2 weeks post therapeutic dose Toxicity: drowsiness, dizziness, ataxia Interactions: Minimal
			Pregabalin	Same effects as gabapentin in neuropathic pain. Adds anxiety effect Immediate analgesia	300 to 600 mg/day (2 or 3 doses) Initial dose: 75 to 150 mg/day Start of action: 2 weeks Maximum effect: 2 weeks post therapeutic dose Toxicity: drowsiness, dizziness, ataxia Interactions: Minimal
Antidepressants	Tricyclic Antidepressants	Mixed and variable blocking Monoaminergic effect: Inhibition of serotonin and norepinephrine reuptake in synapses of the nociceptive pathway Glutamaergic effect: Alters glutamate binding to NMDA receptors Indirect effect on opioid receptors through monoaminergic neurons and inhibition of adenosine reuptake at synapses	Amitriptylin	Relief of chronic pain by central and peripheral mechanisms Treatment of neuropathic pain requires lower doses than antidepressant treatment. Sedative effect Effective in the relief of post-herpetic neuralgia and painful neuropathy secondary to diabetes. 13. Less effective action in neuropathy due to HIV and spinal cord injury 16o and neuropathic pain due to cancer	12.5 to 75 mg/day (1 dose per day) Starting dose: 12.5 to 25 mg/day Adjust 1 time a month Onset of action: 2 weeks Maximum effect: 4 weeks Toxicity: Anticholinergic effects (dry mouth, constipation, urinary retention), blocking effects, sedation, weight gain, arrhythmias and seizures before overdose Interactions: CYP inducers and inhibitors
Local anesthetics	Amides	Na^{+2} channel block in action potential Slows down and blocks action potential from peripheral afferents	Lidocaine	Topic lidocaine: relief of allodynia and postherpetic neuralgia Useful in initial treatment until reaching effective dose of multimodal analgesic treatment	Patches 5 % (700 mg in aqueous adhesive base) 1 patch every 12 to 24 hours Toxicity: Minimal, mild skin reactions Low plasma levels Interactions: Class I antiarrhythmics, Hepatic metabolism

Table II. Second-line drugs for the treatment of PTTN in the maxillofacial territory.

Second-line of treatment	Subclass	Mechanism of action	Recommended drug	Use in neuropathic pain	Dosage in PTTN
Antidepressants	Selective serotonin-noradrenaline reuptake inhibitors (SNRIs)	Moderately selective blocking of serotonin and norepinephrine	Duloxetine	Chronic pain relief Fibromyalgia treatment Second line for neuropathic pain management Greater tolerance than tricyclic antidepressants (they lack antihistamine, alpha adrenergic blocker and anticholinergic effects)	Duloxetine: 30 mg/day first week until reaching 60 mg/day Venlafaxine: 75 to 225 mg/day Start 37.5 mg/day first week until reaching 75 mg/day Onset of action: 2-4 weeks Maximum effect: 4 weeks Toxicity: Anticholinergic effects, risk of glaucoma and liver failure (duloxetine), sedation, hypertension (venlafaxine) Interactions: some inhibition of CYP 2D6 (Duloxetine, desvenlafaxine)
			Venlafaxine	Adjuvant opioid in chronic pain syndromes Medication for moderate pain Adjuvant for immediate pain relief in multimodal treatment of pain of first line Effect in neuropathic pain, polyneuropathies, postherpetic neuralgia and neuropathic pain due to mellitus diabetes Must be supplemented with antiemetic medication in case of nausea	50 to 400 mg/day (3 doses) Starting dose: 50-100 mg/day Toxicity: Seizures, dizziness, constipation, nausea, vomiting, risk of serotonin syndrome Risk of abuse, twenty Interactions: Risk of serotonin syndrome
Opioids	Weak agonist opioid (μ)	Mixed effect: Weak μ agonist, moderate serotonin reuptake inhibitor and weak norepinephrine transporter inhibitor	Tramadol	Intense pain Adjunct in general anesthesia and sedation (fentanyl, remifentanyl, morphine) Pulmonary edema (morphine only) Maintenance in programs rehabilitation (methadone only) In chronic neuropathic pain, a weak μ agonist is preferable	Titiable dose according to case Immediate effect Some available in long-lasting transdermal patches. Duration: 1-4 h except methadone, 4-6 h Toxicity: respiratory depression, severe constipation, addiction liability, seizures, urinary retention, nausea/vomiting, delirium Interactions: Sedative hypnotics (respiratory depression), Antipsychotic agents (increased sedation and cardiovascular effects), monoamine oxidase inhibitors (hyperpyrexia coma and arterial hypertension)
			Morphine Methadone Fentanyl	Strong agonists of μ receptor, affinity variable by δ and κ receptors	

Table III. Third-line drugs for the treatment of PTTN in the maxillofacial territory.

Third-line of treatment	Subclass	Mechanism of action	Recommended drug	Use in neuropathic pain	Dosage in PTTN
Anticonvulsants	Na ⁺ channel blockers	Na ⁺ channel blockers and inhibition of glutamate release by neurons of the central nervous system. twenty Rapid oral absorption, maximum levels in 4-5 hours	Carbamazepine	Use in tonic-clonic crisis focal and focal bilateral, use in neuropathic pain. First level of evidence for essential trigeminal neuralgia, but its efficacy for PTTN is disputed with limited results in some studies	800-1200 mg/day; the maximum dose Gradual increase For neuropathic pain 100 to 200mg every 12 hours is recommended Toxicity: nausea, diplopia, ataxia, hyponatremia, headache Interactions: phenytoin, valproic acid, fluoxetine, verapamil, antibiotics macrolides, isoniazid, propoxyphene, danazol, phenobarbital, primidone, among others
			Oxcarbazepine	Similar effects and mechanism of action as carbamazepine.	300 mg/day to 600mg every 12 hours The clinical dose of oxcarbazepine may need to be 50 % higher than that of carbamazepine. Fewer interactions reported
			Lamotrigine	Use in focal seizures, generalized tonic-clonic seizures, absence seizures, other generalized seizures; depression Bipolar. Its effectiveness in controlled trials was poor and its potential skin toxicity gives it a third level of Choice for the management of neuropathic pain	100 to 300 mg/day Initial dose is 25 mg/day, and increases to 50 mg/day after 2 weeks; subsequently, the degree can advance by 50 mg/day every 1-2 weeks up to a regular maintenance dose 225-375 mg / d (in two divided doses) In patients receiving valproate, the starting dose of lamotrigine should be reduced to 12.5-25 mg every other day, with increases of 25-50 mg/day every 2 weeks as needed at a usual maintenance dose of 100-200 mg/day Toxicity: dizziness, headache, diplopia, rash Interactions: valproic acid, carbamazepine, oxcarbazepine, phenytoin, phenobarbital, primidone, succinimides, sertraline, topiramate
	Spread spectrum	Unknown mechanism	Valproic acid	Use tonic-clonic seizures widespread crisis partial, absence seizures, myoclonic seizures, other generalized seizures; migraine prophylaxis Its mechanism of action is still unknown. No greater effectiveness than placebo has been found in some poor quality studies	15 mg/kg with one titration slow until therapeutic dose. Doses of 25-30 mg/kg/d Toxicity: nausea, tremor, weight gain, loss of hair, teratogenic, hepatotoxic Interactions: phenobarbital, phenytoin, carbamazepine, lamotrigine, felbamate, rifampin, ethosuximide, primidone
	Topiramate	Multiple action	Topiramate	Focal crisis, crisis generalized primaries, Lennox syndrome-Gastaut; prophylaxis of migraine	100 mg/day Initial dose 25-50 mg / day and gradual increase Toxicity: drowsiness, cognitive slowing confusion, paresthesias Interactions: phenytoin, carbamazepine, contraceptives oral, lamotrigine, lithium

(Continue in the next page)

Table III (Cont.). Third-line drugs for the treatment of PTTN in the maxillofacial territory.

Third-line of treatment	Subclass	Mechanism of action	Recommended drug	Use in neuropathic pain	Dosage in PTTN
	Selective serotonin reuptake inhibitors (SSRIs)	Highly selective blocking of the serotonin transporter little effect on the norepinephrine transporter. Acute increase in serotonergic synaptic activity slower changes in various signaling pathways and neurotrophic activity	Paroxetine Citalopram	Major depression, anxiety disorders • panic disorder • obsessive-compulsive disorder • disorder posttraumatic stress • vasomotor symptoms perimenopausal • eating disorder Third-line use in neuropathic pain	Variable dose Toxicity: sexual dysfunction, risk of serotonin syndrome with iMAO Interactions: some inhibition of CYPs (fluoxetine 2D6, 3A4, fluvoxamine 1A2, paroxetine 2D6)
Antidepressants	Tetracyclic, monocyclic	Increased activity of norepinephrine and dopamine (bupropion) • NET> SSRI inhibition (amoxapine, maprotiline) Increased release of norepinephrine, 5-HT (mirtazapine) Presynaptic release of catecholamines, but no effect on 5-HT (bupropion) • the Amoxapine and Maprotiline resemble tricyclics Interaction with the vanilloid receptor VR1 of type C sensory fibers activate the vanilloid receptors of the skin and generate their you see pain, stinging and later analgesia This receptor is a non-selective cation channel, with a high permeability for calcium ⁴² Promotes the release and inhibits the biosynthesis and axonal transport of substance P, which leads to a depletion of substance P in the central and peripheral nervous system produces reversible desensitization of C-fiber sensory endings. It can cause a degeneration of the nerve fibers of the epidermis.	Bupropion	Third line use	Variable dose Extensive liver metabolism. Toxicity: lowers the seizure threshold (amoxapine, bupropion). Interactions: CYP2D6 inhibitor
Other	Neurotoxins (Capsaicin)		Capsaicin	There is moderate-quality evidence that high-concentration (8 %) capsaicin patches can provide moderate pain relief, or better, to a minority of patients with postherpetic neuralgia, and very low-quality evidence that they benefit patients with HIV neuralgia and diabetic peripheral neuropathy Third line of treatment in neuropathic pain management	Topical: 0.025-0.075 %, application every 6 to 8 hours in the affected area. 8 % high concentration patches. In 80 % of cases, there may be a burning or stinging sensation in the area of application, irritative erythema, dry skin

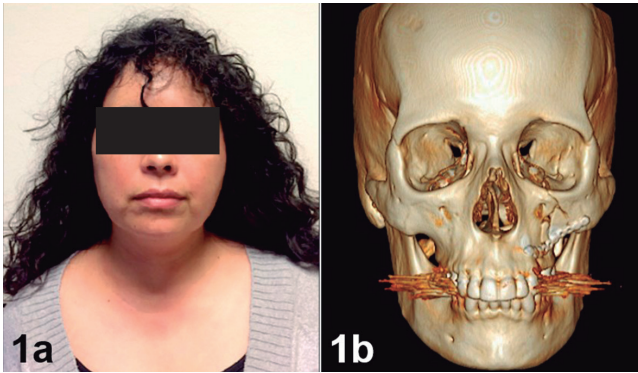


Figure 1. Case 1. A. 43-year-old female patient with a left maxillary-zygomatic fracture. B. Postoperative control CT-3D reconstruction.

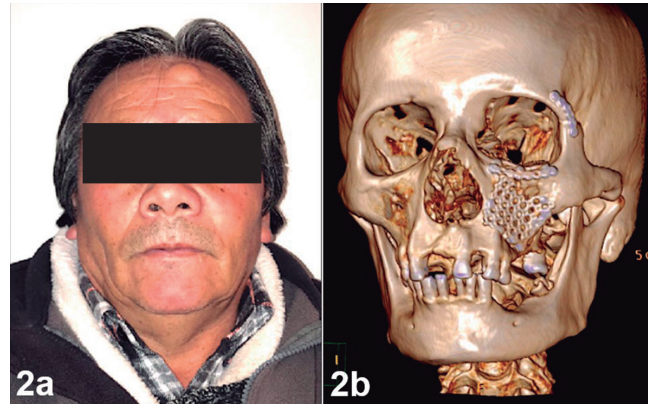


Figure 2. Case 2. A. 62-year-old male patient with a left side maxillary-zygomatic fracture. B. CT-3D reconstruction showing an operated left side zygomaticomaxillary fracture.

was maintained but had isolated episodes of increased pain severity which maintained its characteristics. It was decided to add amitriptyline in doses of 12.5 mg per day. At the seventh month after the start of the therapy, the patient reported relief of the severity of the pain giving a 2 in VAS, which meant an improvement of 70 %.

The second clinical case corresponds to a 62-year-old male patient (Figure 2.A), who suffered an accident which resulted in a left side maxillary-zygoma fracture. He underwent surgery in another maxillofacial-surgery service, and three months later he began with a persistent lancinating sub-eyelid pain on the same side as the fracture, which reached a 5 in VAS and reached 9 with touch of the area or with movements of facial mimic muscles. Also had anesthesia in the same area of the pain that was present since the accident. On examination, the patient had allodynia to the touch of the left sub-palpebral territory, left nasal wing, and anterior area on the left side of the maxilla.

The CT scan (Figure 2.B) showed an operated left side zygomaticomaxillary fracture, with osteosynthesis installed in the left frontozygomatic suture, infraorbital rim, zygomaticomaxillary buttress and a mesh that covered the left infraorbital hole.

Given the described disposition of the mesh, it made suspect a possible compression of the suborbital nerve, so it was decided to remove it. At the surgery, the compression exerted on the affected nerve was verified. The patient was treated with pregabalin at a dose of 75 mg every 12 hours and lidocaine patches to be used 1 every 24 hours in the affected territory. One month after starting this treatment, the patient evolved favorably, reporting a VAS assessment of 4. Considering it still compromised the quality of life of the patient, amitriptyline was added in a single daily dose of 25 mg/day, after which, evolving favorably after one month reporting complete pain relief, assessing it according to VAS as 0.

DISCUSSION

The low incidence of neuropathic pain in these cases has been explained because of the trigeminal nerve experiencing markedly lower ectopic discharges compared to other

peripheral nerves¹⁰. As pathophysiological considerations for neuropathic pain in the cases described, we can explain its occurrence through the formation of a neuroma or areas of demyelination in the suborbital nerve, given the bone displacement caused by the fracture.

We could argue that the best treatment is the prevention of neuropathic sequelae after trauma. This means that the indication for surgery should be considered promptly after having suffered the accident in maxillofacial fractures that compromise any branch of the trigeminal nerve, which at first will manifest with a negative neurological clinical sign (anesthesia, hypoesthesia or hypoalgesia), although the bone displacement is less, trying to achieve an anatomical reduction. This gives a favorable anatomical territory to allow or provide an opportunity for a repair of the affected nervous trunk to occur, thus avoiding areas of demyelination or the formation of a neuroma.

The treatment of this condition must be done with drugs of first line or in combination with others of second or third line, always considering the strategy of *multimodal analgesia* because of its effectiveness in pain control with lower incidence of side effects. The consequences in the quality of life of the patients who suffer PTTN can be devastating, given this, it's essential that the maxillofacial surgery teams be trained in the diagnosis and treatment of this type of condition, in order to achieve timely and effective treatment.

REFERENCES

1. Baad-Hansen L, Benoliel R. Neuropathic orofacial pain: Facts and fiction. *Cephalalgia*. 2017;37(7):670-9. DOI: 10.1177/0333102417706310.
2. Peñarrocha MA, Peñarrocha D, Bagán JV, Peñarrocha M. Post-traumatic trigeminal neuropathy. A study of 63 cases. *Med Oral Patol Oral Cir Bucal*. 2012;17(2):297-300. DOI: 10.4317/medoral.17401.
3. Haviv Y, Zadik Y, Sharav Y, Benoliel R. Painful traumatic trigeminal neuropathy: an open study on the pharmacotherapeutic response to stepped treatment. *J Oral Facial Pain Headache*. 2014;28(1):52-60. DOI: 10.11607/jop.1154.

4. Correa-Illanes Gerardo. Neuropathic pain, classification and management for general practitioners. *Rev. Medica Clínica las Condes*. 2014;25(2):189-99. DOI: 10.1016/S0716-8640(14)70030-6.
5. Zakrzewska JM. Multi-dimensionality of chronic pain of the oral cavity and face. *J Headache Pain*. 2013;14(1):37. DOI: 10.1186/1129-2377-14-37.
6. Fernández R, Ahumada M, Muñoz R, Urra X, Yáñez MV, Velasco M, et al. Guidelines for Definition and Management of Localized Neuropathic Pain (LNP): Chilean Consensus. *Revista El Dolor*. 2011;20(55):12-31.
7. Attal N, Cruccu G, Baron R, Haanpää M, Hansson P, Jensen TS, et al. EFNS guidelines on the pharmacological treatment of neuropathic pain: 2010 revision. *Eur J Neurol*. 2010;17(9):1113-e88. DOI: 10.1111/j.1468-1331.2010.02999.x.
8. Haanpää M, Attal N, Backonja M, Baron R, Bennett M, Bouhassira D, et al. NeuPSIG guidelines on neuropathic pain assessment. *Pain*. 2011;152(1):14-27. DOI: 10.1016/j.pain.2010.07.031.
9. Broggi G, Franzini A, Leone M, Bussone G. Update on neurosurgical treatment of chronic trigeminal autonomic cephalalgias and atypical facial pain with deep brain stimulation of posterior hypothalamus: results and comments. *Neurol Sci*. 2007;28(Suppl. 2):138-45. DOI: 10.1007/s10072-007-0767-3
10. Benoliel R, Zadik Y, Eliav E, Sharav Y. Peripheral painful traumatic trigeminal neuropathy: clinical features in 91 cases and proposal of novel diagnostic criteria. *J Orofac Pain*. 2012;26(1):49-58.