

## Editorial

# Brief considerations about temporomandibular joint internal derangement in the patient with dentofacial deformity

In the last IV National Conference of Temporomandibular Joint (TMJ), held in Madrid on November 7 and 8, 2019, the pathology of TMJ in patients with dentofacial deformities was discussed. Attendees had the opportunity to attend the presentations of prestigious national and international speakers, experts in this field, and were able to deepen the different treatment options of that patient who undergoes orthognathic surgery and suffers, concomitantly, joint pathology. This Editorial exposes some brief considerations on this aspect.

The primary treatment of TMJ dysfunction has the following objectives: 1) to relieve symptoms; 2) to stop the normal progression of the disease; and 3) to restore the normal function of the TMJ. Placing the disc in its normal anatomical position is considered controversial, as there is not yet sufficient scientific evidence. From an anatomical point of view, TMJ dysfunction –also called TMJ internal derangement– is considered the abnormal relationship of the articular disc with respect to the mandibular condyle, the joint eminence and the glenoid fossa of the temporal bone. However, some studies support the non-complete correlation between pathology and disc position: Kircos et al.<sup>1</sup> reported that 34% of asymptomatic volunteers had disc displacement, while, in a complementary way, Tallents et al.<sup>2</sup> observed that the disc maintained its normal position in 16-23% of the patients (symptomatic subjects).

Recurrence after mandibular sagittal osteotomy may occur due to condylar malposition, loss of fixation and condylar resorption. Condylar resorption is a slow process that appears late and may be associated with joint symptoms; It usually occurs in patients with class II dentoskeletal deformity undergoing mandibular advancement with counterclockwise rotation, having also been associated with the existence of an anterior open bite, posterior cross bite and extreme maxillary overjet. Jung et al.,<sup>3</sup> in a retrospective study of 460 patients treated by orthognathic surgery, evaluated the position of the articular disc before and after surgery using nuclear magnetic resonance imaging (MRI). They concluded that the severity of disc displacement increased progressively from class III to class II deformities in the sagittal plane, and from hypodivergent to hyperdivergent deformities in the vertical plane, indicating an association between class II dentoskeletal deformity and/or hyperdivergent deformity and the presence of disc displacement, being difficult to determine if the first is a consequence of the second, or viceversa.

There is some controversy regarding the influence of TMJ status in patients undergoing orthognathic surgery. Dujoncquoy et al.,<sup>4</sup> in a retrospective study based on a survey of 57 patients, concluded that patients with TMJ dysfunction who undergo orthognathic surgery improve their signs (74% for clicks, 27% for joint blockage) and symptoms (44% for pain) significantly. However, they also observed that orthognathic surgery can cause pain (24%), joint click (25%) and joint lock (17%) in previously asymptomatic patients. The systematic review of Te Veldhuis et al.,<sup>5</sup> about of 76 articles with 3399 patients and 380 controls, concluded that the wide variety of surgical techniques, diagnostic criteria and imaging techniques makes it difficult to compare studies to reach conclusions, all of which have levels of low-moderate evidence (between 2 and 4).

In relation to the management of these patients, in 2007, Larry Wolford referred to the combined use of open TMJ surgery (by means of meniscopexy with a Mitek™ mini-anchor) and orthognathic surgery simultaneously, safely and predictably, being necessary a correct diagnosis and treatment and demanding the surgeon wide experience in both types of surgery.<sup>6</sup> The results from two other studies by Wolford are illustrative.<sup>7,8</sup> The author observed significantly better results in terms of pain after surgery, severe pain, skeletal-occlusal outcomes and maximum oral opening for the group of patients who, having pre-surgical joint symptoms, were operated simultaneously by means of TMJ and orthognathic surgery, compared to the poor results of the group

that underwent orthognathic surgery alone. In a recent review article, Nale<sup>9</sup> synthesized the state of the art: 1) TMJ disease and dentofacial deformities should be treated independently one each other; 2) the majority of the authors propose that the treatment of joint disease should be performed first and 3) only once the joint symptoms have improved should the surgical treatment of skeletal malocclusion be performed.

Our philosophy in the management of patients with joint symptoms (pain and/or difficulty in mouth opening) is consistent with that of Wolford’s way in the mandatory need for surgical treatment of the joint disease (specifically internal derangement due to its high prevalence within this field) to obtain predictable results in the patient undergoing orthognathic surgery. However, we consider that minimally invasive surgery of the TMJ by means of operative arthroscopy (anterior myotomy of the lateral pterygoid muscle –to obtain a release of the disc- plus electrocoagulation of the posterior ligament by radiofrequency –to eliminate synovitis and obtain a scarification of the bilaminar area-) is effective in the treatment of the symptomatic patient (with pain and/or limitation for mouth opening), previously to surgery of the dentofacial deformity and as an alternative to open surgery of the TMJ. Of course, open surgery by means of meniscopexy or discectomy is unquestionable in cases refractory to arthroscopic treatment. For better illustration, Fig.1 schematizes our decision-tree proposal.

In a brief summary: 1) there is a manifest disparity in what has been published about the management of the patient with TMJ disease who will undergo orthognathic surgery for the treatment of dentofacial deformity; 2) we believe that the patient with joint pathology and dentofacial deformity should receive surgical treatment for both of them independently, performing joint surgery before and or, alternatively, simultaneously with orthognathic surgery; 3) in our experience, operative arthroscopy of the TMJ is an effective technique in the treatment of the majority of patients with joint dysfunction prior to orthognathic surgery.

Raúl González-García, MD, PhD, FEBOMFS  
 Servicio de Cirugía Oral y Maxilofacial. Hospital Universitario de Badajoz, España.  
 Director de Revista Española de Cirugía Oral y Maxilofacial

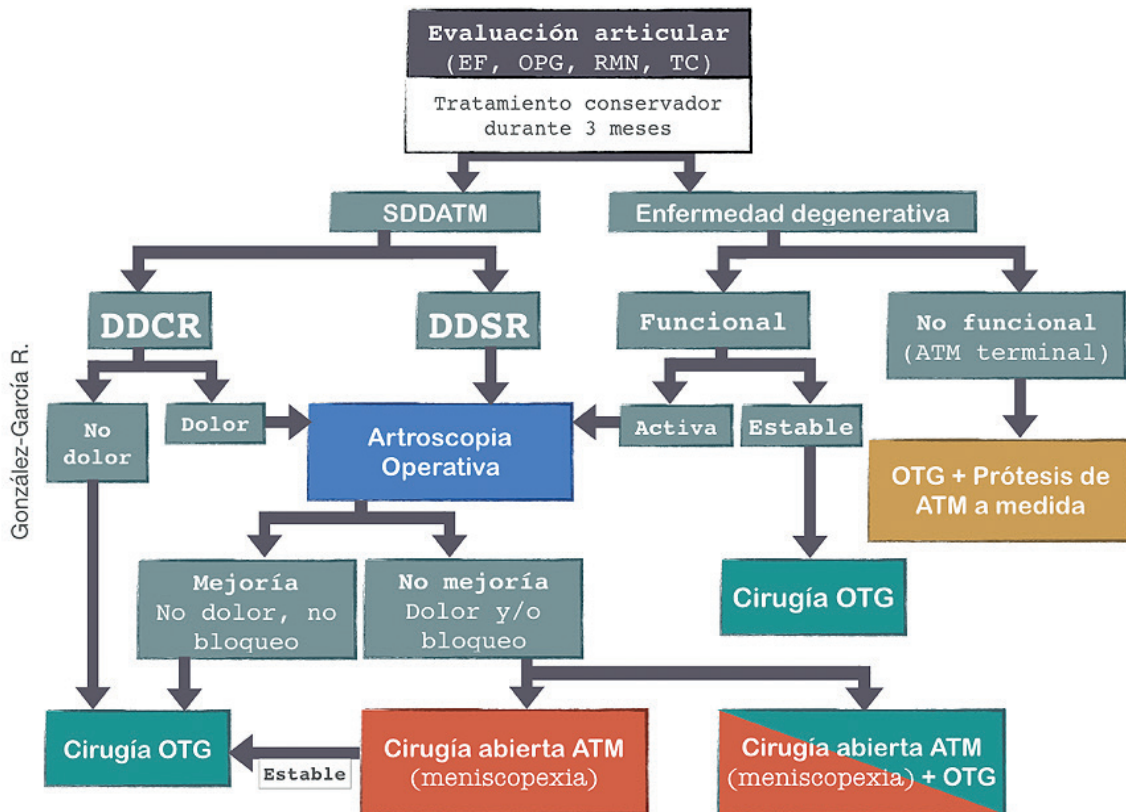


Figure 1. Proposal for a therapeutic decision-tree in patients with joint disease and concomitant dentofacial deformity. Abbreviations: EF, physical examination; OPG, orthopantomography; NMR, nuclear magnetic resonance (MRI); CT, computed tomography; SDDATM: TMJ dysfunction syndrome; DDCR, disc displacement with reduction (DDwR); DDSR, disc displacement without reduction (DDwoR); OTG, orthognathic.

## R E F E R E N C E S

1. Kircos LT, Ortendahl DA, Mark AS, Arakawa M. Magnetic resonance imaging of the TMJ disc in asymptomatic volunteers. *J Oral Maxillofac Surg.* 1987;45(10):852-4. DOI: 10.1016/0278-2391(87)90235-7.
2. Tallents RH, Katzberg RW, Murphy W, Proskin H. Magnetic resonance imaging findings in asymptomatic volunteers and symptomatic patients with temporomandibular disorders. *J Prosthet Dent.* 1996;75(5):529-33. DOI: 10.1016/s0022-3913(96)90458-8.
3. Jung WS, Kim H, Jeon DM, Mah SJ, Ahn SJ. Magnetic resonance imaging-verified temporomandibular joint disk displacement in relation to sagittal and vertical jaw deformities. *Int J Oral Maxillofac Surg.* 2013;42(9):1108-15. DOI: 10.1016/j.ijom.2013.03.012.
4. Dujoncquoy JP, Ferri J, Raoul G, Kleinheinz J. Temporomandibular joint dysfunction and orthognatic surgery: a retrospective study. *Head Face Med.* 2010;6:27. DOI: 10.1186/1746-160X-6-27.
5. Te Veldhuis EC, Te Veldhuis AH, Brammer WM, Wolvius EB, Koudstaal MJ. The effect of orthognatic surgery on the temporomandibular joint and oral function: a systematic review. *Int J Oral Maxillofac Surg.* 2017;46(5):554-63. DOI: 10.1016/j.ijom.2017.01.004.
6. Wolford LM. Clinical indications for simultaneous TMJ and orthognatic surgery. *Cranio.* 2007;25(4):273-82. DOI: 10.1179/crn.2007.041.
7. Wolford LM, Karras S, Mehra P. Concomitant temporomandibular joint and orthognatic surgery: a preliminary report. *J Oral Maxillofac Surg.* 2002;60(4):356-62. DOI: 10.1053/joms.2002.31220.
8. Wolford LM, Reiche-Fischel O, Mehra P. Changes in temporomandibular joint dysfunction after orthognatic surgery. *J Oral Maxillofac Surg.* 2003;61(6):655-60. DOI: 10.1053/joms.2003.50131.
9. Nale JC. Orthognatic surgery and the temporomandibular joint patient. *Oral Maxillofac Surg Clin North Am.* 2014;26(4):551-64. DOI: 10.1016/j.coms.2014.08.012.