



Revista Española de Cirugía Oral y Maxilofacial

Publicación Oficial de la SECOM CyC Sociedad Española de Cirugía Oral y Maxilofacial y de Cabeza y Cuello

Artículo Aceptado para su pre-publicación / Article Accepted for pre-publication

Título / Title:

Written in english / Evaluation of the Efficacy of the SonicWeld Rx® System in Maxillofacial Fractures: A Clinical Study

Autores / Authors:

Abdullah Alqattan, Thair Abdul Lateef

DOI: [10.20986/recom.2024.1517/2024](https://doi.org/10.20986/recom.2024.1517/2024)

Instrucciones de citación para el artículo / Citation instructions for the article:

Alqattan Abdullah, Abdul Lateef Thair. Written in english / Evaluation of the Efficacy of the SonicWeld Rx® System in Maxillofacial Fractures: A Clinical Study. *j.maxilo* 2024. doi: 10.20986/recom.2024.1517/2024.



Este es un archivo PDF de un manuscrito inédito que ha sido aceptado para su publicación en la *Revista Española de Cirugía Oral y Maxilofacial*. Como un servicio a nuestros clientes estamos proporcionando esta primera versión del manuscrito en estado de prepublicación. El manuscrito será sometido a la corrección de estilo final, composición y revisión de la prueba resultante antes de que se publique en su forma final. Tenga en cuenta que durante el proceso de producción se pueden dar errores, lo que podría afectar el contenido final. El copyright y todos los derechos legales que se aplican al artículo pertenecen a la *Revista Española de Cirugía Oral y Maxilofacial*.

EVALUATION OF THE EFFICACY OF THE SONICWELD RX® SYSTEM IN MAXILLOFACIAL FRACTURES: A CLINICAL STUDY

EVALUACIÓN DE LA EFICACIA DEL SISTEMA SONICWELD RX® EN FRACTURAS MAXILOFACIALES: UN ESTUDIO CLÍNICO

Thair A. Lateef Hassan¹, Abdullah Hasan Alqattan²

¹*Department of Oral and Maxillofacial Surgery. College of Dentistry, University of Baghdad. Baghdad, Iraq.* ²*Department of Oral and Maxillofacial Surgery. Al Yarmook Teaching Hospital. Baghdad, Iraq*

CORRESPONDENCE:

Abdullah Hasan Alqattan

aboodi916@gmail.com

Received: 28-03-2024

Accepted: 18-04-2024

ABSTRACT

Background: SonicWeld Rx® is a novel internal fixation system that relies on ultrasonic waves for pin fixation coupled with reabsorbable plates into the tissue. The heat generated by these sonic waves will thermoplastize the pin, and with friction with the bone upon pin placement, it will melt and flow into the trabecular spaces of the adjacent bone, followed by welding of the pin with the plate, forming one functional unit. This system allows less operation time and fewer screw-related complications, such as screw fractures, along with the advantage of being resorbable.

Aim: To evaluate the efficacy of the SonicWeld Rx® system as a treatment modality of internal fixation for facial fractures.

Patients and methods: Twenty patients enrolled in this study were subjected to open reduction and internal fixation via the SonicWeld Rx® system as a treatment modality for

facial fractures. Pinhole ossification, fracture reduction, plate application time and patient satisfaction were studied postoperatively.

Results: All patients were males with ages ranging from 8-41 years and a mean of 23.45 years with a standard deviation (SD) of ± 9.65 . Concerning the surgical approach, 10 patients were managed via an extraoral approach and 3 through an intraoral approach, while the remaining 7 patients were managed by combined approaches. With respect to pinhole ossification and reduction adequacy, 19 patients experienced full-hole ossification and adequate reduction, and those patients were completely satisfied with the final outcome of treatment. Regarding plate application time, there was a significant reduction in the plate application time when compared with the conventional screw-plate resorbable system.

Conclusion: The SonicWeld Rx[®] resorbable plating system showed favorable treatment outcomes regarding fracture reduction adequacy, pinhole ossification and patient satisfaction, with a noticeable reduction in plate application time.

Keywords: SonicWeld Rx, Resorbable plating, Facial bones fractures, Application time, Pinhole ossification.

RESUMEN

Antecedentes: SonicWeld Rx[®] es un novedoso sistema de fijación interna que se basa en ondas ultrasónicas para la fijación de clavos acoplados a placas reabsorbibles en el tejido. El calor generado por estas ondas sónicas termoplastificará el perno y, con la fricción con el hueso al colocar el perno, se fundirá y fluirá hacia los espacios trabeculares del hueso adyacente, seguido de la soldadura del perno con la placa, formando una unidad funcional. Este sistema permite reducir el tiempo de intervención y las complicaciones relacionadas con los tornillos, como las fracturas de los mismos, junto con la ventaja de ser reabsorbible.

Objetivo: Evaluar la eficacia del sistema SonicWeld Rx[®] como modalidad de tratamiento de fijación interna para fracturas faciales.

Pacientes y métodos: Veinte pacientes incluidos en este estudio fueron sometidos a reducción abierta y fijación interna mediante el sistema SonicWeld Rx[®] como modalidad de

tratamiento de fracturas faciales. Se estudiaron postoperatoriamente la osificación pinhole, la reducción de la fractura, el tiempo de aplicación de la placa y la satisfacción del paciente.

Resultados: Todos los pacientes eran varones con edades comprendidas entre los 8 y los 41 años y una media de 23,45 años con una desviación estándar (DE) de $\pm 9,65$. En cuanto al abordaje quirúrgico, 10 pacientes fueron tratados mediante un abordaje extraoral y 3 mediante un abordaje intraoral, mientras que los 7 pacientes restantes fueron tratados mediante abordajes combinados. Con respecto a la osificación del agujero de alfiler y la reducción adecuada, 19 pacientes experimentaron una osificación completa del agujero de alfiler y una reducción adecuada, y esos pacientes estaban completamente satisfechos con el resultado final del tratamiento. En cuanto al tiempo de aplicación de la placa, se produjo una reducción significativa del tiempo de aplicación de la placa en comparación con el sistema reabsorbible convencional tornillo-placa.

Conclusiones: El sistema de placas reabsorbibles SonicWeld Rx[®] mostró resultados de tratamiento favorables en cuanto a la adecuación de la reducción de la fractura, la osificación pinhole y la satisfacción del paciente, con una notable reducción del tiempo de aplicación de la placa.

Palabras clave: SonicWeld Rx, placas reabsorbibles, fracturas de huesos faciales, tiempo de aplicación, osificación pinhole.

INTRODUCTION

In 1966, *Kulkarni* established and published the first study on the use of biodegradable implants, which studied the biocompatibility of poly-L-lactic acid plates for mandibular fracture fixation in animals¹. It had limited clinical use for osteosynthesis because of its susceptibility to rapid degradation approximately 4-7 weeks after implantation (a duration that was insufficient to allow for complete bone healing)².

Poly-L-lactide (PLLA) and poly-D-lactide (PDLA) are bioresorbable monomers that have been developed since the early 1990s. PLLA has been used as a maxillofacial osteosynthesis material as “the first generation” bioresorbable osteosynthetic material, but these two polymers have associated problems, such as a restorability period, foreign body reaction

and inflammatory response³.

Copolymers of PGA, PLLA, and PDLA were preferred over pure PGA and PLLA as “the second generation” as rapidly bioresorbable osteosynthetic materials possessing amorphous structures with higher rates of hydration and hydrolysis. The copolymer is structured to provide adequate strength for 6-8 weeks and for a complete resorption time of 12-18 months. These products are feasible in clinical applications for midfacial osteosynthesis as secure and rapid bioresorbable materials^{2,4}.

Unsintered hydroxyapatite has been incorporated into PLLA because of its documented osteoconductive capacity as “the third generation”, while u-HA/PLLA/PGA combines u-HA particles and a copolymer of PLLA and PGA, known as “the fourth generation”^{2,5}.

The SonicWeld Rx[®] system is composed of the amorphous copolymer, which is a poly-D- and L-lactic acid device (PDLLA) of a 50:50 mixture of D-lactide and L-lactide, boasts short resorption times, minimal foreign body reaction, and adequate strength for bony fixation in non load-bearing areas in the skull⁶. In contrast to conventional biodegradable osteofixation systems, tapping of the cortical bone layer is not necessary before inserting the SonicWeld Rx biodegradable pins⁷.

PATIENTS AND METHODS

This is a clinical observational prospective study organized from October 2021 to May 2023 in the Maxillofacial Surgery Department of Al-Yarmouk Teaching Hospital in Baghdad as a fulfillment requirement for the fellowship in the Maxillofacial Surgery of the Iraqi Board for Medical Specializations. A total of 20 patients enrolled in this study, all males aged 8-41 years, met the eligibility criteria and were subjected to facial trauma coupled with fractures related to the facial skeleton. They were managed with open reduction and internal fixation utilizing the SonicWeld Rx[®] osteosynthesis bioresorbable system as the treatment modality. Patients in this study met certain criteria, including patients who sustained single or multiple fractures involving the facial bones indicated for open reduction and internal fixation with any degree of displacement, participants of any age group for midfacial fractures (including both maxillary and zygomatic fractures) and mandibular condylar fractures who refused the introduction of metallic plates to their facial skeleton beside other mandibular fractures

aside from the condyle from 1-10 years for pediatric fractures, and patients with good general health without any systemic disease compromising bone healing potential for the sake of standardization.

While the exclusion criteria were any systemic condition that could interfere with normal bone healing, local conditions such as the presence of acute/chronic infection, comminuted and pathological fractures, individuals with facial fractures as a result of civilian or missile injuries with considerable soft tissue loss, and patients with age above 10 years subjected to mandibular fractures except for the mandibular condyle.

Preoperative assessment

All patients had undergone the Advanced Trauma Life Support (ATLS) protocol after being received by the emergency department. A detailed history was taken from patients followed by clinical examination, including extraoral and intraoral inspection for any signs of maxillofacial facial injury along with palpation for any step deformity that would indicate a facial bone fracture, succeeded by investigations such as radiographs to confirm and evaluate any fracture to the facial skeleton, as displayed in Figure 1.

Operative phase

According to the previously organized treatment plan, surgery would take place through a proper surgical approach that would give appropriate access to the fracture and allow good reduction and placement of plates and pins. The number, shape, thickness and site of the plates were recorded in addition to the pin number, diameter and length in addition to the plate application time using a stopwatch. A biodegradable pin is placed onto an ultrasound-activated electrode called the sonotrode and inserted into the borehole. As a result of the added ultrasound energy, the thermoplastic biodegradable pin melts, resulting in a flow of biodegradable polymers into the cortical bone layer and the cavities of the cancellous bone. There is no cellular reaction due to thermal stress during insertion. The biodegradable plate and pinhead fuse at the same time. Theoretically, the fusion of the plate and pinhead will result in superior mechanical device characteristics compared to conventional

biodegradable osteofixation systems⁷, as revealed in Figure 1.

Patient follow-up

All patients in this study were kept under observation and were hospitalized for 24 hours postoperatively. An antibiotic regimen was prescribed for all patients, administered as intravenous ceftriaxone on the day of surgery followed by Co-Amoxiclav and metronidazole tablets for six days postoperatively (no penicillin-allergic patients were encountered). Acetaminophen vial was given intravenously on the day of surgery followed by tablet preparation on need as a pain killer. Maxillomandibular fixation was maintained for 2 weeks postoperatively in cases where occlusion was disturbed.

The patients were evaluated both subjectively and objectively 7-10 days postoperatively for suture removal, at 2 weeks for MMF release, and regularly at 3- and 9-month follow-up intervals. The postoperative assessment was performed subjectively by the surgeon and patient for wound discomfort or pain, satisfaction with the results, possible wound dehiscence, pus discharge, sinus formation, plate exposure, and occlusion disturbances. The objective assessment was assessed by taking either CT or CBCT 3 and 9 months postoperatively (taking into consideration not to obtain CT scan in less than 6 months interval) to assess the adequacy of fracture fixation with resorbable plates, fracture healing and displacement, bone union and pinhole ossification as visible in Figure 1.

RESULTS

Twenty male patients were enrolled in this study. The patients' ages ranged from 8-41 years, with an average of 23.45 years, a standard deviation (SD) of ± 9.65 and a median of 24 years.

In this research, 10 patients (50 %) were managed via an extraoral approach (6 cases in the midface area and 4 in the mandible), 3 patients (15 %) were treated through an intraoral procedure approach (2 cases in the midface and one in the mandible) and 7 patients (35 %) were treated via combined extraoral and intraoral approaches. Regarding the fracture site, the largest number was 14 (70 %), which was reported in the midface, and 6 (30 %) were

registered in the mandible.

Supplemental Table I explains that 19 cases displayed adequate fracture reduction and complete hole ossification with no statistically significant difference between study variables. On the other hand, surgical site infection was reported in one case during the follow-up period without any substantial changes in the statistical results regarding age, fracture multiplicity, fracture site and surgical approach.

There was no significant difference concerning patient satisfaction in relation to the study variables, as only one patient was unsatisfied with the final outcome of the treatment.

There was no significant difference concerning the mean plate time with the variables of the study, as reported in the supplemental Table II.

The time required for the application of each plate is presented in Figure 2.

In this study, the plate application time was divided into two entities, the maxilla and the mandible, to compare their correlation to age separately, and the results showed a significant moderate inverse association for the midface (Pearson's test $r = -0.65$, $P \text{ value} = 0.03^* \text{ Sig}$). Furthermore, there was no significant inverse association for the mandible (Pearson's test $r = -0.06$ $P \text{ value} = \text{NS}$).

Regarding intraoperative complications, out of 35 plates, one plate was subjected to replacement due to the need for a longer plate for the fractured pieces of the zygomatic body to obtain optimum fixation. For postoperative complications, the most prominent complication encountered was the development of sterile abscess that led to inadequate healing of the fracture site, which was registered in one case (5 %). Additionally, two cases (10 %) of neurological disturbances were observed and recorded, as paresthesia over the infraorbital region and weakness of the marginal mandibular nerve, both cases were transient.

DISCUSSION

Surgical approach and fracture site

In this study, 10 cases (50 %) were managed via an extraoral approach (6 cases in the midface area and 4 in the mandible), 3 cases (15 %) were treated through an intraoral

procedure (2 cases in the midface and one in the mandible) and 7 cases (35 %) were treated via a combined approach. The intraoral and extraoral approaches were also used by Arya et al., 2020⁸ and Ongodia et al., 2013⁹ (11 intraoral and 3 extraoral) in the management of mandibular fractures via resorbable plates. In contrast, Lauren et al., 2020¹⁰, in their study considering the treatment of mandibular fractures in 336 patients, utilized a miniplate system through an isolated intraoral approach for the fixation of 391 mandibular fractures. Midfacial fractures were dominant in 14 cases (70 %), and 6 cases (30 %) involved mandibular fractures. The sequela of the present study was not on the same page as that of Cleveland et al., 2020¹¹, who found that the most commonly fractured facial bone in the face was the mandible (36.9 %), followed by the maxilla (30.9 %), nasal bone (27.3 %) and orbital floor (19.4 %).

Fracture reduction and pinhole ossification

After finishing the follow-up period and radiographical examination (3 and 9 months postoperatively), fracture reduction and bone healing were adequate in 19 cases (95 %), as the decision for adequacy was made through the observation of the position of fractured segment ends compared with previously taken postoperative radiographs. Settled bone and undisturbed reduction were considered hallmarks of stable and adequate fixation. Other than a single case (5 %) that presented with mild malunion, which was not statistically significant, healing occurred after drainage of the sterile abscess and removal of plates and pin remnants.

These results are in the same direction as Dubina et al., 2013¹², who reported that neither of their cases met a change in transplant and implant configuration nor displaced plates and pins. The rigid fixation of bone fragments was observed in their study, and Iwanaga et al., 2021¹³ stated in their study when comparing the biomechanical stiffness of titanium and SonicWeld Rx[®] osteofixation systems for monoblock zygomaticomaxillary complex fractures that there was no significant difference between the two systems.

Furthermore, El-Saadany et al., 2015¹⁴ studied bone healing radiographically via CT scan in pediatric mandibular fractures fixated by the Sonicweld system and found that the fracture line was difficult to see after 3 months and almost disappeared after six months.

Concerning pinhole ossification, the holes appeared completely ossified radiographically in 95 % of cases, which was interpreted clinically as part of normal bone healing, remodeling and new bone formation in the location of the drill hole. One case (5 %) underwent sterile abscess formation, and pins were removed before complete ossification had taken place after 9 months.

Plate application time and patient satisfaction

In this research, there was a significant difference in the meantime of plate application between patients with single and multiple fractures, with a mean of 8.8 ± 2.4 vs 25.3 ± 12.9 min, respectively.

It is noteworthy here that the time consumption for the first two plates took 11 and 19 minutes, respectively, while the last two plates took only 5 and 8 minutes, respectively, which sheds light on the rise of the learning curve for both the operator and the assistant.

Regarding another variable, there was no significant difference in the meantime of plate application between mandibular and midfacial fractures, with a mean of 10.2 ± 2.4 vs 16.5 ± 12.7 min, respectively, as time was calculated for 4 holes (33 plates) and 5 holes (2 plates) collectively.

The statistical lack of significance is related to the properly exposed fracture site and attempting to gain the best access for the plates and pins, but the difference in mean time between the midface and mandible was more than 6 min, which was clinically irrelevant and was related to the anatomical restrictions to gain access for the handpiece during the limited intraoral approach for the mandible compared to the extraoral approach for the midface in most cases. On the other hand, regarding the surgical approach, the plate application time was 8.9 ± 2.9 vs. 9.0 ± 2.0 vs. 25.1 ± 13.1 min for extraoral, intraoral and combined approaches, respectively.

This paper reports a moderate significance regarding this variable and the explanation is quite simple which would make it also clinically relevant as patients with a single incision whether approached intraorally or extraorally are most likely to have a single fracture that requires a single plate to be fixed, even with the requirement of second plate, the additional plate application would be straightforward requiring less time for application.

The final results were analogous to those of Sweedan et al., 2016¹⁵, who found a plate application time of 10.6 min with an SD of 1.6, which was compatible with the current study that found 8.3 with an SD of 2.6. The slight difference may be interpreted as they applied 20 plates, while the current study involved 35 plates placed, which may allow better development of the learning curve. Additionally, the results found by Yadav et al., 2019¹⁶ included that the plate placement time for the conventional titanium miniplate was 19.0 min and 13.9 min for the 3D titanium plate, both of which consume more time than the Sonicweld system.

Regarding patient satisfaction, outside of a single case (5 %), all patients were satisfied with the terminal net results of this treatment modality after completing the 9-month succeeding surgery follow-up period. The results were in line with those of Wendelken and Sullivan, 2008⁽¹⁷⁾, who found similar results with overall high patient satisfaction with the Sonicweld system in temporomandibular joint surgery.

Intraoperative complications

In the present study, in the early cases, the operator faced pin-associated issues in 5 pins (3.5 %), which presented as 4 pins dislodged when placed above the pinhole due to rushing in the activation of the sonotrode and one pin fell on the ground due to improper attachment. This has been overwhelmed with the gain of more experience in operating with this system. Reichwein et al., 2009¹⁸ reported in their study that pin insertion could be finished with a total failure rate of lower than 5 %, which corroborates ideas with the current research.

It comes with a great portion of value to mention one intraoperative case faced difficulty when the operator needed to replace the plate with a longer one after being welded to the bone to gain the optimum fixation of the fracture, the removal was strenuous and required a surgical removal with handpiece and burs to be replaced which is not faced with the use of screwed plate system that only requires to loosen and untwist the screws, so in order to avoid such struggle it's advisable to select the proper plate before welding.

Postoperative complications

Sterile abscess formation was recorded in one case (5 % of total cases). The patient presented with painless bulging at the plate site and wound discharge at the surgical site without wound redness in the second month of follow-up. The abscess was drained surgically, and the plates and pins were removed after one month (three months postoperatively), followed by wound toilet and primary closure in the supraorbital rim region with the prescription of antibiotics.

Similar complications were observed by Nkenke et al. 2011¹⁹ in 3 out of 10 patients who had noted bulging of the plate and postoperative infection, and drainage and plate remnant removal were performed under general anesthesia, with regard to postoperative infection of titanium plates Daniels et al. 2021²⁰ found a similar infection rate of 4.7 % related to these metallic plates.

Two cases (10 %) revealed neurological disturbances. The first disturbance was paresthesia over the infraorbital nerve distribution that lasted for 3 weeks. This event may have occurred during the reduction and mobilization of the fractured segment containing the infraorbital nerve to the normal anatomical position. The second disturbance was a transient weakness of the orbicularis oris muscle that could be attributed to neuropraxia of the marginal mandibular nerve emanating from injudicious flap retraction, which remained for one week.

CONCLUSION

The SonicWeld Rx[®] resorbable plating system was a major milestone advancement in the aspect of plate application time in comparison to the ordinary plate-screw resorbable system and reduced the application time with the elevation of the learning curve with pleasant outcomes regarding fixation adequacy after reduction during the healing period with excellent pin hole ossification and patient satisfaction with the final outcome of the treatment.

Funding

There is no funding to declare.

REFERENCES

1. Kulkarni RK, Pani KC, Neuman C, Leonard F. Polylactic acid for surgical implants. *Arch Surg.* 1966;93(5):839-43. DOI: 10.1001/archsurg.1966.01330050143023.
2. Kanno T, Sukegawa S, Furuki Y, Nariai Y, Sekine J. Overview of innovative advances in bioresorbable plate systems for oral and maxillofacial surgery. *Jpn Dent Sci Rev.* 2018;54(3):127-38. DOI: 10.1016/j.jdsr.2018.03.003.
3. Burns B, Fields JM, Farinas A, Pollins A, Perdakis G, Thayer W. Comparing maximal forces in resorbable poly-L-lactic acid and titanium plates for mandibular fracture fixation. *Heliyon.* 2020;6(4):e03705. DOI: 10.1016/j.heliyon.2020.e03705.
4. Ahmed R, Muthusekhar MR, Senthil Murugan P. Bioresorbable Plate Systems for Oral and Maxillofacial Surgery: A Review. *J Res Med Dent Sci.* 2021;9(9):215-22.
5. Ngo HX, Bai Y, Sha J, Ishizuka S, Toda E, Osako R, et al. A Narrative Review of u-HA/PLLA, a Bioactive Resorbable Reconstruction Material: Applications in Oral and Maxillofacial Surgery. *Materials (Basel).* 2021;15(1):150. DOI: 10.3390/ma15010150.
6. Wood RJ, Petronio JA, Graupman PC, Shell CD, Gear AJ. New resorbable plate and screw system in pediatric craniofacial surgery. *J Craniofac Surg.* 2012;23(3):845-9. DOI: 10.1097/SCS.0b013e31824dbed8.
7. Buijs GJ, van der Houwen EB, Stegenga B, Verkerke GJ, Bos RR. Mechanical strength and stiffness of the biodegradable SonicWeld Rx osteofixation system. *J Oral Maxillofac Surg.* 2009;67(4):782-7. DOI: 10.1016/j.joms.2008.07.022.
8. Arya S, Bhatt K, Bhutia O, Roychoudhury A. Efficacy of bioresorbable plates in the osteosynthesis of linear mandibular fractures. *Natl J Maxillofac Surg.* 2020;11(1):98-105. DOI: 10.4103/njms.NJMS_54_19.
9. Ongodia D, Li Z, Xing WZ, Li ZB. Resorbable plates for fixation of complicated mandibular fractures in children. *J Maxillofac Oral Surg.* 2014;13(2):99-103. DOI: 10.1007/s12663-013-0501-z.
10. Bohner L, Beiglboeck F, Schwipper S, Lustosa RM, Pieirna Marino Segura C, Kleinheinz J, Jung S. Treatment of Mandible Fractures Using a Miniplate System: A Retrospective

- Analysis. *J Clin Med.* 2020;9(9):2922. DOI: 10.3390/jcm9092922.
11. Cleveland CN, Kelly A, DeGiovanni J, Ong AA, Carr MM. Maxillofacial trauma in children: Association between age and mandibular fracture site. *Am J Otolaryngol.* 2021;42(2):102874. DOI: 10.1016/j.amjoto.2020.102874.
 12. Dubina L, Drobyshev A, Davydov D, Yakimenko I. Experience of using ultrasonic resorbable system in treatment of patients with traumatic injury of face skeleton bones. *Int J Oral Maxillofac Surg.* 2013;42(10):1222. DOI: 10.1016/j.ijom.2013.07.177.
 13. Iwanaga H, Nuri T, Ueda K. Comparison of the Biomechanical Stiffness of Titanium and Sonic Weld RX Osteofixation Systems for Monoblock Zygomaticomaxillary Complex Fractures. *J Craniofac Surg.* 2021;32(4):1549-52. DOI: 10.1097/SCS.00000000000007167.
 14. El-Saadany WH, Sadakah AA, Hussein MM, Saad KA. Evaluation of Using Ultrasound Welding Process of Biodegradable Plates for Fixation of Pediatric Mandibular Fractures. *Tanta Dental Journal.* 2015;12(Suppl. 1):S22-9. DOI: 10.1016/j.tdj.2015.08.003.
 15. Sweedan AO, Hassan NE, El-Sheikh SA, El-Dibany RM, Kawana KY. Evaluation of Resorbable Plates with Ultrasonic Welded Pins in the Management of Midface Fractures Clinical, Histological, and Biomechanical Study. *Alexandria Dental J.* 2016;41:269-76.
 16. Yadav D, Mishra R, Tripathi S, Kandel L, Pahari B. 3-Dimensional versus Conventional Titanium Miniplate Osteosynthesis in Mandibular Fracture. A Comparative Study. *Adv Research Dentistry Oral Hygiene.* 2019;1:1.
 17. Wendelken JA, Sullivan SM. Poster 078: Use of the Ultrasound-Activated Pinned SonicWeld Rx Resorbable Anchor as an Alternative to the Mitek Mini Anchor in Temporomandibular Joint Disc-Repositioning Surgery: Report of a Technique and Preliminary Findings. *J Oral Maxillofac Surg.* 2008;66:115.
 18. Reichwein A, Schicho K, Moser D, Seemann R, Poeschl P, Baumann A, et al. Clinical experiences with resorbable ultrasonic-guided, angle-stable osteosynthesis in the panfacial region. *J Oral Maxillofac Surg.* 2009;67(6):1211-7. DOI: 10.1016/j.joms.2008.12.033.

19. Nkenke E, Vairaktaris E, Schwarz S, Eyüpoglu I, Ganslandt O, Leis T, et al. Prospective assessment of complications associated with ultrasound activated resorbable pin osteosynthesis in pediatric craniofacial surgery: preliminary results. *Neurocirugia (Astur)*. 2011;22(6):498-506. DOI: 10.1016/s1130-1473(11)70105-1.
20. Daniels JS, Albakry I, Braimah RO, Samara MI. Is The Routine Removal of Titanium Plates and Screws Following Miniplate Osteosynthesis of Maxillofacial Bone Fractures Justified? A Fifteen-Year Experience in a Maxillofacial Centre, Saudi Arabia. *Craniofacial Trauma & Reconstruction*. 2021;6:1-9.

Figure 1. A: a lateral view of three-dimensional CT view revealing the lateral displacement of the right mandibular condyle (*arrow*). B: application of SonicWeld[®] resorbable plate following reduction (*arrow*). C, D: follow up with 3D view of CBCT scan for the facial bones demonstrating pin holes ossification and bone healing (*arrows*) after three months and nine months respectively.

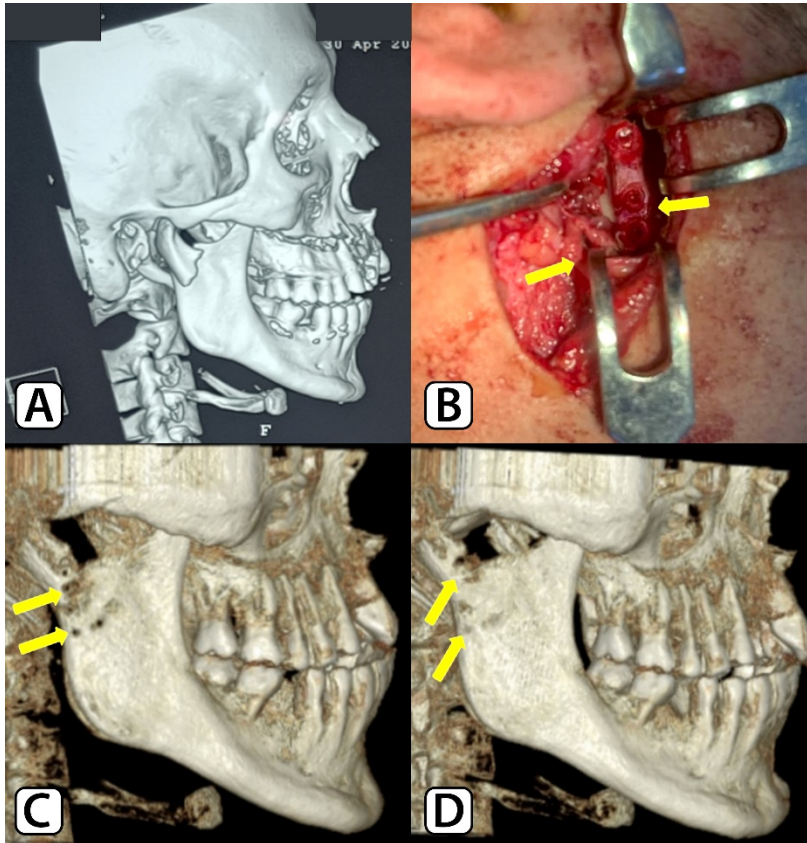


Table I. Hole ossification and fracture reduction correlation with different variables.

Variables	Total No. (%)	Fracture reduction			Hole ossification		
		Yes No. (%)	No No. (%)	P-value	Yes No. (%)	No No. (%)	P-value
Age							
> 24	10 (50)	9 (45)	1 (5)	Fisher's exact test P-value 0.999 NS	9 (45)	1 (5)	Fisher's exact test P-value 0.999 NS
≤ 24	10 (50)	10 (50)	0		10 (50)	0	
Fracture multiplicity							
Single	13 (65)	12 (60)	1 (5)	Fisher's exact test P-value 0.999 NS	12 (60)	1 (5)	Fisher's exact test P-value 0.999 NS
Multiple	7 (35)	7 (35)	0		7 (30)	0	
Fracture site							
Midface	14 (70)	13 (65)	1 (5)	Fisher's exact test P-value 0.999 NS	13 (70)	1 (5)	Fisher's exact test P-value 0.999 NS
Mandible	6 (30)	6 (30)	0		6 (30)	0	
Surgical approach							
Extraoral	10 (50)	9 (45)	1 (5)	Chi-squared P-value 0.591 NS	9 (45)	1 (5)	Chi-squared P-value 0.591 NS
Intraoral	3 (15)	3 (15)	0		3 (15)	0	
Combined	7 (35)	7 (35)	0		7 (35)	0	

Table II. The relation between plate application time and study variables.

Variables	Total No. (%)	Plate application time (min)	
		Mean±SD	P-value
Fracture multiplicity			
Single	13 (65)	8.8 ± 2.4	Unpaired t-test with Welch's correction P-value 0.0149 Sig *
Multiple	7 (35)	25.3 ± 12.9	
Fracture site			
Midface	14 (70)	16.5 ± 12.7	Mann Whitney test P-value 0.5309 NS
Mandible	6 (30)	10.2 ± 2.4	
Surgical approach			
Extraoral	10 (50)	8.9 ± 2.9	Brown-Forsythe ANOVA test P-value 0.0092 Sig **
Intraoral	3 (15)	9.0 ± 2.0	
Combined	7 (35)	25.1 ± 13.1	

Figure 2. A line graph showing the time required for the application of a single plate.

