

Original

Ameloblastic fibroma: a report of 4 clinical cases and review of the literature

Marta María Pampín Martínez^{1*}, José Juan Pozo Kreilinger², Jesús Manuel Muñoz Caro¹, Juan Pablo Rodríguez Arias¹, Elena M. Gómez García¹, Mercedes Martín Pérez¹ and José Luis Cebrián Carretero¹

¹Oral and Maxillofacial Surgery Department. La Paz Hospital. Madrid. Spain. ²Pathological Anatomy. La Paz Hospital, Madrid. Spain

INFORMACIÓN DEL ARTÍCULO

Historia del artículo:

Recibido: 15 de mayo de 2022

Aceptado: 05 de octubre de 2022

Keywords:

Ameloblastic fibroma, odontogenic tumor, cystic lesion.

A B S T R A C T

Introduction: Ameloblastic fibroma is a rare benign mixed odontogenic tumor that usually presents as a painless swelling in young patients. In this article we performed a literature review and present our experience in the management of fibroblastic ameloblastoma in 4 cases.

Material and methods: We performed a review of cases published in the literature in PubMed between 2015 and 2022. Regarding our experience, research in the Anatomical Pathology department was done to find cases of ameloblastic fibroma that had been histologically confirmed.

Results: The search rendered 29 results, of which only 9 were selected. All articles were single case reports, and most of them were located in the mandible (77,7 %). Most patients underwent enucleation and curettage, and no recurrence were reported by any of the authors.

We found 4 cases operated in our department in the last 15 years. Two lesions were located in the maxilla and 2 in the mandible. In all cases, enucleation and curettage was performed, including extraction of the teeth involved, with a very favorable evolution and no recurrences.

Discussion: Management can be conservative, performing enucleation and curettage with a very favorable evolution. Variable rates of recurrence have been described and a malignant variant has been identified, so long-term follow-up must be done. In the literature we found only single case reports, with most of the cases presenting in the mandible and undergoing conservative treatment with favorable results. In our series we did not observe recurrences, with good bone regeneration and receiving subsequent orthodontic treatment.

*Autor para correspondencia:

Correo electrónico: mpampin@simergia.com (Marta María Pampín Martínez).

<http://dx.doi.org/10.20986/recom.2022.1367/2022>

Fibroma ameloblástico: reporte de 4 casos clínicos y revisión de la literatura

R E S U M E N

Palabras clave:

Fibroma ameloblástico, tumor odontogénico, lesión quística.

Introducción: El fibroma ameloblástico es un tumor odontogénico mixto benigno y poco frecuente que generalmente se presenta como un abombamiento indoloro en pacientes jóvenes. En este artículo realizamos una revisión de la literatura y presentamos nuestra experiencia en el manejo del ameloblastoma fibroblástico en 4 casos.

Material y métodos: Realizamos una revisión de los casos publicados en la literatura en Pub-Med entre 2015 y 2022. En cuanto a nuestra experiencia, se realizó una búsqueda en el departamento de Anatomía Patológica de los casos de fibroma ameloblástico confirmados histológicamente.

Resultados: La búsqueda arrojó 29 resultados, de los cuales solo 9 fueron seleccionados. Todos los artículos fueron reportes de casos únicos, y la mayoría de ellos se localizaron en la mandíbula (77,7 %). La mayoría de los pacientes se sometieron a enucleación y curetaje, y ninguno de los autores informó de recurrencia. Encontramos 4 casos operados en nuestro departamento en los últimos 15 años. Dos lesiones se localizaron en el maxilar y dos en la mandíbula. En todos los casos se realizó enucleación y curetaje, incluyendo exodoncia de los dientes afectados, con evolución muy favorable y sin recidivas.

Discusión: El manejo puede ser conservador, realizándose enucleación y curetaje con una evolución muy favorable. Se han descrito tasas variables de recurrencia y se ha identificado una variante maligna, por lo que se debe realizar un seguimiento a largo plazo. En la literatura encontramos solo informes de casos únicos, la mayoría de los casos se presentaron en la mandíbula y se sometieron a un tratamiento conservador con resultados favorables. En nuestra serie no observamos recidivas, con buena regeneración ósea y recibiendo tratamiento de ortodoncia posterior.

INTRODUCTION

Ameloblastic fibroma is a very rare mixed odontogenic tumor, representing only 2 % of odontogenic tumors¹ and mainly affects patients in the first two decades of life, with no sex predilection, being 80 % of the reported cases located in the mandible, usually in the premolar and/or molar area².

Despite many similarities, it is essential to differentiate the ameloblastic fibroma from other mixed odontogenic lesions because it has true neoplastic qualities³ and even malignant transformation cases have been reported⁴.

The effective surgical treatment includes enucleation and curettage of the surrounding bone and removal of the affected teeth⁵. Although recurrence of ameloblastic fibroma is rare, a long term follow up is recommended⁶.

Our objective is to analyze if the ameloblastic fibroma is amenable to conservative treatment and describe the main clinical characteristics and recurrence rates. We performed a literature review of ameloblastic fibroma case series published in the literature and we report our experience in 4 cases treated at the Pediatric Oral and Maxillofacial Surgery Department of Hospital La Paz in the last 15 years.

MATERIAL AND METHODS

We performed a literature review in the data base PubMed. The inclusion criteria were: articles reporting ameloblastic

fibroma of the jaws cases, that had been published between 2015 and 2022 and articles in English or Spanish. Exclusion criteria included articles published earlier than 2015, articles in a language different from English or Spanish and articles reporting cases of ameloblastic fibro-odontoma or fibrosarcoma or peripheral ameloblastic fibroma.

For this research we used the following MeSH terms: (((("Ameloblastic"[All Fields] AND ("fibroma"[MeSH Terms] OR "fibroma"[All Fields] OR "fibromas"[All Fields]) AND ("jaw"[MeSH Terms] OR "jaw"[All Fields] OR ("mandible"[MeSH Terms] OR "mandible"[All Fields] OR "mandibles"[All Fields] OR "mandible s"[All Fields]) OR ("maxilla"[MeSH Terms] OR "maxilla"[All Fields] OR "maxillae"[All Fields] OR "maxillas"[All Fields]))) NOT ("odontoma"[MeSH Terms] OR "odontoma"[All Fields] OR ("Ameloblastic"[All Fields] AND "fibro"[All Fields] AND "odontoma"[All Fields]) OR "ameloblastic fibro odontoma"[All Fields])) NOT ("Ameloblastic"[All Fields] AND "Fibro-Sarcoma"[All Fields])). A total of 29 results were obtained. One article was discarded because it was written in Chinese. Seven articles describing ameloblastic fibrosarcoma cases were also discarded. Two articles describing a peripheral ameloblastic fibroma were also discarded. Seven articles presented cases of lesions different from ameloblastic fibroma and, therefore, were not included.

A total of 13 articles fulfilled the inclusion criteria, reporting cases of ameloblastic fibroma of the jaws. One article was rejected because of unavailability of full-text report. Finally, 12 articles were included.

Regarding our experience, a research was performed at the Anatomical Pathology department of our hospital and cases filed as ameloblastic fibroma that had been operated in the last 15 years were selected and analyzed.

RESULTS

We found 12 articles reporting cases of ameloblastic fibroma of the jaws. All articles were single case reports. Mean age was 8,3 years (Range [2-38]). Only three articles (25 %) reported ameloblastic fibroma cases presenting in the maxilla. All cases were associated to unerupted teeth. Most cases underwent conservative treatment with enucleation and curettage. One patient underwent segmental mandible resection with 1 cm safe margin and IAN preservation⁷, and one patient underwent enucleation and received an iliac crest graft⁸. One patient⁹ underwent marsupialization and curettage, with no recurrence. Three articles did not report follow up length, for the

rest of publications, the mean follow up was 26,11 months (Range [6-144]). No recurrences were reported in any of these cases. These research data is presented in Table I.

On the other hand, in the research at our hospital a total of four cases were found. Information regarding these cases is presented in Table II. Cases 2 and 3 presented with lesions in the posterior maxilla and cases 1 and 4 in the mandible (50 %) (symphysis and left posterior mandible). The mean age was 8,5 years (range [5-13]) and we found 2 male and 2 female patients. Mean follow up was 8,5 years (range 3-15 years). Their medical, surgical, and familiar history was unremarkable.

Three patients (cases 2-4) presented with progressive painless swelling, and one patient referred pain (case 1). Intraorally, a hard swelling due to buccal cortical expansion was palpated. The overlying mucosa was intact, and absence of the involved teeth was noticed.

Diagnostic workup included preoperative orthopantomography and CT. A multilocular radiolucent cystic lesion with included teeth (Figures 1 and 2) was noticed. The CT dem-

Table I. Literature research showing 9 publications regarding ameloblastic fibroma case reports.

Author	Year	Number of patients	Age	Location	Treatment	Follow up
Vasconcellos y cols. ²	2015	1	6	Mandible	Excision and curettage	No recurrence, 2 years follow up
Khande y cols. ¹⁰	2019	1	11	Mandible	Enucleation	No recurrence, 1 year follow up
De Campos y cols. ¹¹	2019	1	11	Mandible	Enucleation	No recurrence, 12 year follow up
Sanadi y cols. ⁷	2019	1	21	Mandible	Segmental resection with 1 cm margin and IAN preservation	No recurrence, 15 months follow up
Cieliszka y cols. ¹²	2018	1	4	Maxilla	Enucleation	No recurrence, 1 year follow up
Carroll y cols. ⁸	2019	1	6	Mandible	Enucleation + iliac crest graft	No recurrence, 10 months follow up
Ealla y cols. ¹³	2015	1	2	Maxilla	Curettage	No report
Ferrazzano y cols. ¹⁴	2018	1	12	Mandible	Enucleation assisted by endoscopy	No recurrence, 6 months follow up
Kumar y cols. ¹⁵	2018	1	15	Mandible	Enucleation and curettage	No report
Tozoglu y cols. ¹⁶	2016	1	38	Mandible	Enucleation and curettage	6 months
Whitson y cols. ⁹	2020	1	9	Mandible	Marsupialization and curettage	6 months
Arora y cols. ¹⁷	2015	1	3	Maxilla	Enucleation	No report

Table II. Cases of ameloblastic fibroma operated at our department in the last 15 years.

Case	Age	Location	Surgery	Recurrence	Follow up
1	5 years	Mandible (ramus and angle)	Drainage (marsupialization) and enucleation and curettage 4 months later	No	3 years
2	13 years	Maxilla (left)	Enucleation and curettage	No	7 years
3	5 years	Maxilla (left)	Enucleation and curettage	No	15 years
4	11 years	Mandible (symphysis)	Enucleation and curettage	No	10 years

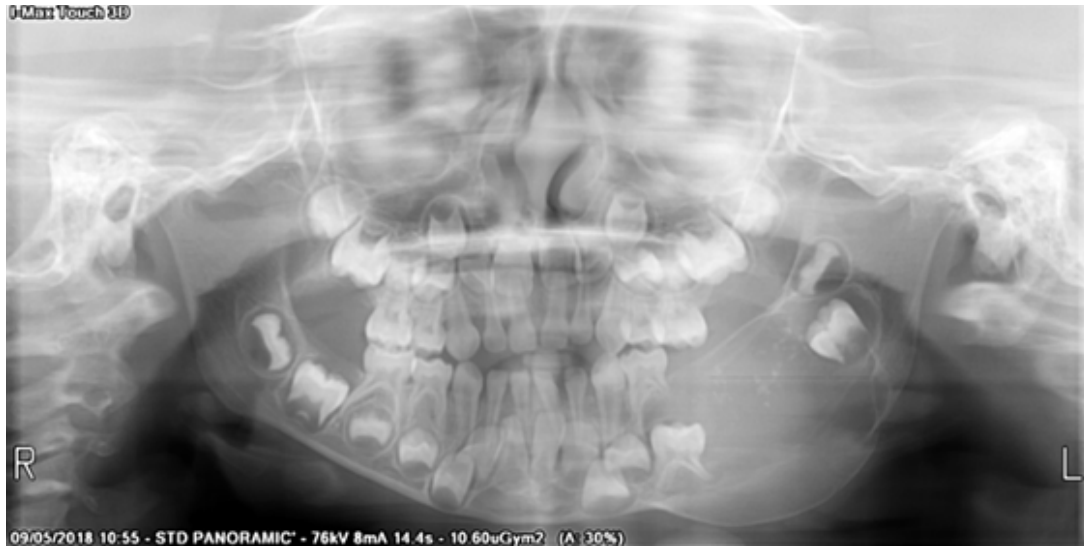

Figure 1. Ameloblastic fibroma in the left mandibular body and angle. A cystic lesion with impacted teeth (75) and cortical expansion is seen.

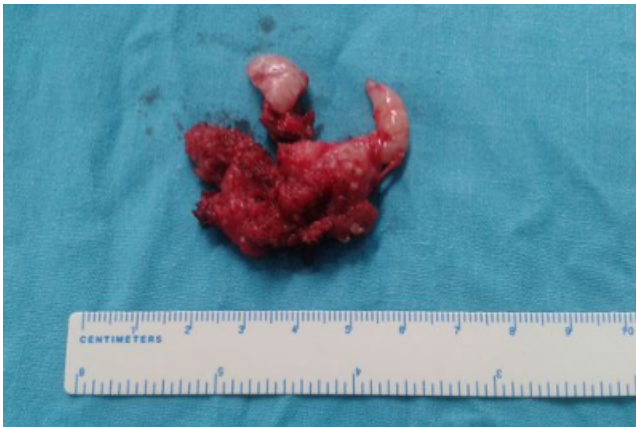

Figure 2. Surgical specimen of an ameloblastic fibroma showing a solid mass with areas of smooth surface. Grossly, ameloblastic fibroma appears as firm, lobular soft tissue mass with a smooth surface.

onstrated a well-circumscribed heterogenous cystic lesion showing areas of density similar to liquid and others similar to soft tissue. These lesions showed an expansive behavior with cortical thinning and calcifications, with teeth inclusion.

A biopsy was performed in all cases and, in the case where the patient referred pain as well (case 1), a drainage was placed for marsupialization to alleviate intralesional pressure and pain. The biopsy confirmed the diagnosis of ameloblastic fibroma.

All patients underwent enucleation through an intraoral vestibular approach and curettage of the surrounding bone under general anesthesia. The teeth involved were also extracted. The patient that underwent marsupialization presented with infection of the surgical wound, which resolved with intravenous antibiotics (amoxicillin – clavulanic 875 mg/8 h for 7 days) and underwent enucleation and curettage of the amelo-

blastic fibroma four months later during her hospital stay (case 1). Also, a CT was performed, which showed an overall moderate reduction of the size of the lesion after marsupialization.

Histological examination showed a mass made of mesenchymal and epithelial components of odontogenic origin. The mesenchymal part showed primitive connective tissue that resembled the dental papilla with variable cellular density. On the other hand, the epithelial component consisted of cords and islands bordered by two tight layers of parallel columnar cells in a palisading pattern with nuclei in reverse polarity, confirming the diagnosis of ameloblastic fibroma (Figure 3).

After a mean of 8,5 years of clinical and radiological follow up, there was no evidence of recurrence in all patients, and the surgical defects were filled with bone in all cases (Figure 4).

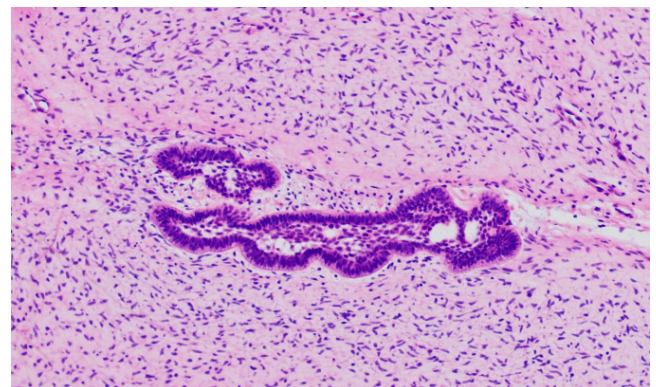


Figure 3. Histological image shows a cell-rich mesenchymal component that resembles dental papilla. In the middle two strands of odontogenic epithelium with parallel layers of hyperchromatic cuboidal to columnar cells with a palisading pattern in reversed polarity.

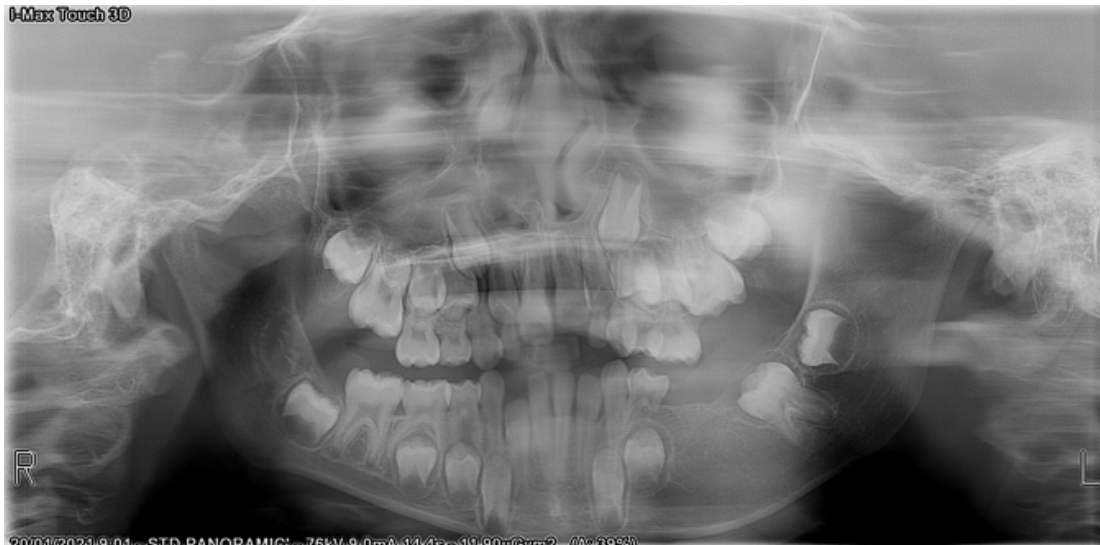

Figure 4. The same patient as in Figure 1, 28 months after surgery. Satisfactory bone filling is observed.

Patients underwent orthodontic treatment without incident and facial symmetry was satisfactorily restored. None of the patients required further surgery.

DISCUSSION

Ameloblastic fibromas are benign tumors defined by the WHO in their latest 2017 classification as mixed epithelial and mesenchymal odontogenic tumours¹⁸. These tumours are composed of both epithelial and mesenchymal elements and may show varied degrees of inductive change with formation of dental hard tissues. In this recent edition, some previously poorly defined lesions have been removed, including the ameloblastic fibro-dentinoma and ameloblastic fibro-odontoma, which are probably developing odontomas¹⁹.

Its histological features are characteristic but not specific since they may also be seen in an early developing (non-calcifying) odontoma²⁰. Previously, if dentine was seen, the lesions were considered ameloblastic fibrodentinoma, and if dentine and enamel were noted, the lesion was named ameloblastic fibro-odontoma. However, these characteristics are indistinguishable from a developing odontoma, and it is considered that if lesions were left, they would continue to mature into fully calcified lesions¹⁹.

Up to 20 % of cases are incidentally detected upon review of routine dental radiograph³. However, most patients generally present with painless swelling of the jaw and the lesion may affect the normal eruption of teeth in the area. An impacted tooth may be associated with the tumor in approximately three quarters of the cases³. Hence, it is why it is often confused with ameloblastoma and dentigerous cyst and can be distinguished histologically by the presence of myxoid appearance of connective tissue²⁰.

Radiographically, ameloblastic fibromas are unilocular lesions, occasionally multilocular when larger, with smooth well-demarcated borders³. AF has no specific radiologic signs

and consists in generally unilocular, scarcely multilocular lesions that can mimic the scalloped outlines of unilocular ameloblastoma and the soap bubble appearance of multilocular ameloblastoma. It produces expansion of the cortical bone. Surgical excision and/or thorough curettage with removal of affected teeth is the gold standard treatment.

It is necessary to distinguish ameloblastic fibroma from ameloblastoma and ameloblastic fibrosarcoma since these later two can be locally aggressive and have greater potential for recurrence. Clinically, ameloblastic fibroma usually occurs at a younger age than ameloblastoma. Radiographic examination does not contribute to the differential diagnosis. Ameloblastic fibroma lacks specific radiological signs and generally consists in unilocular or multilocular lesions that can mimic either the unilocular ameloblastoma or the soap bubble appearance of multilocular ameloblastoma on orthopantomography. Histological examination will usually confirm the diagnosis. Ameloblastic fibroma requires a long-term follow-up due to its chances of recurrence or its transformation into ameloblastic fibrosarcoma, but there is varied rate of recurrence by different authors and mostly attributed to incomplete primary removal¹⁵.

Also, ameloblastic fibroma exhibits a more indolent clinical course than ameloblastoma and does not tend to infiltrate among trabeculae of bone. It also tends to separate from the bone more readily. Therefore, it can be treated more conservatively than ameloblastoma, and the same was advocated in our cases with complete enucleation of the tumor along with the removal of impacted teeth and posterior curettage of the surrounding bone.

This lesion is considered a benign lesion; however, recent reports have suggested that it has the potential for recurrence and malignant transformation, the ameloblastic fibrosarcoma⁶. Therefore, some authors have advocated a more aggressive approach of recurrent ameloblastic fibroma²¹. Regardless of the form of treatment, patients with this tumor must be followed up for a long period to enable the early detection of possible recurrence or development of ameloblastic fibrosarcoma.

In our research, we found 12 case reports of ameloblastic fibroma of the jaws. All articles were single case reports, which emphasizes the peculiarity of this entity. Most of the cases (75 %) were located in the mandible, in line with previous reports, and all cases were associated to impacted teeth. Enucleation and curettage were the most frequent surgical treatment applied. However, Sanadi et al.⁷ performed a marginal resection with a safe 1cm margin and preservation of the IAN due to concerns about recurrence. Also, Whitson et al.⁹ performed marsupialization in their case, with posterior curettage and no recurrence in their 6-months follow up. In most articles, the mean follow-up was short (between 6-12 months) and only one article¹¹ reported a 12 year follow up. No recurrences were reported in any of the articles.

In our series we found 50 % of cases located in the maxilla, a higher rate compared to the literature, however, the size of the study is very limited. The mean age was 8.5 years, in line with previous reports where this lesion mostly presents in the first two decades of life. The most frequent symptom was a slowly progressive swelling, and one of them also referred pain. All four lesions showed a cystic multilocular heterogeneous appearance on orthopantomography, which was confirmed on CT examination. Histology established the definitive diagnosis.

In all cases, enucleation of the lesion and curettage of the surrounding bone was performed, including extraction of the involved teeth. One patient (case 1) underwent marsupialization which demonstrated to reduce the size of the lesion. However, it is not a established treatment of this entity and it was performed to alleviate pain and was followed by enucleation and curettage 4 months later. None of the patients showed recurrence at the longest follow up (mean 8,5 years, 15 years the longest follow up) and all four patients showed satisfactory bone filling and restoration of facial symmetry. Patients underwent orthodontic treatment uneventfully, at least 18 months after surgery.

As limitations to this study the number of patients is low due to the low frequency of this lesion. Further studies with bigger series and longer follow-up are needed to establish recurrence rates and the risk of malignant transformation.

CONCLUSIONS

Ameloblastic fibroma is an extremely rare entity that usually appears in the mandible in young patients and can be managed in a conservative way through enucleation and curettage, with good results. In our series we did not find any recurrences and facial symmetry was restored satisfactorily.

PUBLICATION ETHICS

The authors confirm that they have the informed consent of the patients.

CONFLICT OF INTEREST

None.

FUNDING

None.

REFERENCES

- Cohen DM, Bhattacharyya I. Ameloblastic fibroma, ameloblastic fibro-odontoma, and odontoma. *Oral Maxillofac Surg Clin North Am.* 2004;16(3):375-84. DOI: 10.1016/j.coms.2004.03.005.
- de Vasconcellos SJ de A, de Santana Santos T, Vaez SC, Piva MR, Martins-Filho PRS. Massive Ameloblastic Fibroma Treated With Surgical Conservative Treatment. *Journal of Craniofacial Surgery.* 2015;26(3):999-1000. DOI: 10.1097/SCS.0000000000001669.
- Nelson BL, Folk GS. Ameloblastic fibroma. *Head Neck Pathol.* 2009;3(1):51-3. DOI: 10.1007/s12105-008-0091-0.
- Cieliszka C, Galmiche-Rolland L, Khonsari RH. Early presentation in ameloblastic fibroma. *J Stomatol Oral Maxillofac Surg.* 2020;121(1):95-7. DOI: 10.1016/j.jormas.2019.04.015.
- Munde A, Karle R, Kale U. Ameloblastic fibroma in one-year-old girl. *J Oral Maxillofac Pathol.* 2013;17(1):149. DOI: 10.4103/0973-029X.110734.
- Ponnam S, Srivastava G, Smitha B. Ameloblastic fibroma. *J Oral Maxillofac Pathol.* 2012;16(3):444-5. DOI: 10.4103/0973-029X.102515.
- Sanadi A, Shah S, Golgire S, Shetty S. Highly proliferative ameloblastic fibroma: A rare entity. *Contemp Clin Dent.* 2018;9(4):656-8. DOI: 10.4103/ccd.ccd_637_18.
- Carroll C, Gill M, Bowden E, Ed O'Connell J, Shukla R, Sweet C. Ameloblastic fibroma of the mandible reconstructed with autogenous parietal bone: Report of a case and literature review. *Case Rep Dent.* 2019;2019:5149219. DOI: 10.1155/2019/5149219.
- Whitson E, Kim E, Youngblood D, Lubetsky S. Pediatric Ameloblastic Fibroma: A Case Report. *J Contemp Dent Pract.* 2020;21(3):322-5. DOI: 10.5005/jp-journals-10024-2780.
- Khande K, Mograwala H, Halli R, Hebbale M. Ameloblastic fibroma mimicking dentigerous cyst: A diagnostic dilemma. *Ann Maxillofac Surg.* 2019;9(1):201-4. DOI: 10.4103/ams.ams_194_17.
- de Campos W, Esteves C, Paiva G, Zambon C, Rocha A, Lemos C. Successful management of a gigantic ameloblastic fibroma: A 12-year follow-up. *Ann Maxillofac Surg.* 2019;9(1):197-200. DOI: 10.4103/ams.ams_268_18.
- Cieliszka C, Galmiche-Rolland L, Khonsari RH. Early presentation in ameloblastic fibroma. *J Stomatol Oral Maxillofac Surg.* 2020;121(1):95-7. DOI: 10.1016/j.jormas.2019.04.015.
- Ealla KKR, Basavanapalli VR, Velidandla SR, Manikya S, Ragulakollu R, Danappanavar PM, et al. Ameloblastic Fibroma of the Maxilla with Bilateral Presentation: Report of a Rare Case with Review of the Literature. *Case Rep Pediatr.* 2015;2015:250713. DOI: 10.1155/2015/250713.
- Ferrazzano GF, Coda M, Romano A, Dell'Aversana Orabona G, Califano L, Ingenito A, et al. Paediatric oral surgery: endoscopic approach in ameloblastic fibroma management. A preliminary report. *Eur J Paediatr Dent.* 2018;19(4):313-6.
- Kumar R, Bavle R, Srinath N, Umashankar D. Ameloblastic fibroma in a young adult. *Journal of Oral and Maxillofacial Pathology.* 2019;23(4):S63-5. DOI: 10.4103/jomfp.JOMFP_37_16.
- Tozoglu S, Hatipoglu M, Aytekin Z, Gurer EI. Extensive ameloblastic fibroma of the mandibula in a female adult patient: A case report with a follow-up of 3 years. *Eur J Dent.* 10(1):139-43. DOI: 10.4103/1305-7456.175700.
- Arora M, Dave A, Shetty V, Saluja P. Ameloblastic fibroma with ghost cell differentiation and calcification: A unique case report. *J Cancer Res Ther.* 11(4):1033. DOI: 10.4103/0973-1482.150436.

18. Slootweg PJ, El-Naggar AK. World Health Organization 4th edition of head and neck tumor classification: insight into the consequential modifications. *Virchows Archiv*. 2018;472(3):311-3. DOI: 10.1007/s00428-018-2320-6.
19. Speight PM, Takata T. New tumour entities in the 4th edition of the World Health Organization Classification of Head and Neck tumours: odontogenic and maxillofacial bone tumours. Vol. 472, *Virchows Archiv*. Springer Verlag; 2018. p. 331-9. DOI: 10.1007/s00428-017-2182-3.
20. Khande K, Mograwala H, Halli R, Hebbale M. Ameloblastic fibroma mimicking dentigerous cyst: A diagnostic dilemma. *Ann Maxillofac Surg*. 2019;9(1):201-4. DOI: 10.4103/ams.ams_194_17.
21. Munde A, Karle R, Kale U. Ameloblastic fibroma in one-year-old girl. *J Oral Maxillofac Pathol*. 2013;17(1):149. DOI: 10.4103/0973-029X.110734.