




## Revista Española de Cirugía Oral y Maxilofacial

[www.revistacirugiaoralmxilofacial.es](http://www.revistacirugiaoralmxilofacial.es)



### Original

# Spatial relationship between mandibular third molar and the mandibular canal in cone beam computed tomography. A cross-sectional descriptive study

David Ismael Bravo Anchundia<sup>\*1</sup> and Leonardo Flavio Cabrera Maldonado<sup>2</sup>

<sup>1</sup>Faculty of Dentistry. University of Cuenca, Ecuador. <sup>2</sup>Oral surgery at the Faculty of Dentistry of University of Cuenca, Ecuador

#### INFORMACIÓN DEL ARTÍCULO

Historia del artículo:

Recibido: 14 de noviembre de 2024

Aceptado: 15 de enero de 2025

Keywords:

Mandibular nerve, cone-beam computed tomography, third molar, mandible.

#### A B S T R A C T

**Background:** The spatial relationship between the mandibular canal and the third molar is the three-dimensional position of the mandibular canal with respect to the third molar and is a risk indicator for an injury to the neurovascular bundle in third molar extraction. The aim of this study was to determine the prevalence of the spatial relationship between the mandibular canal and the third molar.

**Material and methods:** A descriptive cross-sectional study was carried out, which evaluated the CBCT files of the anonymized database of the Department of Imaging of the Faculty of Dentistry of the University of Cuenca (Ecuador) within the period 2017-2023. The CBCTs that met the selection criteria were statistically analyzed according to the spatial relationship variable. The CBCTs were examined by the same observer after calibration by a specialist in Dental and Maxillofacial Imaging.

**Results:** 325 lower third molars were evaluated. The highest prevalence of the spatial relationship between the lower third molar and the mandibular canal was the caudal relationship without contact in 32.0 %, followed by the lingual relationship in contact in 22.2 %, buccal in contact in 14.8 %, caudal in contact in 12.9 %, buccal without contact in 8.6 %, interradicular in contact in 6.8 %, lingual without contact in 1.5 % and intrarradicular in contact in 1.2 %. 28.9 % of the third molars presented branches of the mandibular canal.

**Conclusions:** The most prevalent spatial relationship between the mandibular canal and the third molar was the caudal relationship without contact.

\*Autor para correspondencia:

Correo electrónico: [dismaelbravo@gmail.com](mailto:dismaelbravo@gmail.com) (David Ismael Bravo Anchundia).

<http://dx.doi.org/10.20986/recom.2025.1581/2024>

1130-0558/© 2024 SECOM CyC. Publicado por Inspira Network. Este es un artículo Open Access bajo la licencia CC BY-NC-ND (<http://creativecommons.org/licenses/by-nc-nd/4.0/>).

## Relación espacial del conducto mandibular con el tercer molar en tomografías computarizadas de haz cónico. Un estudio descriptivo transversal

### R E S U M E N

#### Palabras clave:

Nervio mandibular, tomografía computarizada de haz cónico, tercer molar, mandíbula.

**Introducción:** La relación espacial entre el conducto mandibular y el tercer molar es la posición tridimensional del conducto mandibular con respecto al tercer molar y es un indicador de riesgo para una lesión al paquete vasculonervioso en la exodoncia del tercer molar. El objetivo de este estudio fue determinar la prevalencia de la relación espacial del conducto mandibular con el tercer molar.

**Métodos:** Se realizó un estudio descriptivo transversal, el cual evaluó los archivos de tomografías computarizadas de haz cónico (CBCT) de la base de datos anonimizada del Departamento de Imagenología de la Facultad de Odontología de la Universidad de Cuenca (Ecuador) dentro del periodo 2017-2023. Las CBCT que cumplieron con los criterios de selección fueron analizadas estadísticamente de acuerdo con la variable relación espacial. Las CBCT fueron examinadas por el mismo observador previa calibración por una especialista en imagenología dental y maxilofacial.

**Resultados:** Se evaluaron 325 terceros molares inferiores. La mayor prevalencia de la relación espacial entre el tercer molar inferior y el conducto mandibular fue la relación caudal sin contacto en el 32,0 %, seguido de la relación lingual en contacto en el 22,2 %, bucal en contacto en el 14,8 %, caudal en contacto en el 12,9 %, bucal sin contacto en el 8,6 %, interradicular en contacto en el 6,8 %, lingual sin contacto en el 1,5 % e intraradicular en contacto en el 1,2 %. El 28,9 % de los terceros molares presentó conductos aberrantes.

**Conclusiones:** La relación espacial más prevalente entre el conducto mandibular y el tercer molar fue la relación caudal sin contacto.

### INTRODUCTION

The spatial relationship between the mandibular canal and the third molar is a risk indicator for an injury to the inferior alveolar nerve during tooth extraction<sup>1</sup>. It is defined as the three-dimensional position of the mandibular canal with respect to the third molar, which can be found in buccal, lingual, caudal, intraradicular and interradicular positions and in contact or not with the dental structure<sup>2-4</sup>. Sklavos et al.<sup>5</sup> evaluated in cone beam computed tomography (CBCT) the degree of compression measured at the point of maximum compression between third molar roots and mandibular canal. They found that patients who had a degree of compression where the diameter decreased by a 75 % or greater had increased risk of a postoperative inferior alveolar nerve injury and accounted for 52.17 % of all inferior alveolar nerve injuries. Besides, Klatt et al.<sup>6</sup> found that caudal relationship in contact was associated with the highest risk of a temporal neurological damage. It has been reported that the injury to the inferior alveolar nerve has an incidence of 1.1 % at 7 days after third molar surgery, while the involvement in a time greater than 6 months is 0.5 %<sup>7</sup>.

Panoramic radiography is the standard imaging test for preoperative evaluation of lower third molar surgery. However, being a two-dimensional radiograph, it may have limitations in assessing the spatial relationship when the mandibular canal is in intimate contact with the third molar<sup>8,9</sup>. CBCT has

greater sensitivity than panoramic radiography for detecting exposure of the inferior alveolar nerve during surgery, with intimate contact with loss of cortical bone of the mandibular canal being the most commonly associated sign. CBCT has a sensitivity of 95.1 % and a specificity of 64.4 %, while panoramic radiography has a sensitivity of 73.9 % and a specificity of 24.8 %<sup>10</sup>. Although neurosensory deficit does not simply occur after exposure of the neurovascular bundle, it increases the risk of injury to the inferior alveolar nerve<sup>11,12</sup>. An incidence of sensory disturbance of 20% has been reported after 7 days in cases where there is exposure of the neurovascular bundle<sup>12</sup>.

Detecting the mandibular canal on panoramic radiographs can be a challenge for the clinician, especially in its anterior and middle section<sup>13,14</sup>. Even on CBCT, it has been reported that it could not be detected in 18 % of cases at the level of the first molar. The cortex of the mandibular canal may vary according to the degree of bone density within the mandibular body, which can make its evaluation difficult<sup>15</sup>.

The effective dose represents the radiosensitivity of each organ, that is the risk of tissue damage by ionizing radiation, and allows us to estimate stochastic risks and compare different technologies and procedures<sup>16</sup>. The effective dose from CBCT is generally higher than intraoral and panoramic radiography but lower than conventional computed tomography (CT) and it is dependent on equipment type and exposure parameters, especially the field of view selected<sup>16</sup>.

The mandibular canal may present bifid canals along its course. This anatomical variant of the mandibular canal may be formatted by a partial fusion of independent canals present at mandible during latter half of the prenatal period<sup>17-19</sup>. However, it is necessary to clarify the mechanism of forming such anatomical variant<sup>18</sup>. A meta-analysis has reported the prevalence of bifid canals in 16 % of patients on computed tomography (CT) and CBCT<sup>20</sup>. In contrast, several studies with CT and CBCT have demonstrated a high frequency of bifid canals per patient with reports of 9.8 % to 66.5 %<sup>21</sup>. Its clinical relevance lies in the difficulty to detect it with two-dimensional radiographs and has two clinical implications: potential failure to achieve local anesthesia and surgical injuries to the neurovascular bundle<sup>20,22</sup>.

The spatial relationship of the mandibular canal with the third molar is an important factor in a presurgical evaluation, because it can intervene in a potential risk of injury to the inferior alveolar nerve. The present investigation aimed to determine the prevalence of the spatial relationship between the mandibular canal and the third molar in CBCT in the population investigated.

## MATERIAL AND METHODS

### Study design and population

The present observational, descriptive, cross-sectional study evaluated the cone beam computed tomography (CBCT) scans from the anonymized database of the Department of Imaging of the Faculty of Dentistry of the University of Cuenca (Ecuador) within the period May 2017-January 2023 of patients which were referred to Department of Imaging requiring CBCT imaging as part of their dental treatment. During this period, the universe was composed of 1092 CBCT files.

### Ethical approval

The present study was approved by the Research Directorate of the Faculty of Dentistry (DIFO) of the University of Cuenca (Ecuador). This study was conducted in accordance with the ethical foundations of research on human beings based on the Declaration of Helsinki of the WMA (World Medical Association)<sup>21</sup>. The database was anonymized to preserve the confidentiality of the data obtained and the patient's anonymity, to this end, the CBCTs were assigned a code and the information was recorded in digital files that were only accessible to the authors of the study. No data was provided that would allow the patient to be identified. In addition, each patient signed an informed consent prior to being treated at the Faculty of Dentistry.

### Eligibility criteria

Inclusion criteria: CBCT corresponds to the Department of Imaging between the period 2017-2023 that shows the mandibular canal and the uni or bilateral lower third molars with complete root formation or in the formation of the apical root third (Nolla stage 9).

Exclusion criteria: Repeated CBCT; pathology in the third molar and the posterior mandibular region; existence of a foreign body artifact such as titanium plates, orthodontic appliances, implants, amalgams, and dental prostheses; motion artifacts; poor quality in CBCT; hypodense trabecular bone that makes it impossible to observe the mandibular canal; a third molar with an abnormal shape and root remains of the third molar which difficult recognize the third molar.

### Study method

The CBCT files were evaluated through the i-Dixel Version 6.4.0.5 program. The spatial relationship variable was analyzed in the study population by a single observer after calibration by a specialist in Dental and Maxillofacial Imaging. The Microsoft Excel Version 2102 program was used to record the variables, and the SPSS Statistics Version 22 program was used for the statistical analysis. The CBCT code, right and left side, spatial relationship variable and technical parameters: field of view (FOV) and voxel size were recorded in the Microsoft Excel Version 2102 program. In the registry of variables, the qualitative value of the spatial relationship was noted, therefore, for each position in the buccolingual direction, the distance was described as contact or no contact. In the case of detecting branches of the mandibular canal at the level of the third molar in the transaxial slices, the number and spatial relationship with the third molar were noted. In the statistical analysis, the prevalence (the percentage of each case) and the frequency (the number of each case) were obtained.

### Calibration and inter-rater reliability

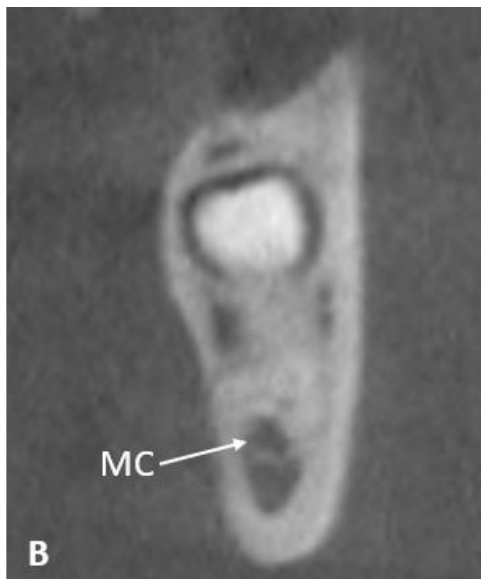
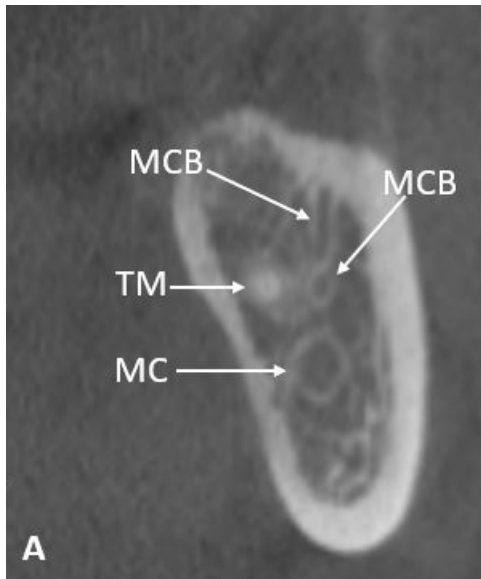
To avoid inter-observer differences, all CBCTs were evaluated by the same observer. The observer was calibrated by a specialist in Dental and Maxillofacial Imaging to identify the mandibular canal and its relationship to the third molar using the i-Dixel program Version 6.4.0.5, in CBCTs that were not included in the study. The degree of inter-observer agreement was obtained using Cohen's Kappa index using the SPSS Statistics program Version 22. A high agreement was found in the buccolingual position of the mandibular canal with the third molar (Kappa = 0.87) and in the distance (Kappa = 1.0) between the two investigators, which suggests that the observer was able to analyze the experimental CBCTs.

### Study variables

The radiographic variable analyzed in the CBCT files was the spatial relationship, which is a polychotomous nominal qualitative variable. Spatial relationship is composed by the buccolingual direction and the distance between the mandibular canal and the tooth structure (Figure 1). The operational definitions of the study variables are described below, obtained through a literature review<sup>2-4,23</sup>.

**Buccal:** The mandibular canal is partially or completely in a buccal position to the dental structure during its journey by the third molar.

**Lingual:** The mandibular canal is partially or completely lingual to the tooth structure during its journey by the third molar.



**Figure 1. A:** mandibular canal (MC) in caudal position without contact with the third molar (TM), mandibular canal branches at the level of the third molar (MCB). **B:** mandibular canal in interradicular position in contact with the third molar.

**Caudal:** The entire mandibular canal is located below the tooth structure along the entire journey with the third molar.

**Interradicular:** The mandibular canal is located between the roots of the tooth.

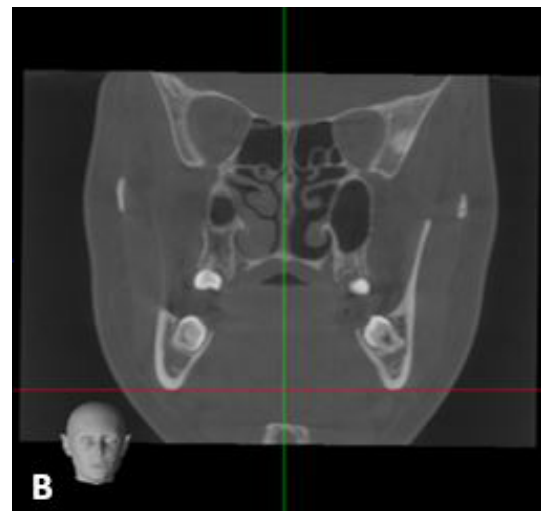
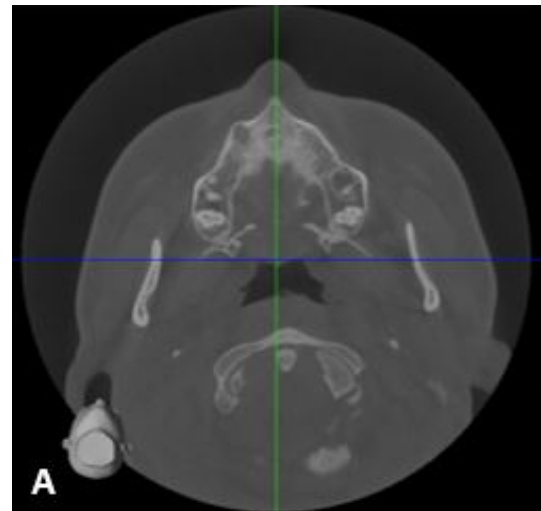
**Intraradicular:** The mandibular canal passes between converging roots fused at the apex.

**Contact:** There is no bone between the mandibular canal and the third molar, interruption of the cortex is observed at some point along its journey with the third molar.

**No contact:** There is bone between the mandibular canal and the third molar, the cortex is preserved without interruptions along the entire journey with the third molar.

## Observation method

Images were obtained using a CBCT unit (3D Accuitomo 170, J. Morita, Kyoto, Japan). The i-Dixel software Version 6.4.0.5 was used as the observation tool. Images were evaluated with a slice thickness of 0.1 mm and a slice interval of 0.5 mm. To describe the different spatial relationships of the mandibular canal with the third molar, the direct observation technique was applied to the CBCTs. The observation method was standardized as follows; contrast and brightness were modified to visualize the mandibular canal and the third molar using the BONE 2 option in the Contrast and Color Presets. The position of the anterior nasal spine was evaluated in the axial slices to establish the midsagittal plane, then the third molars were located in the coronal plane and the lower basal edge was aligned with the reference line of the axial section (Figure 2). The cervical region of the mandibular teeth was located in the axial slices.



**Figure 2. A:** evaluation of the anterior nasal spine to establish the midsagittal plane. **B:** center the third molars and match the lower basal edge with the reference line of the axial section.

The dual-CMPR module was selected and then the option Draw an MPR spline on the axial slice was selected in Tools. This was started on the right side (if applicable). A curve was drawn using points, starting at the posterior and middle of the mandibular ramus, then equidistant points were drawn between the cortical plates at the level of the mandibular molars and continuing to the midline. The process was repeated on the left side by again selecting the option Draw an MPR spline on the axial section. After drawing the curve, the

transaxial slices of the bilaterally delimited area were automatically generated (Figure 3).

To determine the right or left side was used the reference line on the coronal slices. The transaxial images was evaluated with a slice thickness of 0.1 mm with a slice interval of 0.5 mm. The mandibular canal was recognized as a corticalized hypodense tubular structure in the transaxial slice<sup>15</sup>. The dental structure is observed as a hyperdense image. Through the transaxial slices were established the relationship of the dental canal with the third molar and whether or not it is in contact.

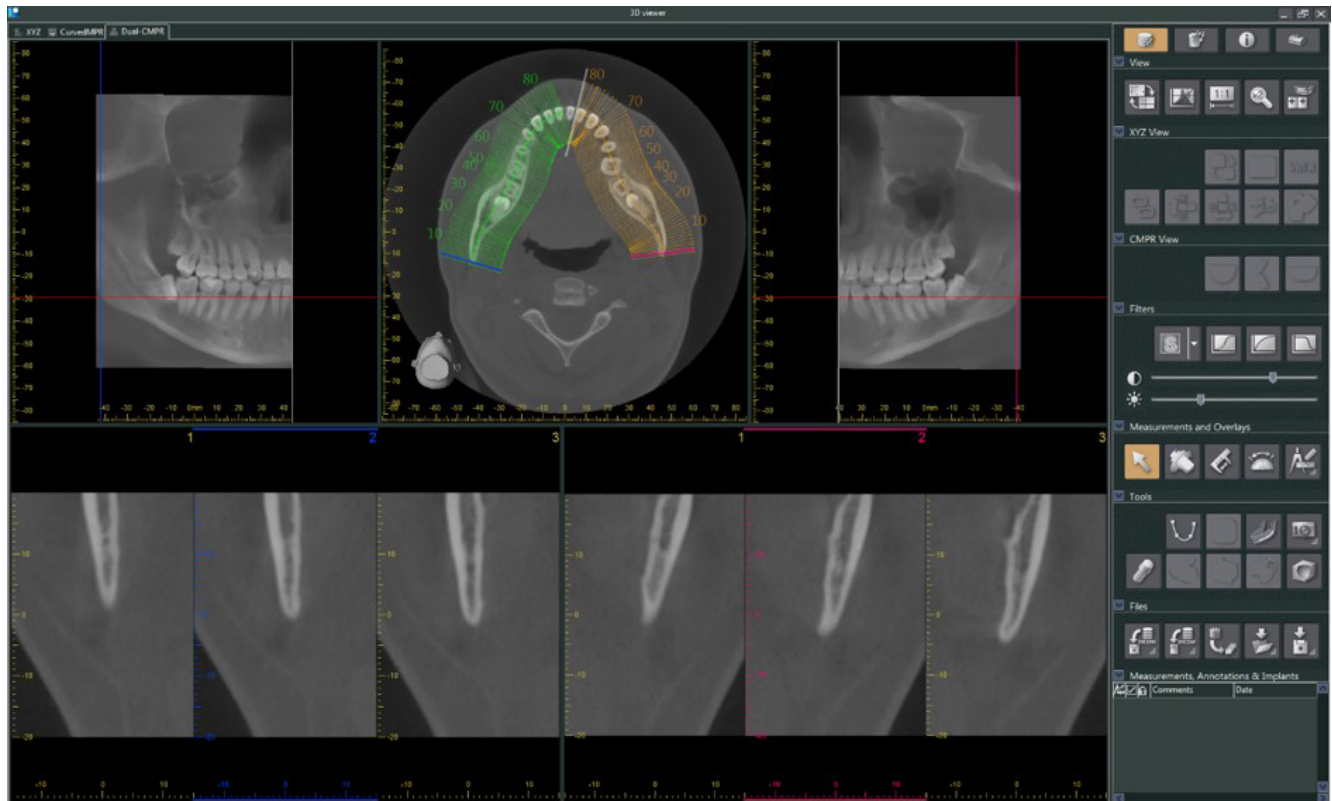


Figure 3. View of the dual-CMPR module showing the transaxial sections of the bilaterally delimited area.

## RESULTS

### *Prevalence of the spatial relationship of the mandibular canal with the third molar*

The universe was composed of 1092 CBCT files. According to the eligibility criteria, the study population comprised 199 CBCT Files. No calculation of the study sample size was performed. In total, 325 lower third molars were evaluated, where 51.4 % were lower right third molars and 48.6 % were lower left third molars. The technical parameters were: FOV of 170 x 120 mm and the voxel size of 0.33 mm in most of the CBCTs analyzed.

The highest prevalence of the spatial relationship between the lower third molar and the mandibular canal was the caudal

relationship without contact in 32.0 % ( $n = 104$ ), followed by the lingual relationship in contact in 22.2 % ( $n = 72$ ), buccal in contact in 14.8 % ( $n = 48$ ), caudal in contact in 12.9 % ( $n = 42$ ), buccal without contact in 8.6 % ( $n = 28$ ), interradicular in contact in 6.8 % ( $n = 22$ ), lingual without contact in 1.5 % ( $n = 5$ ) and intraradicular in contact in 1.2 % ( $n = 4$ ). Furthermore, mandibular third molars were found in contact with the mandibular canal in 57.8 % and without contact in 42.4 % (Table I, Figure 4). In the interradicular and intraradicular spatial relationship, the canal was always found in contact with the third molar.

Another imaging finding was the presence of mandibular canal branches in 28.9 % at the level of third molars, where 27.7 % of the cases presented bifid mandibular canal, while 1.2 % presented trifid mandibular canal. The highest prevalence of the spatial relationship of the mandibular canal branch with the third molar was the buccal relationship

Table I. Prevalence of the spatial relationship between the mandibular canal and the third molar.						
Buccolingual relationship	Contact	Percentage	No contact	Percentage	Total	Percentage
Caudal	42	12.9 %	104	32.0 %	146	44.9 %
Lingual	72	22.2 %	5	1.5 %	77	23.7 %
Buccal	48	14.8 %	28	8.6 %	76	23.4 %
Interradicular	22	6.8 %	0	0.0 %	22	6.8 %
Intraradicular	4	1.2 %	0	0.0 %	4	1.2 %
Total	188	57.8 %	137	42.2 %	325	100.0 %

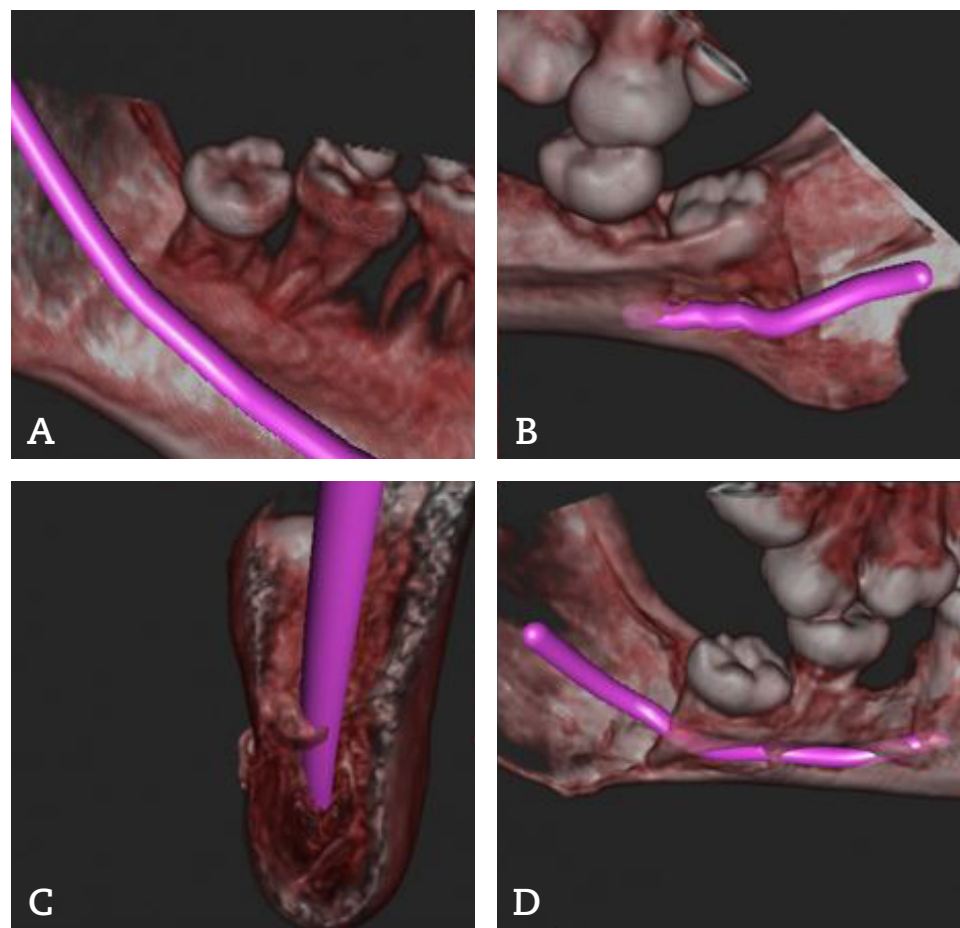


Figure 4. Three-dimensional reconstruction of the mandibular canal path with the third molar.  
A: spatial relationship in a caudal direction without contact. B: spatial relationship in a lingual direction in contact.  
C: spatial relationship in a buccal direction in contact. D: spatial relationship in an intraradicular direction.

without contact in 22.5 % (n = 22), followed by the cranial relationship without contact in 20.4 % (n = 20), caudal in contact in 13.3 % (n = 13), buccal in contact in 12.2 % (n = 12), lingual in contact in 7.1 % (n = 7), cranial in contact in 5.1 % (n = 5), caudal without contact in 5.1 % (n = 5) and lingual without contact in 2.0 % (n = 2) (Table II).

The lower third molars were found without contact with the mandibular canal branches in 50 % (n = 49), while they

were found in contact in 37.7 % (n = 37) and observation of the path was impossible in 12.3 % (n = 12) of the cases due to loss of cortex of the canal, therefore it could not be determined whether or not it was in contact with the dental structure. Some branches of the mandibular canal were observed in the retromolar area towards the third molar; however, the route was not visualized due to the loss of the cortex of the canal (Table II).



Table II. Prevalence of the spatial relationship of mandibular canal branches with the third molar.

Buccolingual relationship	Contact		No contact		The path is not displayed		Total	Percentage
Buccal	12	12.2 %	22	22.5 %	0	0.0 %	34	34.7 %
Cranial	5	5.1 %	20	20.4 %	3	3.1 %	28	28.6 %
Caudal	13	13.3 %	5	5.1 %	0	0.0 %	18	18.4 %
Lingual	7	7.1 %	2	2.0 %	0	0.0 %	9	9.2 %
Retromolar zone	0	0.0 %	0	0.0 %	9	9.2 %	9	9.2 %
Total	37	37.7 %	49	50.0 %	12	12.3 %	98	100.0 %

## DISCUSSION

The spatial relationship of the third molar with the mandibular canal has been shown to have high variability, which may be due to the ethnicity of the patients and the size of the study population<sup>24,25</sup>.

Yamada et al.<sup>3</sup> in their CBCT investigation, evaluated the spatial relationship of 112 impacted third molars at the closest point to the mandibular canal from three examined areas and found that in 36.6 % of the cases, the mandibular canal was caudal in contact to the third molar. Lübbers et al.<sup>26</sup> evaluated 707 impacted third molars by CBCT and reported that in 52.8 % of the cases, the mandibular canal was buccal to the third molar. In both studies, to be part of the study population, the mandibular canal was overlapping on the third molar in panoramic radiographs and the preoperative CBCT was evaluated.

In the study by Wang et al.<sup>24</sup> 137 impacted third molars were evaluated in CBCT and found that in 60.6 % of the cases the mandibular canal was caudal without contact with the third molar. Quirino de Almeida Barros et al.<sup>27</sup> evaluated 173 thirds molars in CBCT, and found that in 28.3 % of the cases, the mandibular canal was mainly located caudal in contact with the third molar. In these studies, the study population were patients with impacted third molars.

Previous studies present limitations in the study methodology, such as non-specific operational definitions of study variables, lack of calibration and inter-observer reliability, and non-specific eligibility criteria. In addition, imaging studies of anatomical structures must have an observation method to align the CBCT in the same axial, sagittal and coronal plane. Further studies with homogeneity in methodology should be carried out.

In the present study, 325 third molars were evaluated in CBCT and the most prevalent spatial relationship of the mandibular canal with the third molar was the caudal relationship without contact in 32.0 % of the cases. Study population were patients in whom the reason for the radiological examination was unknown, which allows for internal validity at a local level. In the results of the present study most of the third molars were found in contact with the third molar, which is similar with the study by Yamada et al.<sup>3</sup>, Lübbers et al.<sup>26</sup> and Quirino de Almeida Barros et al.<sup>27</sup>.

Interruption of the mandibular canal cortex on CBCT, the interradicular and lingual position of the mandibular canal has been associated with intraoperative exposure of the inferior alveolar nerve during third molar surgery<sup>11,28</sup>. In the present study, it was demonstrated that in the intra and interradicular position, there was always direct contact between the third molar and the mandibular canal, while in the lingual position the majority of the cases were in contact.

Yamada et al.<sup>3</sup> found mandibular canal branches in 94.6 % of the cases at the level of third molars. In contrast, the present study found mandibular canal branches in 28.9 % of the cases at the level of third molars. This difference may be due to the ethnicity of the patients, operational definition of the study variables, size of the study population, selection criteria and voxel. Voxel size is an important factor for the recognition of mandibular canal branches. The smaller the voxel size, the better the resolution of CBCT, and the better the recognition of branches of the mandibular canal, thus there is a positive association between the prevalence of branches of the mandibular canal and the voxel size of a CBCT<sup>18</sup>. In the present study, the majority of CBCTs examined had a voxel size of 0.33 mm.

Preoperative assessment by computerized tomography or cone beam computed tomography is based on the presence of mandibular canal wall for its localization, which may be further affected by decreased bone trabeculation<sup>15</sup>. In the present study, it demonstrated the difficulty of evaluating branches of the mandibular canal due to the loss of the cortex, making it impossible to observe their course in 12.3 % of cases. Magnetic resonance imaging (MRI) is a valid alternative for preoperative assessment radiation-free of the inferior alveolar nerve and accessory inferior alveolar nerves<sup>29,30</sup>. Special "black bone" MRI sequences such as 3D Double Echo Steady State and 3D Short Tau Inversion Recovery sequences providing high-resolution and high-contrast images that allow simultaneous visualization of the inferior alveolar nerve tissue within osseous limits of the mandibular canal<sup>29,31,32</sup>. Besides, Al-Haj Husain et al.<sup>33</sup> demonstrated that in 3D Double Echo Steady State MRI, the observation of the entire course of nerve lingual from the foramen ovale to the mandibular third molar region was possible in 35 % of the cases. The decision to choose any imaging modality in mandibular third molar surgery has to be based on his indications, contraindications, limitations and their

respective advantages and disadvantages<sup>29</sup>. In recent years, deep learning-based evaluation had demonstrated high sensitivity and specificity for detection and evaluation of the spatial relationship between mandibular canal and third molar on CBCT images which could be utilized for preoperative planning<sup>34,35</sup>.

This study presents some limitations. First, the study universe was obtained from single database therefore further studies with homogeneity in methodology should be carried out. This study presents an observation method and operational definitions of the study variables that can be replicated for the investigation of the spatial relationship of the mandibular canal with the lower third molar. Second, gender and age were not investigated due to the database anonymization protocol. Third, It is not possible to conclude that the tubular bone structures arising from the mandibular canal contain branches of the inferior alveolar nerve. Finally, the present study evaluated mandibular canal branches that were found at the level of the third molar excluding those branches that were found only in the retromolar region and in front of the third molar, which could increase their prevalence.

## CONCLUSIONS

The most prevalent spatial relationship of the mandibular canal with the third molar was the caudal relationship without contact, in 32.0 % of the cases. However, most of the third molars were found in contact with the third molar, in 57.8 % of the cases. Anatomical variations of mandibular canal were found in 28.9 % of third molars only at the level of the third molars, presenting in most cases a bifid mandibular canal. Its most prevalent spatial relationship was the buccal relationship without contact. Most branches of the mandibular canal were found without contact with the third molar, and its complete visualization was impossible in 12.3 % of cases due to the loss of the cortex of the canal.

## CONFLICTS OF INTEREST

The authors declare that they have no conflicts of interest. This study received no funding.

## AUTHOR CONTRIBUTIONS

Leonardo Cabrera participated in the design of the study and the correction of the manuscript. David Bravo participated in the design of the study, study method, observation method, analysis of the results and in the writing of the manuscript. This research is based on the undergraduate research work of David Bravo.

## ACKNOWLEDGMENTS

The authors would like to acknowledge to specialist in Dental and Maxillofacial Imaging, Valeria Romero by her participated in the calibration and inter-rater reliability.

## REFERENCES

1. Smith WP. The relative risk of neurosensory deficit following removal of mandibular third molar teeth: The influence of radiography and surgical technique. *Oral Surg Oral Med Oral Pathol Oral Radiol.* 2013;115(1):18-24. DOI: 10.1016/j.oooo.2012.03.017.
2. Maglione M, Costantinides F, Bazzocchi G. Classification of impacted mandibular third molars on cone-beam CT images. *J Clin Exp Dent.* 2015;7(2):e224-31. DOI: 10.4317/jced.51984.
3. Yamada T, Ishihama K, Yasuda K, Hasumi-Nakayama Y, Ito K, Yamaoka M, et al. Inferior alveolar nerve canal and branches detected with dental cone beam computed tomography in lower third molar region. *J Oral Maxillofac Surg.* 2011;69(5):1278-82. DOI: 10.1016/j.joms.2010.07.010.
4. Kuntz NM, Schulze R. Three-Dimensional Classification of Lower Third Molars and Their Relationship to the Mandibular Canal. *J Oral Maxillofac Surg.* 2021;79(8):1611-20. DOI: 10.1016/j.joms.2021.02.033.
5. Sklavos A, Delpachitra S, Jaunay T, Kumar R, Chandu A. Degree of Compression of the Inferior Alveolar Canal on Cone-Beam Computed Tomography and Outcomes of Postoperative Nerve Injury in Mandibular Third Molar Surgery. *Journal of Oral and Maxillofacial Surgery.* 2021;79(5):974-80. DOI: 10.1016/j.joms.2020.12.049.
6. Klatt JC, Sorowka T, Kluwe L, Smeets R, Gosau M, Hanken H. Does a preoperative cone beam CT reduce complication rates in the surgical removal of complex lower third molars? A retrospective study including 486 cases. *Head Face Med.* 2021;17(1):1-11. DOI: 10.1186/s13005-021-00271-5.
7. Queral-Godoy E, Valmaseda-Castellón E, Berini-Aytés L, Gay-Escoda C. Incidence and evolution of inferior alveolar nerve lesions following lower third molar extraction. *Oral Surg Oral Med Oral Pathol Oral Radiol Endod.* 2005;99(3):259-64. DOI: 10.1016/j.tripleo.2004.06.001.
8. Al Ali S, Jaber M. Correlation of panoramic high-risk markers with the cone beam CT findings in the preoperative assessment of the mandibular third molars. *J Dent Sci.* 2020;15(1):75-83. DOI: 10.1016/j.jds.2019.08.006.
9. Baqain ZH, AlHadidi A, AbuKaraky A, Khader Y. Does the Use of Cone-Beam Computed Tomography Before Mandibular Third Molar Surgery Impact Treatment Planning? *J Oral Maxillofac Surg.* 2020;78(7):1071-7. DOI: 10.1016/j.joms.2020.03.002.
10. Reia VCB, de Toledo Telles-Araujo G, Peralta-Mamani M, Biancardi MR, Rubira CMF, Rubira-Bullen IRF. Diagnostic accuracy of CBCT compared to panoramic radiography in predicting IAN exposure: a systematic review and meta-analysis. *Clin Oral Investig.* 2021;25(8):4721-33. DOI: 10.1007/s00784-021-03942-4.
11. Bhardwaj P, Bhardwaj Y, Ram R, Parmar M, Ghezta N, Sinha A. Radiographic factors associated with inferior alveolar nerve exposure during mandibular third molar surgery and their influence on neurosensory deficit: A prospective study. *J Oral Biol Craniofac Res.* 2022;12(6):818-22. DOI: 10.1016/j.jobcr.2022.08.025.
12. Tay ABG, Go WS. Effect of exposed inferior alveolar neurovascular bundle during surgical removal of impacted lower third molars. *J Oral Maxillofac Surg.* 2004;62(5):592-600. DOI: 10.1016/j.joms.2003.08.033.
13. Angelopoulos C, Thomas S, Hechler S, Parissis N, Hlavacek M. Comparison between digital panoramic radiography and cone-beam computed tomography for the identification of the mandibular canal as part of presurgical dental implant assessment. *J Oral Maxillofac Surg.* 2008;66(10):2130-5. DOI: 10.1016/j.joms.2008.06.021.
14. Kamrun N, Tetsumura A, Nomura Y, Yamaguchi S, Baba O, Nakamura S, et al. Visualization of the superior and inferior borders of the mandibular canal: A comparative study using digital panoramic radiographs and cross-sectional computed tomography images. *Oral Surg Oral Med Oral Pathol Oral Radiol.* 2013;115(4):550-7. DOI: 10.1016/j.oooo.2013.01.001.



15. de Oliveira-Santos C, Souza PHC, de Azambuja Berti-Couto S, Stinkens L, Moyaert K, Rubira-Bullen IRF, et al. Assessment of variations of the mandibular canal through cone beam computed tomography. *Clin Oral Investig*. 2012;16(2):387-93. DOI: 10.1007/s00784-011-0544-9.
16. European Commission. Radiation protection n° 172: Cone beam CT for dental and maxillofacial radiology. Evidence based guidelines. [Internet]. 2012. Available from: <https://op.europa.eu/s/z1d6>.
17. Chávez-Lomelí ME, Mansilla Lory J, Pompa JA, Kjær I. The human mandibular canal arises from three separate canals innervating different tooth groups. *J Dent Res*. 1996;75(8):1540-4. DOI: 10.1177/00220345960750080401.
18. Aung NM, Myint KK. Bifid Mandibular Canal: A Proportional Meta-Analysis of Computed Tomography Studies. *Int J Dent*. 2023;2023:1-23.
19. Shiozaki K, Fukami K, Kuribayashi A, Shimoda S, Kobayashi K. Mandibular lingual canals distribute to the dental crypts in prenatal stage. *Surgical and Radiologic Anatomy*. 2014;36(5):447-53. DOI: 10.1007/s00276-013-1201-6.
20. Haas LF, Dutra K, Porporatti A, Mezzomo LA, De Luca Canto G, Flores-Mir C, et al. Anatomical variations of mandibular canal detected by panoramic radiography and computed tomography: a systematic review and meta-analysis. *Dentomaxillofac Radiol*. 2016;45(2):1-12. DOI: 10.1259/dmfr.20150310.
21. von Arx T, Bornstein M. The bifid mandibular canal in three-dimensional radiography: morphologic and quantitative characteristics. *Swiss Dent J*. 2021;131(1):10-28. DOI: 10.61872/sdj-2021-01-01.
22. Claeyss V, Wackens G. Bifid mandibular canal: literature review and case report. *Dentomaxillofac Radiol*. 2005;34(1):55-8. DOI: 10.1259/dmfr/23146121.
23. Ghaeminia H, Meijer GJ, Soehardi A, Borstlap WA, Mulder J, Bergé SJ. Position of the impacted third molar in relation to the mandibular canal. Diagnostic accuracy of cone beam computed tomography compared with panoramic radiography. *Int J Oral Maxillofac Surg*. 2009;38(9):964-71. DOI: 10.1016/j.ijom.2009.06.007.
24. Wang WQ, Chen MYC, Huang HL, Fuh LJ, Tsai MT, Hsu JT. New quantitative classification of the anatomical relationship between impacted third molars and the inferior alveolar nerve. *BMC Med Imaging*. 2015;15:1-6. DOI: 10.1186/s12880-015-0101-0.
25. Liu ZL, Jiang ES, Cui LY, Li JX. Cone-Beam Computed Tomography Analysis on the Relationship between the Mandibular Third Molar and the Position of the Mandibular Canal in Koreans from the Yanbian Area and the Han People. *Int J Clin Pract*. 2023;2023:1-11. DOI: 10.1155/2023/9563476.
26. Lübbers HT, Matthews F, Damerau G, Kruse AL, Obwegeser JA, Grätz KW, et al. Anatomy of impacted lower third molars evaluated by computerized tomography: is there an indication for 3-dimensional imaging? *Oral Surg Oral Med Oral Pathol Oral Radiol Endod*. 2011;111(5):547-50. DOI: 10.1016/j.tripleo.2010.06.010.
27. Quirino de Almeida Barros R, Bezerra de Melo N, de Macedo Bernardino, Arêa Leão Lopes Araújo Arruda MJ, Meira Bento P. Association between impacted third molars and position of the mandibular canal: a morphological analysis using cone-beam computed tomography. *British Journal of Oral and Maxillofacial Surgery*. 2018;56(10):952-5. DOI: 10.1016/j.bjoms.2018.10.280.
28. Pippi R, Santoro M, D'Ambrosio F. Accuracy of cone-beam computed tomography in defining spatial relationships between third molar roots and inferior alveolar nerve. *Eur J Dent*. 2016;10(4):454-8. DOI: 10.4103/1305-7456.195168.
29. Al-Haj Husain A, Stadlinger B, Winklhofer S, Piccirelli M, Valdec S. Magnetic resonance imaging for preoperative diagnosis in third molar surgery: a systematic review. *Oral Radiol*. 2022;39(1):1-17. DOI: 10.1007/s11282-022-00611-4.
30. Beck F, Austerlmann S, Bertl K, Ulm C, Lettner S, Toelly A, et al. Is MRI a viable alternative to CT/CBCT to identify the course of the inferior alveolar nerve in relation to the roots of the third molars? 2021;25(6):3861-71.
31. Valdec S, Al-Haj Husain A, Winklhofer S, Müller M, Piccirelli M, Stadlinger B. Comparison of Preoperative Cone-Beam Computed Tomography and 3D-Double Echo Steady-State MRI in Third Molar Surgery. *J Clin Med*. 2021;10(20):4768. DOI: 10.3390/jcm10204768.
32. Al-Haj Husain A, Stadlinger B, Winklhofer S, Müller M, Piccirelli M, Valdec S. Mandibular Third Molar Surgery: Intraosseous Localization of the Inferior Alveolar Nerve Using 3D Double-Echo Steady-State MRI (3D-DESS). *Diagnostics (Basel)*. 2021;11(7):1245. DOI: 10.3390/diagnostics11071245.
33. Al-Haj Husain A, Valdec S, Stadlinger B, Rücker M, Piccirelli M, Winklhofer S. Preoperative visualization of the lingual nerve by 3D double-echo steady-state MRI in surgical third molar extraction treatment. *Clin Oral Investig*. 2022;26(2):2043-53. DOI: 10.1007/s00784-021-04185-z.
34. Liu MQ, Xu ZN, Mao WY, Li Y, Zhang XH, Bai HL, et al. Deep learning-based evaluation of the relationship between mandibular third molar and mandibular canal on CBCT. *Clin Oral Investig*. 2022;26(1):981-91. DOI: 10.1007/s00784-021-04082-5.
35. Chun SY, Kang YH, Yang S, Kang SR, Lee SJ, Kim JM, et al. Automatic classification of 3D positional relationship between mandibular third molar and inferior alveolar canal using a distance-aware network. *BMC Oral Health*. 2023;23(1):794. DOI: 10.1186/s12903-023-03496-9.