




Revista Española de
Cirugía Oral y
Maxilofacial

www.revistacirugiaoralmaxilofacial.es



Original

Analysis of skeletal growth and development in cleft lip and palate patients undergoing Delaire's functional surgery

Erita Cordero^{*1,2}, María Sáez³, Felipe Soto⁴, Alicia Laura⁵, Ana Alarcón^{1,2} and Roberto Pantoja^{1,2}.

¹Department of Oral and Maxillofacial Surgery. Faculty of Dentistry. University of Chile. Santiago, Chile. ²Department of Oral and Maxillofacial Surgery. San Borja Arriarán Hospital. Santiago, Chile. ³DDS. Faculty of Dentistry. University of Chile. ⁴Oral and Maxillofacial Surgery Resident. Faculty of Dentistry. University of Chile. Santiago, Chile. ⁵Department of Oral and Maxillofacial Surgery. Orthodontics and Dentofacial Orthopedics Unit. San Borja Arriarán Hospital. Santiago, Chile

ARTICLE INFORMATION

Article history:

Received: 13 de enero de 2025

Accepted: 17 de febrero de 2025

Keywords:

Cleft lip and palate, cheilorhinoplasty, veloplasty, palatoplasty, skeletal development, orthognathic surgery.

ABSTRACT

Objectives: The purpose of this article is to analyze the skeletal features and further treatment required by cleft lip and palate patients treated with Delaire's functional surgery during the years 2005-2010 at San Borja Arriarán Hospital in Santiago, Chile, focusing on the subsequent requirement for orthognathic surgery.

Patients and methods: An observational retrospective study included patients with cleft lip and palate undergoing Delaire's functional surgery, analyzing patients' clinical records, updated dental cast models, and cephalograms. Individuals meeting the inclusion criteria were classified according to diagnosis and later applied clinical and radiographic methods. Measurements of overjet and overbite were performed in available dental cast study models, along with the molar relationship according to Angle's classification. Furthermore, GOSLON Yardstick was applied to determine long-term occlusal prognosis and the ultimate requirement for secondary surgery.

Results: A sample of 30 patients was obtained. Regarding occlusal analysis, severe overbite alterations were not observed, while overjet exhibited predominantly negative measures; with bilateral cleft lip and palate corresponding to the most altered group. 10 patients (33%) were ultimately elected for orthognathic surgery, presenting average overjet of -0.13 mm and GOSLON Yardstick scores of 4-5. None cases for osteogenic distraccion.

Conclusions: Skeletal development observed in patients undergoing Delaire's functional surgery may be considered appropriate since it implies mild and moderate maxillary discrepancies. With 53.3 % of the individuals classified in GOSLON groups 1-3, proper occlusal relationships can be observed, allowing them to be successfully treated through an orthopedic approach.

*Correspondence:

E-mail: eritac@uchile.cl (Erita Cordero).

<http://dx.doi.org/10.20986/recom.2025.1596/2025>

1130-0558/© 2024 SECOM CyC. Publicado por Inspira Network. Este es un artículo Open Access bajo la licencia CC BY-NC-ND (<http://creativecommons.org/licenses/by-nc-nd/4.0/>).

Análisis de crecimiento y desarrollo esquelético de pacientes con fisuras labio palatinas operados mediante cirugía funcional de Delaire

R E S U M E N

Palabras clave:

Fisura labio palatina, queilorrinoplastia, veloplastia, palatoplastia, desarrollo esquelético, cirugía ortognática.

Objetivos: El propósito de este artículo es analizar las características esqueléticas y el tratamiento adicional requerido por los pacientes con fisuras labio palatinas tratados con la cirugía funcional de Delaire durante los años 2005-2010 en el Hospital San Borja Arriarán en Santiago, Chile, enfocándose en la necesidad subsecuente de cirugía ortognática.

Pacientes y métodos: Un estudio observacional retrospectivo incluyó a pacientes con labio y paladar hendido sometidos a DFS, analizando los registros clínicos de los pacientes, modelos de yeso dental actualizados y cefalogramas. Los individuos que cumplían con los criterios de inclusión fueron clasificados según el diagnóstico y luego se aplicaron métodos clínicos y radiográficos. Se realizaron mediciones de *overjet* y *overbite* en los modelos de estudio de yeso dental disponibles, junto con la relación molar según la clasificación de Angle. Además, se aplicó la valoración GOSLON para determinar el pronóstico oclusal a largo plazo y la necesidad final de cirugía secundaria.

Resultados: Se obtuvo una muestra de 30 pacientes. En cuanto al análisis oclusal, no se observaron alteraciones severas de *overbite*, mientras que el *overjet* mostró medidas predominantemente negativas; con el grupo de fisura labio palatina bilateral correspondiendo al grupo más alterado. 10 pacientes (33 %) fueron finalmente seleccionados para cirugía ortognática, presentando un *overjet* promedio de -0,13 mm y puntuaciones de GOSLON de 4-5. Ningún caso requirió de distracción osteogénica.

Conclusiones: El desarrollo esquelético observado en pacientes sometidos a la cirugía funcional de Delaire puede considerarse adecuado, ya que implica discrepancias maxilares leves y moderadas. Con el 53,3 % de los individuos clasificados en los grupos GOSLON 1-3, se pueden observar relaciones oclusales adecuadas, permitiendo que sean tratados exitosamente a través de un enfoque ortopédico.

INTRODUCTION

Cleft lip and palate (CLP) correspond to a group of congenital malformations of multifactorial etiology that feature an incomplete union of structures involved in nasal and oral cavities such as upper lip, alveolar process, soft and hard palate^{1,2}. They can be classified as syndromic and non-syndromic; 70 % of cases correspond to a non-syndromic nature; whereas syndromic CLPs have been associated with more than 300 syndromes^{3,4}. They can also be classified according to compromised structures. Cleft Lip (CL) involves exclusively the upper lip, cleft palate (CP) affects hard and/or soft palate. On the other hand, CLP represents a disruption from the upper lip to the soft palate, presenting themselves as unilateral (U-CLP) or bilateral (B-CLP); being left-side U-CLP is the most common among the Chilean population⁵.

Regarding epidemiology, CLP incidence varies according to ethnicity, showing a 1:500 incidence amongst the Asian population; 1:1,000 in the caucasian and Latin-American population, and 1:2,500 in the African population, being more predominant in male individuals. On a national aspect, Chilean incidence corresponds to 0.7:1,000 newborn individuals⁵. Risk factors for

CLP have been described as tabaquism, gestational alcohol, diabetes, arterial hypertension, preeclampsia, and pregnancy use of medication such as NSAIDs, antibiotics, and corticosteroids.

CLP treatment requires a multidisciplinary surgical approach focused on restoring vital functions for the newborn such as breathing and proper feeding. Once the primary surgery stage is concluded, individuals must undergo dental treatments to reach adequate morphofunctional development in early childhood, adolescence, and adulthood. Multiple surgical techniques have been described for primary CLP surgery and they can be further classified into two groups: single-stage and two-stage, considering simultaneous or deferred cheilorhinoplasty and veloplasty. Delaire's functional surgery (DFS), consists of a two-step CLP surgical technique first described by Jean Delaire in Nantes, France. The main purpose of DFS is the functional reconstitution of disrupted muscles involved in the nasolabial and palatal regions; thus, restoring functions such as deglutition, speech, and breathing by performing a first-stage cheilorhinoplasty and veloplasty at the age of 6 months, followed by palatoplasty at the age of 18-24 months⁶⁻⁹. However, due to natural progression and surgical procedures, a considerable amount of CLP patients reach adulthood with skeletal alterations often associated

with occlusal dysfunction, implying both functional and aesthetic disturbances. This further considers the need for secondary surgical procedures such as orthognathic surgery (OS) or distraction osteogenesis (DO) to stabilize skeletal bases and therefore improve their quality of life¹⁰.

The aim of this study is to analyze skeletal and dental features and treatment required by CL, CP, and CLP patients who underwent DFS during the years 2005-2010 in San Borja Arriarán Hospital (HCSBA), to determine the percentage of patients that required further secondary surgery.

PATIENTS AND METHODS

An observational retrospective study was designed, in which clinical records were collected in collaboration with the Orthodontics and Maxillofacial Unit, under previous informed consent of patients who underwent DFS during the years 2005-2010 in HCSBA meeting the following inclusion criteria:

Non-syndromic CL/CP/CLP individuals surgically intervened via DFS.

Complete medical record and available study models and lateral cephalogram.

- The exclusion criteria applied were as follows:
- Syndromic CL/CP/CLP.
- Patients requiring surgical reintervention following DFS.
- Patients treated with pre-surgical orthopedics.
- Lack or rejection of informed consent by parents or tutors.

Individuals meeting the inclusion criteria were applied clinical and radiographic methods, later performing Delaire's architectural and structural analysis. Data collection consisted of personal information, skeletal diagnosis, and orthopedic treatment. Individuals were classified according to diagnosis in four groups; U-CLP (n = 17), B-CLP (n = 6), CP (n = 3), and CL (n = 4).

For the purpose of this study, we exclusively realized cranial analysis, in order to determine the patient's skeletal class. This is due to the frequently altered dental position present in CLP individuals. Thus, stable cranial points were privileged, considering the C1-C4 and F1 lines of Delaire's analysis (Figure 1).

Measurements of overjet and overbite in millimeters (mm) were performed in available dental cast study models, along with molar relationship according to Angle's classification. In dental cast before the definitive first molar eruption was not possible to determine molar relationship. Furthermore, GOSLON Yardstick was applied to determine long-term occlusal prognosis.

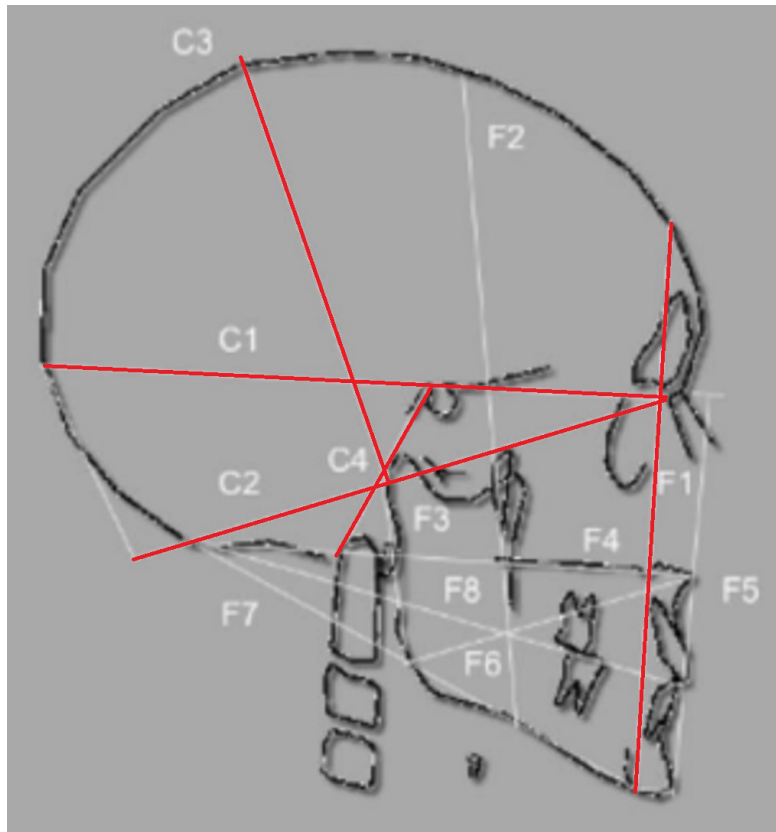


Figure 1. Illustration of the traces used in Delaire's architectural and structural analysis. Lines C1-C4 and F1, used in this study, are highlighted in red. C1: superior skull base line, traced from fronto-nasal and fronto-maxillary sutures connecting with the upper portion of anterior and posterior clinoid processes. C2: inferior skull base, traced from fronto-nasal and fronto-maxillary sutures connecting with the mid portion of the articular eminence of the temporal bone. C3: cranial height, traced perpendicular in midpoint of C2. C4: sphenoidal angle, traced from posterior clinoid process onto the posterosuperior region of the odontoid process. F1: anterior facial balance line, traced from C1 intersecting the anterior aspect of the nasopalatine duct.

RESULTS

From a total of 129 CLP patients surgically intervened during the years 2005-2010; 30 individuals met the inclusion criteria, corresponding to 20 (66,7 %) males and 10 (33,3 %) females (Table I). Regarding occlusal analysis, severe overbite alterations were not observed since they corresponded to a positive value in all measures. Overjet exhibited mostly negative measures; B-CLP corresponded to the most altered group (\bar{x} = -1,33 mm), followed by CP (\bar{x} = -1,0 mm) and U-CLP (\bar{x} = -0,59 mm); while CL was the only group presenting a positive overjet average (\bar{x} = 4,25 mm) (Figure 2). In terms of molar relationship, 50 % of patients presented neutral occlusion,

30 % disto-occlusion, 7 % mesio-occlusion, and 13 % were undetermined. Considering the GOSLON Yardstick, 53.3 % of patients presented GOSLON scores of 1-3, being considered as proper occlusal relationships and thus, less overall requirement for a subsequent surgical approach. Groups with bad/poor prognosis (GOSLON Score 4-5) were predominantly found in CP, U-CLP, and B-CLP groups (Figure 3).

Skeletal class according to lateral cephalogram, class III was observed on 50 % of individuals, 36.7 % class I, and 13,3 % class II (Figure 4). By means of Delaire's architectural and structural analysis, it was able to determine that skeletal alterations were attributed to a mild to moderate posterior position adopted by the maxilla, in comparison to a properly developed and positioned mandible (Figure 5).

Table I. General results of the study.

Group	Diagnosis	Permanent Dentition		Deciduous Dentition		Total
		Male	Female	Male	Female	
1	U-CLP	1	6	9	1	17
2	B-CLP	1	0	5	0	6
3	CP	0	1	1	1	3
4	CL	2	0	1	1	4
		4 (13.3 %)	7 (23.3 %)	16 (53.3 %)	3 (10 %)	30 (100 %)

U-CLP: unilateral cleft lip and palate. B-CLP: bilateral cleft lip and palate. CP: cleft palate. CL: cleft lip.

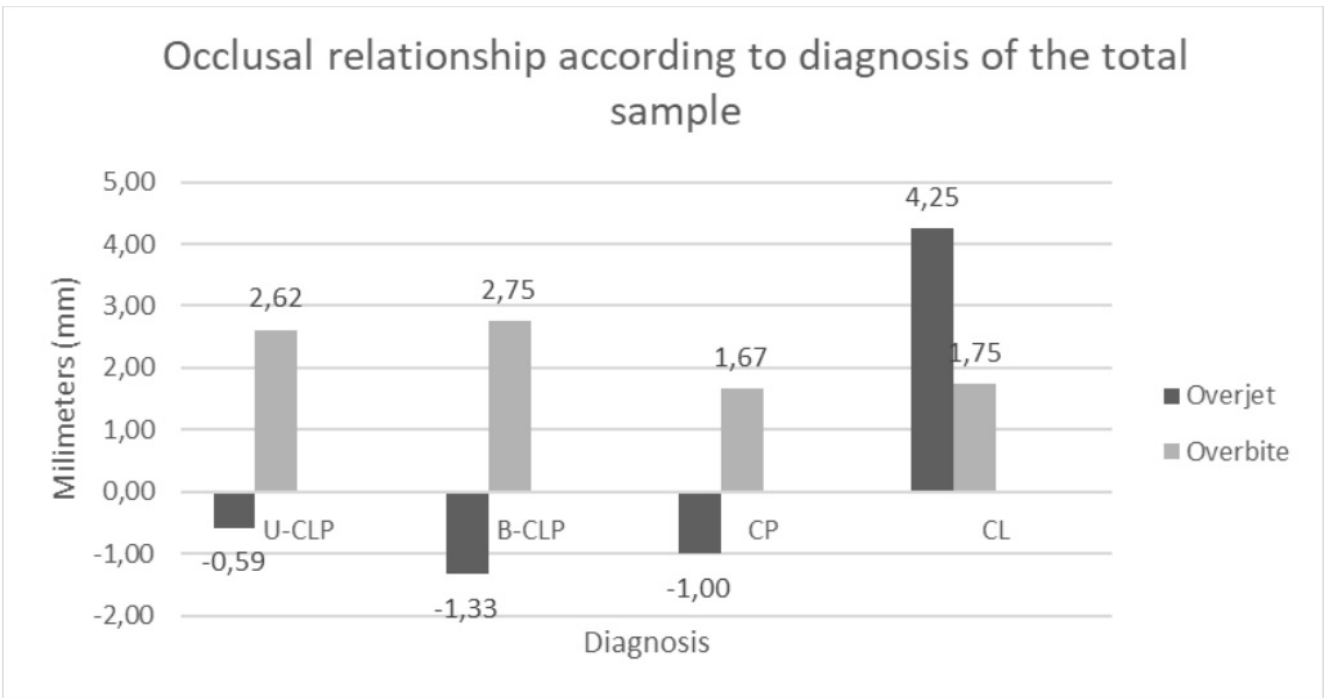


Figure 2. Occlusal relationship of the total sample, divided into groups according to diagnosis.
Group 1: Patients with unilateral cleft lip and palate (U-CLP). Group 2: patients with bilateral cleft lip and palate (B-CLP).
Group 3: Patients with cleft palate (CP). Group 4: Patients with cleft lip (CL).

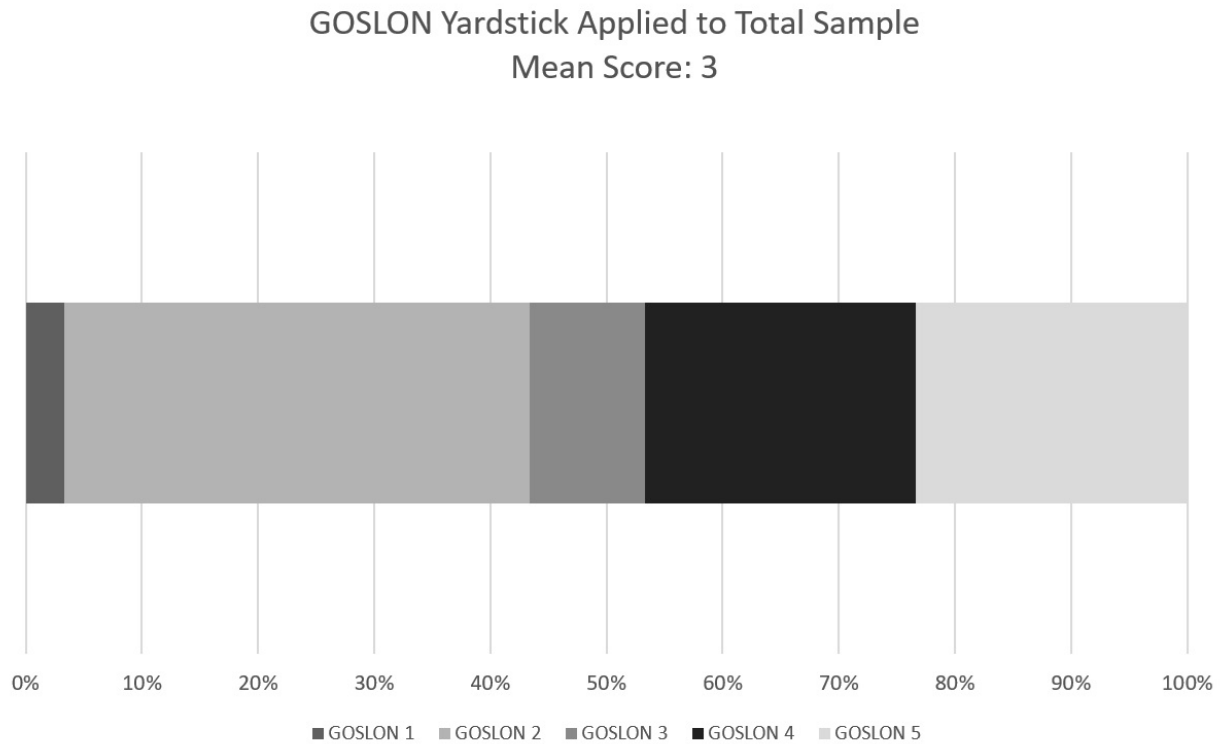


Figure 3. GOSLON Yardstick score applied to the total sample. GOSLON Score 1 (3,3%), GOSLON Score 2 (40 %), GOSLON Score 3 (10 %), GOSLON Score 4 (23,3 %), GOSLON Score 5 (23,3 %).

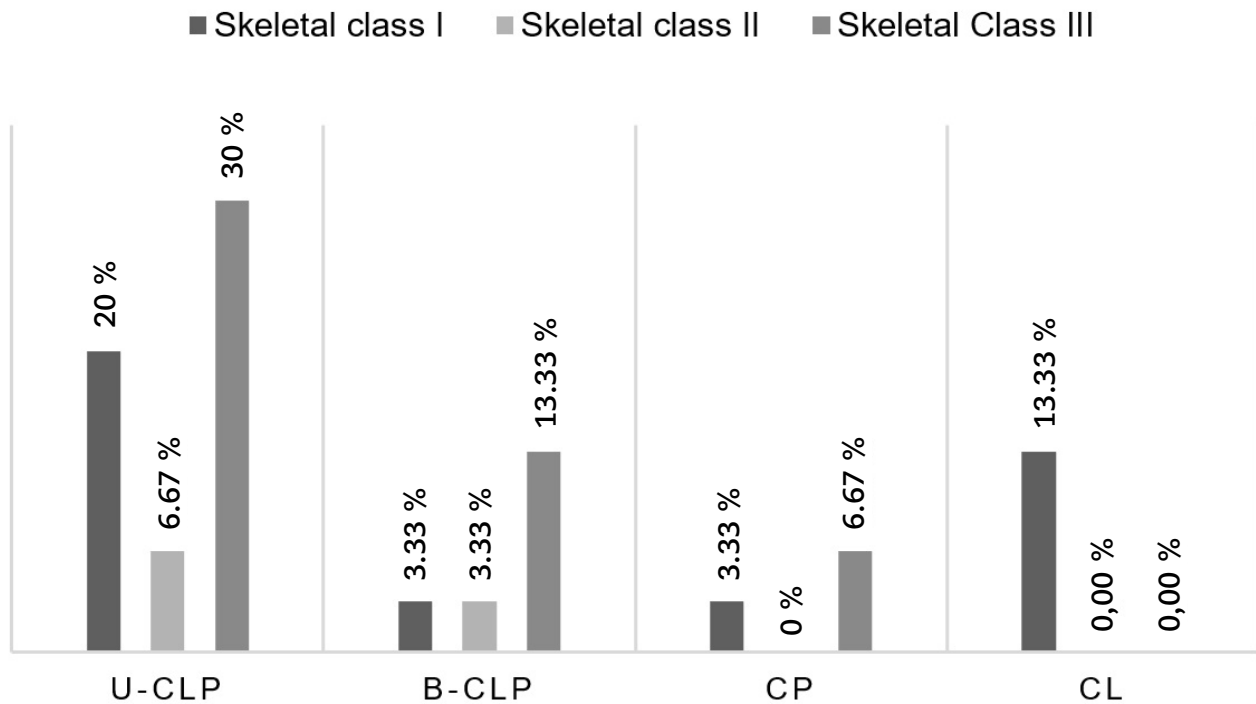


Figure 4. Skeletal class of the total sample divided into groups according to diagnosis. Group 1: Patients with unilateral cleft lip and palate (U-CLP). Group 2: patients with bilateral cleft lip and palate (B-CLP). Group 3: Patients with cleft palate (CP). Group 4: Patients with cleft lip (CL).

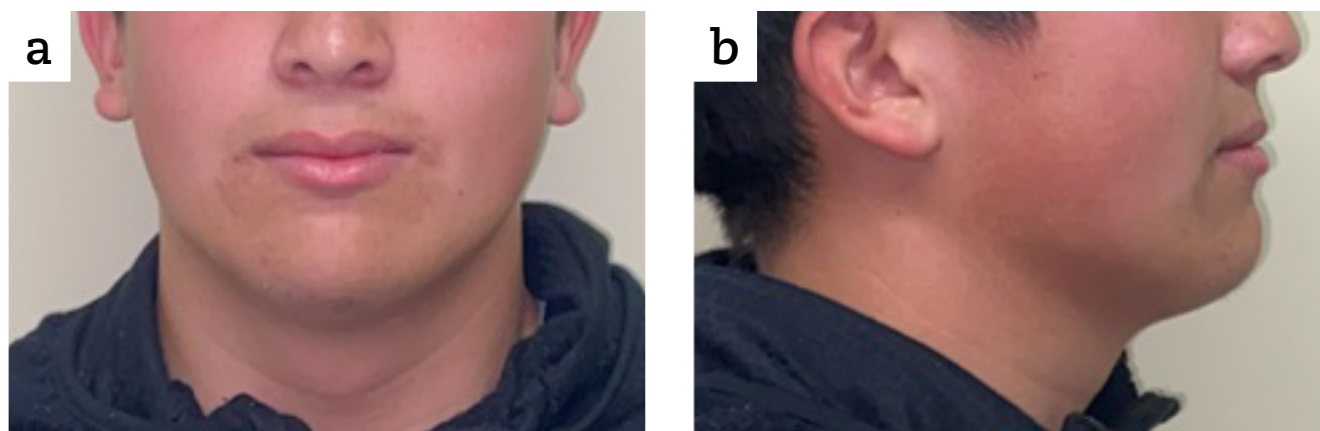


Figure 5. Frontal (a) and right profile view of CL patient during follow up secondary to Delaire's functional surgery.

Requirement for Secondary Surgery

According to occlusal and skeletal characteristics presented in this sample of patients included in this study, a total of 10 patients (33,3 %) were indicated surgical correction through OS at an average age of 15.7 years (Table II). Based on CLP diagnosis, 60 % of the patients with surgical indication of OS were B-CLP, 20 % corresponded to U-CLP, and 10 % each for CL and CP, respectively; exhibiting skeletal class III on 80 % of the cases and presenting an average of -1,85 mm in overbite and 2.8 mm in overjet. Class I was observed on 20 % of patients undergoing surgery, indicating OS due to a mild maxillary retrusion unable to be corrected using orthopedic treatment (Figure 6). The GOSLON Yardstick for these patients consisted of GOSLON 2 on 20% of patients, and 80% classified as GOSLON 4-5.

DISCUSSION

CLP is a condition more predominant in male individuals rather than females, with an approximate frequency of 2:1. Our sample follows such said distribution reported on both national¹¹ and international literature¹²⁻¹⁴.

Multiple surgical techniques have been described for the primary management of CLP worldwide. A European register which included 30 different countries with 201 reference healthcare centers for CLP recorded 194 different surgical

protocols for primary CLP closure, 42,8 % of them consisting of a two-stage surgical method, performing cheilorhinoplasty as a first step, followed by veloplasty and palatoplasty on a second period, much similar to the methodology described in DFS¹⁵.

Regardless of the surgical method employed, CLP affects in different magnitudes the growth and development of the maxilla. A systematic review carried out by Reddy et al.¹⁶ included 26 articles to analyze the relationship between the skeletal development of CLP individuals undergoing different protocols for primary cleft surgery, either a single-step or two-step methods. They were able to conclude that regardless of the surgical current chosen, different degrees of maxillary hypoplasia can be detected as early as 3 years of age. However, no significant differences were found comparing one-stage and two-stage surgical maneuvers, mainly due to a lack of studies with high-quality evidence.

Regarding the influence of DFS on skeletal development of CLP individuals, another study on Chilean population by Donoso et al.¹⁷ compared the sagittal development of the maxilla in 10 U-CLP patients intervened by DFS in HCSBA with non-CLP individuals with direct blood correlation, aged between 7-12 years. Through Delaire's structural analysis, measuring C1-F1 traces, they were not able to find significant differences in terms of maxillary development between CLP and non-CLP individuals.

Both OS and DO have been successfully reported for the management of midface hypoplasia present in CLP individu-

Table II. Indication for orthognathic surgery according to diagnosis of the total sample.

Diagnosis	Indication for Orthognathic Surgery		Total
	No	Yes	
U-CLP	11	6	17
B-CLP	4	2	6
CP	2	1	3
CL	3	1	4
	20 (66.7 %)	10 (33.3 %)	30 (100 %)

U-CLP: unilateral cleft lip and palate. B-CLP: bilateral cleft lip and palate. CP: cleft palate. CL: cleft lip.

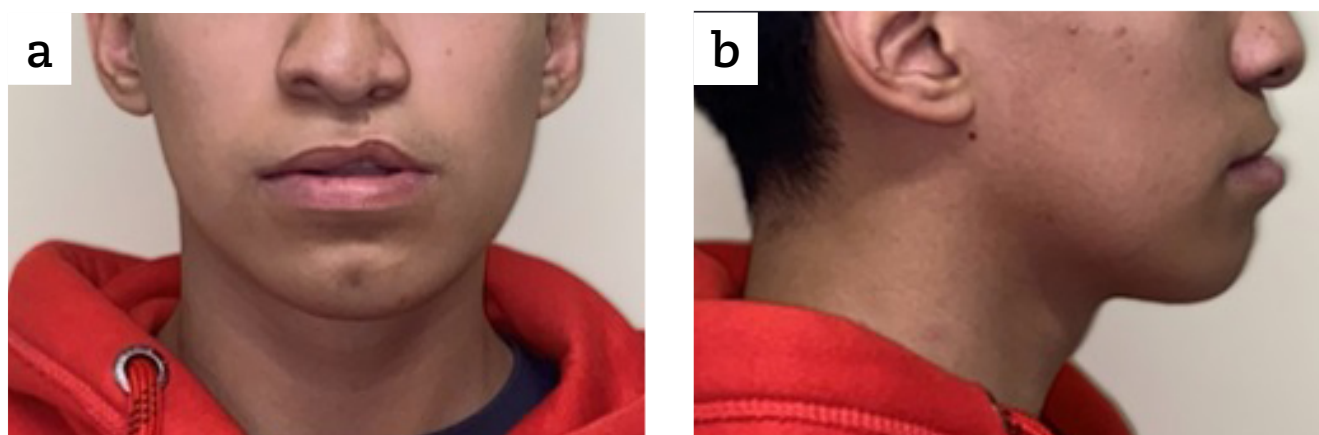


Figure 6. Frontal (a) and right profile (b) view of U-CLP patient during follow up, with ultimate indication for secondary orthognathic surgery.

als. In the context of OS; Felemovicious & Ortiz-Monasterio¹⁸ evaluated a total of 38 CLP patients, 30 U-CLP and 8 B-CLP, with an indication of OS in Mexico. The surgical procedure consisted of conventional Le Fort I and bilateral sagittal split osteotomies, with a mean sagittal advancement of 7 mm. Posteriorly, patients were evaluated by orthodontists and plastic surgeons not related to the study, qualifying as good and excellent results by subjective methods such as comparative preoperative and postoperative extraoral and intraoral photographs; therefore concluding that OS stands as a reliable secondary surgical procedure for managing midface hypoplasia in CLP.

Regarding the Asian population, a study directed by Yamanishi et al.¹⁹ compared long-term results between single-stage and two-stage CLP closure protocols, being able to demonstrate more favorable results in both sagittal and transverse aspects of maxillary development 4 years postoperatively for the two-step CLP closure process. Thus, it may imply a lower rate of secondary surgical indication in these patients. Daskalogiannakis & Mehta²⁰ evaluated OS requirements in 211 U-CLP and 129 B-CLP in Toronto, without a specific surgical protocol described for their primary CLP surgery. Amongst their findings, they report a 48,3 % indication for OS in U-CLP patients and 65.1 % for B-CLP; the latter being significantly higher than our percentage of OS requirement for B-CLP individuals. This can be explained due to the smaller sample size and thus, less representative results on our behalf.

On another aspect, Manna et al.²¹ analyzed 36 CLP patients in Italy undergoing primary cleft surgery consisting of cheilorhinoplasty at 6 months of age, veloplasty at 10 months of age, and palatoplasty at 3-3.5 years of age, complimented with adjuvant orthodontic and orthopedic treatment. Different cheilorhinoplasty techniques were described according to CLP diagnosis; Tennison & Millard technique for B-CLP and Pfeiffer or Millard technique for U-CLP, whereas Ortiz-Monasterio and Widmaier-Perko techniques were performed as standard veloplasty and palatoplasty procedures, respectively. At an average age of 6.9 years, it was concluded that 77.7 % of the individuals reached proper occlusion, speech, nasal valve functions, and aesthetics. However, the remaining 22,3 % presented malocclusions and compressed alveolar processes. It was concluded

that 11.1 % ultimately required OS due to poor response to adjuvant orthopedic treatment.

Brusati et al.²² studied 40 U-CLP patients managed with a two-stage protocol consisting of modified Delaire cheilo-rhinoplasty performed at the age of 6 months, followed by veloplasty at 18 months, and palatoplasty simultaneously with gingivoperiostioplasty at an average of 2.9 years of age. Through cephalogram, they followed their craniofacial development and further requirements for OS. At the average age of 19.8 years, 32.5 % required secondary surgery; presenting similar results in comparison to the sample of our study. Authors conclude that this two-stage protocol appears effective for primary CLP surgery, providing satisfactory results regarding speech and labial appearance, affecting a moderate degree of maxillary development.

As an alternative procedure, DO stands as a first-choice surgical technique indicated for patients presenting severe (> 10 mm) midface or maxillary hypoplasia²³. It has also been proven reliable for managing hypoplastic maxillae secondary to dental agenesis and/or hypodontias. Through DO it can preserve velopharyngeal function and preserve stable molar relationships while improving osseous and soft tissue profile^{23,24}. However, reports questioning its efficiency compared to OS can be found in the literature, due to an increased rate of skeletal relapse²⁵.

To summarize the findings of our investigation, it can be concluded that:

Skeletal growth and development in the craniofacial region are always affected in surgically intervened CLP individuals, regardless of the surgical chronology employed. B-CLP and U-CLP are greatly affected compared to CL and CP, which present a lesser degree of skeletal alterations.

With an average overjet and overbite of -0.13 mm and 2.13 mm respectively, DFS leads to mild and moderate intermaxillary discrepancy, requiring a less morbid secondary surgery.

None of our cases require OD. Out of the sample, 53.3% of the individuals can be classified in GOSLON groups 1-3, presenting proper to acceptable dental and occlusal relationships allowing them to be successfully treated with fixed or removable orthopedic devices.

Authors consider orthodontic and orthopedic treatment crucial for improving both transversal and sagittal dento-skeletal alterations in CLP patients.

Considering the limitations of our study, we can consider that a diminished sample size ($n = 30$) does not permit the extrapolation of obtained results to a regional or national aspect. Regardless of similar results observed in previous national and international studies in the CLP discipline, further recommendations and incentives to standardize patient follow-up reaching adulthood provide more reliable data on secondary surgical indications in these patients.

CONFLICTS OF INTERESTS

The authors declare to have no conflicts of interest regarding the publication of this article.

FUNDING SOURCES

There is nothing to declare.

ETHICS

The authors state that the current article meets the principles stated in the Declaration of Helsinki and has been properly approved by the San Borja Arriarán Hospital Ethics Committee.

REFERENCES

- Argandoña J, Pantoja R, Cortés J. Ubicación de las bases esqueléticas maxilares en la arquitectura craneofacial (Parte II). *Rev Dent Chile*. 1992;83(3):171-80.
- Cordero E, Martínez G, Espinoza I, Pantoja R. Estudio Retrospectivo de Fisuras Labio-Máxilo-Palatina en Chile, 12 años de seguimiento. *Int J Odontostomat*. 2021;15(1):88-93. DOI: 10.4067/S0718-381X2021000100088. DOI: 10.4067/S0718-381X2021000100088.
- Escobar L, Prada J, Tellez C, Castellanos J. Bases genéticas de la formación de fisuras labiales y/o palatinas en humanos. *Rev CES Odontología*. 2013;26(1):57-67.
- Kini U. Genetics and orofacial clefts: a clinical perspective. *Br Dent J*. 2023;234(12):947-52.
- Cordero E, Muñoz M, Espinoza I, Pantoja R. Espectro de dismorfosis dentofaciales: estudio retrospectivo de 23 años en hospital tipo I de alta complejidad en Chile. *Rev Clin. Periodoncia Implantol. Rehabil Oral Vol*. 2019;12(1):15-8.
- Markus AF, Delaire J. Functional primary closure of cleft lip. *Br J Oral Maxillofac Surg*. 1993;31(5):281-91.
- Delaire J. La Cheilo-Rinoplastie Primaire pour Fente Labiomaxillaire Congénitale Unilatérale. *Essai de Schematisation d' une Technique*. *Rev Stom*. 1975;(76):193-215.
- Delaire J. Theoretical principles and technique of functional closure of the lip and nasal aperture. *J Maxillofac Surg*. 1978;6(2):109-16. DOI: 10.1016/S0301-0503(78)80078-2.
- Talmant JC. Evolution of the functional repair concept for cleft lip and palate patients. *Indian J Plast Surg*. 2006;39(2). DOI: 10.4103/0970-0358.29555.
- Ravelo V, de Moraes M, Olate S. Transverse, Vertical and Sagittal Relationship in Subjects with Facial Deformity Candidates for Orthognathic Surgery. *Int J Odontostomat*. 2020;14(4):664-9. DOI: 10.4067/S0718-381X2020000400664.
- Sepúlveda G, Palomino H, Cortés J. Prevalence of cleft lip and palate and risk indicators: Study of the reference population of Felix Bulnes University Hospital, Santiago de Chile. *Rev Esp Cir Oral y Maxilofac*. 2008;30(1):17-25.
- Semb G, Brattström V, Mølsted K, Prahl-Andersen B, Shaw WC. The Eurocleft study: intercenter study of treatment outcome in patients with complete cleft lip and palate. Part 1: introduction and treatment experience. *Cleft Palate Craniofac J*. 2005;42(1):64-8. DOI: 10.1597/02-119.1.1.
- Stone C. Cleft Lip and Palate: Etiology, Epidemiology, Preventive, and Intervention Strategies. *Anat Physiol*. 2014;4(3). DOI: 10.4172/2161-0940.1000150.
- Ellis E. Management of Patients With Orofacial Clefts. In: JR Hupp, Ellis EI, Tucker MR. *Tucker: Contemporary Oral and Maxillofacial Surgery*. New York: Elsevier; 2018. p. 608.
- Shaw WC, Semb G, Nelson P, Brattström V, Mølsted K, Prahl-Andersen B, Gundlach KK. The Eurocleft project 1996-2000: overview. *J Craniomaxillofac Surg*. 2001;29(3):131-42. DOI: 10.1054/jcms.2001.0217.
- Reddy RR, Gosla Reddy S, Vaidhyathan A, Bergé SJ, Kuijpers-Jagtman AM. Maxillofacial growth and speech outcome after one-stage or two-stage palatoplasty in unilateral cleft lip and palate. A systematic review. *J Craniomaxillofac Surg*. 2017;45(6):995-1003. DOI: 10.1016/j.jcms.2017.03.006.
- Donoso F, Pantoja F, Pantoja R. Crecimiento sagital maxilar en fisurados unilaterales operados funcionalmente. *Rev Esp Cir Oral y Maxilofac*. 2007;29(3):156-61. DOI: 10.4321/S1130-05582007000300005.
- Felemovicius J, Ortiz-Monasterio F. Management of the impaired adult cleft patient: the last chance. *Cleft Palate Craniofac J*. 2004;41(5):550-8. DOI: 10.1597/03-039.1.
- Yamanishi T, Nishio J, Kohara H, Hirano Y, Sako M, Yamanishi Y, et al. Effect on maxillary arch development of early 2-stage palatoplasty by modified furlow technique and conventional 1-stage palatoplasty in children with complete unilateral cleft lip and palate. *J Oral Maxillofac Surg*. 2009;67(10):2210-6. DOI: 10.1016/j.joms.2009.04.038.
- Daskalogiannakis J, Mehta M. The need for orthognathic surgery in patients with repaired complete unilateral and complete bilateral cleft lip and palate. *Cleft Palate Craniofac J*. 2009;46(5):498-502. DOI: 10.1597/08-176.1.
- Manna F, Pensiero S, Clarich G, Guarneri GF, Parodi PC. Cleft lip and palate: current status from the literature and our experience. *J Craniofac Surg*. 2009;20(5):1383-7. DOI: 10.1097/SCS.0b013e3181b0daa3.
- Brusati R, Meazzini MC, Rezzonico A, Biglioli F, Garattini G, Battista VMA, et al. Evaluation of a Sample of Patients With Unilateral Cleft Lip and Palate Treated With a Two-Stage Protocol. *J Craniofac Surg*. 2018;29(8):2058-64. DOI: 10.1097/SCS.0000000000004789.
- Fariña R, Diaz A, Pantoja R, Bidart C. Treatment of Maxillary Hypoplasia in Cleft Lip and Palate: Segmental Distraction Osteogenesis With Hyrax Device. *J Craniofac Surg*. 2018;29(2):411-4. DOI: 10.1097/SCS.0000000000004118.
- Martínez-Plaza A, Menéndez-Núñez, M, Martínez-Lara I, Fernández-Solís J, Gálvez-Jiménez, P, Monsalve-Iglesias F. Avance maxilar en pacientes fisurados labio palatinos con distractor intraoral. *Rev Esp Cir Oral Maxilofac*. 2015;37(3):123-31. DOI: 10.1016/j.maxilo.2014.01.001.
- Guerrero M, Traub V, Zursiedel M, Álamos C, Noguera A, Gutiérrez C, Solé P. Facial Changes and their Stability over Time in Non-Syndromic Cleft Lip and Palate Patients Undergoing Maxillary ÊDistraction Osteogenesis Through Rigid External Distractor. *Narrative Review*. *Int. J. Odontostomat*. 2019;13(2):123-31.