



Revista Española de Cirugía Oral y Maxilofacial

Publicación Oficial de la SECOM CyC Sociedad Española de Cirugía Oral y Maxilofacial y de Cabeza y Cuello

Artículo Aceptado para su pre-publicación / Article Accepted for pre-publication

Título / Title:

Nota técnica: alargamiento de labio superior tras procedimientos quirúrgicos maxilares. una técnica de cierre simple y novedosa / Technical note: upper lip vermilion elongation technique after maxillary surgical approaches: a simple and innovative procedure

Autores / Authors:

Ana Laura Capote Moreno, Pilar Rubio Bueno, Francisco J Rodriguez Campo

DOI: [10.20986/recom.2025.1618/2025](https://doi.org/10.20986/recom.2025.1618/2025)

Instrucciones de citación para el artículo / Citation instructions for the article:

Capote Moreno Ana Laura, Rubio Bueno Pilar, Rodríguez Campo Francisco J. Nota técnica: alargamiento de labio superior tras procedimientos quirúrgicos maxilares. una técnica de cierre simple y novedosa / Technical note: upper lip vermilion elongation technique after maxillary surgical approaches: a simple and innovative procedure. j.maxilo 2025. doi: 10.20986/recom.2025.1618/2025.



Este es un archivo PDF de un manuscrito inédito que ha sido aceptado para su publicación en la *Revista Española de Cirugía Oral y Maxilofacial*. Como un servicio a nuestros clientes estamos proporcionando esta primera versión del manuscrito en estado de prepublicación. El manuscrito será sometido a la corrección de estilo final, composición y revisión de la prueba resultante antes de que se publique en su forma final. Tenga en cuenta que durante el proceso de producción se pueden dar errores, lo que podría afectar el contenido final. El copyright y todos los derechos legales que se aplican al artículo pertenecen a la *Revista Española de Cirugía Oral y Maxilofacial*.

**TECHNICAL NOTE: UPPER LIP VERMILION ELONGATION TECHNIQUE AFTER
MAXILLARY SURGICAL APPROACHES: A SIMPLE AND INNOVATIVE PROCEDURE**

**NOTA TÉCNICA: ALARGAMIENTO DE LABIO SUPERIOR TRAS PROCEDIMIENTOS
QUIRÚRGICOS MAXILARES. UNA TÉCNICA DE CIERRE SIMPLE Y NOVEDOSA**

Ana Capote-Moreno, Pilar Rubio-Bueno y Francisco J. Rodríguez-Campo

*Servicio de Cirugía Oral y Maxilofacial. Hospital Universitario de la Princesa.
Universidad Autónoma de Madrid. Madrid, España*

CORRESPONDENCE

Ana Capote-Moreno

anacapotemoreno@gmail.com

Received: 12-03-2025

Acepted: 8-04-2025

ABSTRACT

Introduction: Soft tissue changes after orthognathic surgery are one of the most important concerns to consider when treating malocclusions. Several techniques of closure have been employed to achieve an aesthetic balance between upper lip and teeth after maxillary advancements.

Material and method: A new surgical technique to minimize upper lip shortening after Le Fort I advanced osteotomies is presented. This new surgical wound closure method consists on suturing the lower edge of the incision of the upper lip wound to the bottom of the buccal space, leaving the submucous tissue without coverage allowing secondary epithelial metaplasia. This cheiloplasty is employed routinely in our center for wound closure in patients after both convectional orthognathic surgery and obstructive sleep apnea procedures.

Discussion: The technique described is useful to control the length shortening and vermilion lip exposure after maxillary surgery and minimized hypertrophic scars in the buccal mucosa, that could favor retraction of the gingivae of the upper teeth. This wound closure method can be associated to other soft tissue procedures as the classic nasal alar base cinch or lip volume augmentation techniques as the bilateral buccal fat pad.

Keywords: Lip vermilion elongation, V-Y closure, obstructive sleep apnea, orthognathic surgery, cinch nasal alar base suture.

RESUMEN

Introducción: Los cambios posquirúrgicos de los tejidos blandos tras los diferentes procedimientos de cirugía ortognática, son uno de los objetivos más importantes a considerar cuando se tratan las maloclusiones. Diferentes técnicas de cierre han sido empleadas para alcanzar un equilibrio entre el labio superior y los dientes tras las cirugías de avance maxilar.

Material y método: Se presenta una novedosa técnica quirúrgica para minimizar el acortamiento del labio superior tras las osteotomías de Le Fort I de avance maxilar. Este método de cierre del labio superior consiste en suturar el borde inferior de la incisión quirúrgica al tejido blando del fondo del vestíbulo superior, dejando el tejido submucoso del labio sin cobertura para favorecer la metaplasia mucosa secundaria. Esta queiloplastia se emplea de forma rutinaria en nuestro centro para el cierre de la herida quirúrgica maxilar en pacientes de cirugía ortognática convencional y, sobre todo, en pacientes con apnea obstructiva del sueño con grandes avances maxilares.

Discusión: La técnica descrita es eficaz para controlar el acortamiento y la exposición del labio superior respecto al incisivo superior tras una cirugía de avance maxilar y minimiza las cicatrices hipertróficas en la mucosa labial y vestíbulo superior, que pueden favorecer la retracción gingival de los incisivos. Este método de cierre se puede asociar a otros procedimientos de tejidos blandos como la cincha nasal clásica o el aumento de labio con bola de grasa de Bichat.

Palabras clave: Alargamiento de labio superior, cierre en V-Y, apnea obstructiva del sueño, cirugía ortognática, cincha nasal.

INTRODUCTION

One of the most important goals in orthognathic surgery is the esthetic balance between upper lip and teeth. Changes in nasolabial region that may occur after orthognathic surgery have been widely documented, which include alar base widening, nasal tip upturning and tip protrusion, nasal length decrease, thinning and flatting of the upper lip and upper vermillion shortening^{1,2}. The surgical approach of the maxilla has a direct effect on this nasal width and on the exposure of the upper labial vermillion as well as on the total length of the upper lip^{3,4}. Maxillary advancement Le Fort I (LFI) osteotomies can produce unsatisfactory aesthetic results especially in thin upper lips, that may appear so straight, thinner and with shortened red vermillion³. The amount of advancement also influences these changes, as large anteroposterior movements more than 10 mm may shorten the lip with high probability.

During many years, several authors have made efforts to modify the different sutures that can improve these negative effects on the upper lip, such as the alar cinch suture, or the muco-muscle-periosteal V-Y closure⁵⁻⁷. Paredes de Sousa et al., in their systematic review of 17 papers concluded that alar cinch suture and V-Y closure technique seemed to have little effect in avoiding undesirable changes on nasolabial tissues after maxillary advancement osteotomies¹. However, results are variable as studies are not homogeneous in the methodology to analyze soft tissues changes after maxillary osteotomies since they combined 2D and 3D analysis¹.

In this article, a new wound closure technique after LFI osteotomy is presented, with the aim of improving vermillion exposure and preventing upper lip shortening.

METHOD AND SURGICAL TECHNIQUE

This technique for upper lip closure after maxillary osteotomies is performed routinely in patients submitted for orthognathic surgery; either due to dentofacial deformities or maxillomandibular advancement in obstructive sleep apnea (OSA) patients. In these patients, a LFI osteotomy is performed for maxillary advancement, with or without associated mandibular osteotomies. In OSA patients, big maxillary advancements are reached up to 10 mm, with subsequent protraction of soft tissues that may shorten lip height. All the procedures are performed under general anesthesia and with controlled hypotension to control intraoperative bleeding. All the patients have been previously planned with a tridimensional software (Dolphin software; Dolphin Imaging and Management Solutions, Chatsworth, CA) from Cone-beam computed tomography taken with an i-CAT device (Imaging Sciences International, Hatfield, PA).

After bone osteotomies and miniplate fixation, upper lip cheiloplasty is performed for wound closure in cases with maxillary advancements of 5 mm or more. The technique consists on suturing with resolvable or non-resolvable sutures the lower edge of the incision of the upper lip wound to the bottom of the buccal space, leaving the upper part of the submucous tissue without coverage allowing secondary epithelial metaplasia by contact with the oral cavity (Figures 1 and 2). Submucosal lack of bleeding is ensured after suturing the mucosa. This closure is associated with a classic nasal alar base cinch, but substitutes the classic V-Y lip closure. The objective of this new suture is to elongate homogeneously the upper lip vermilion, avoiding retractile scars that could shorten the lip in the postoperative period.

Immediate postoperative care includes analgesic medication, wash-mouth with chlorhexidine and soft diet. Local lip massages are also recommended the following weeks after surgery. Progressive secondary metaplasia of the submucosa is observed in all the cases (Figures 3 to 5). Dimensional changes of the upper lip are subsequently analyzed in these patients by Arnett Facial Analysis and tridimensional studies six months after the procedure and compared with preoperative measures (lip length and red vermilion length). Lip thickness and lip length increased with this technique and the new upper lip contour was considered good to excellent in all cases.

DISCUSSION

The harmony of soft tissues after skeletal changes in orthognathic surgery has been gaining importance in the last decade. Upper lip aesthetic and exposure of upper central tooth must be one of the main objectives in our surgical planning in these patients. It is known that lip thickness is bigger in childhood and puberty, decreasing in adult age. Vermillion exposure could be a problem in those patients candidates to maxillary procedures, especially those with thin and sharp lips⁴. Changes of upper incisor landmarks after surgery have been described as the most important variables in predicting lip response to maxillary movements⁸. In that sense, great advancements more than 10 mm, as occurs in OSA patients, may tighten and thinner the red vermillion, making it anesthetic and contributing to an excessive upper incisor exposure³. Upper lip contour, even though elongation with classical closure techniques as V-Y closure, may also appear so straightened and with sight loss of normal lip pout⁸. As commented, the most extended lip closure after maxillary osteotomies is V-Y closure associated with alar nasal cinch, proposed by Collins and Epker in 1982⁹. Wide variety of studies have reported different results with this suturing technique, all of them supporting its beneficial effect in lip lengthening. However, as thickness and contour of the vermillion are not guaranteed, alternatives as the bilateral buccal fat pad described by Rubio et al.³ could provide excellent aesthetic results and maintain lip volume indefinitely.

Authors has attempted to predict changes in nasolabial complex after LFI osteotomies depending on type and amount of movements, with predictive models that may help surgeons to plan maxillary osteotomies. Vasudavan et al.², in their anthropometric study of changes in nasolabial soft tissues after LFI osteotomy, showed a cutaneous lip height increased mainly due to the unfurling of the upper lip. However, they did not find significant changes in lip vermillion height. Brooks et al.⁸ suggested that the predictive amount of anterior movement of the upper lip may ranged from 50% at subnasale to 90% at labrale superius of the underlying skeletal movement of the maxilla. However, other authors as Stella et al.¹⁰, concluded that for a given amount of maxillary advancement is difficult to predict the amount of soft tissue change and the correlation is less with bigger anterior movements. Most of these studies are based on

2D lateral cephalograms without clinical facial measurements, so conclusions may probably not be extrapolated to other series. Tridimensional measurement with cone-beam tomograms combined with facial analysis, as Arnett facial Analysis, may be essential when comparing soft tissue results of the nasomaxillary complex^{1,3}.

Upper lip closure with the described technique have shown to preserve an adequate lip-tooth relation and provide a good lip contour and projection, even in big maxillary advancements up to 10 mm like OSA patients. It also avoids undesirable scars that may contribute to gum retraction and inadequate upper incisor exposure after surgery. Postoperative morbidity is low and complete metaplasia of the buccal sulcus is observed 4 to 5 weeks after surgical procedure with good to excellent results. Other advantages are that this new approach is also easy to reproduce, does not extend intraoperative time and require little postoperative care except of simple self-administrated massages by the patient at home.

CONCLUSION

Upper lip elongation cheiloplasty is an excellent alternative for lip closure after maxillary advancements, even in cases with big anteroposterior movements up to 10 mm. This new technique is useful to control the length shortening, contour and vermilion exposure of the upper lip. Hence, it should be considered instead of classical V-Y closure and could be combined with other procedures as alar nasal cinch or vermilion thickening with the buccal fat pad flap.

ACKNOWLEDGEMENTS

To Dr. Francisco J. Rodriguez Campo for his image support. To Santiago Jimenez and Adrian Jimenez. 3D Technician Experts, Ortosan Virtual Lab (Madrid).

FUNDING

This study has been granted by the Institute of Health Carlos III (ISCIII), co-financed by the European Regional Development Fund (ERDF) under the Research Project Reference PI18/01891.

DECLARATION OF PATIENTS CONSENT

The authors certify that they have obtained all appropriate patient consent forms. In the form the patient(s) has/have given his/her/their consent for his/her/their images and other clinical information to be reported in the journal. The patients understand that their names and initials will not be published and due efforts will be made to conceal their identity, but anonymity cannot be guaranteed.

FINANCIAL SUPPORT AND SPONSORSHIP

Nil.

CONFLICTS OF INTEREST

There are no conflicts of interest.

REFERENCES

1. Paredes de Sousa Gil A, Guijarro-Martínez R, Haas OL Jr, Hernández-Alfaro F. Three-dimensional analysis of nasolabial soft tissue changes after Le Fort I osteotomy: A systematic review of the literature. *Int J Oral Maxillofac Surg*. 2019;48(9):1185-200. DOI: 10.1016/j.ijom.2019.01.028.
2. Vasudavan S, Jayaratnet YSN, Padwa BL. Nasolabial soft tissue changes after Le Fort I advancement. *J Oral Maxillofac Surg*. 2012;70(4):e270-7. DOI: 10.1016/j.joms.2011.11.022.
3. Rubio-Bueno P, Ardanza B, Piñas L, Murillo N. Pedicled buccal fat pad flap for upper lip augmentation in orthognathic surgery patients. *J Oral Maxillofac Surg*

2013;71(4):e178-84. DOI: 10.1016/j.joms.2012.11.012.

4. Scomparin L, Bernaola-Paredes WE, Salvatore de Freitas KM, Chantarola Rodrigues M, Vasques da Fonseca E, Falbo Martins D. Eficacia de las suturas de las bases alares y en forma de V-Y labial en pacientes sometidos a expansión quirúrgicamente asistida de maxila. *Int J Med Surg Sci.* 2017;4(1):1127-39. DOI: 10.32457/ijmss.2017.006.
5. Peled M, Ardekian L, Krausz AA, Aizenbud D. Comparing de effects of V-Y advancement versus simple closure on upper lip aesthetics after Le Fort I advancement. *J Oral Maxillofac Surg.* 2004;62(3):315-9. DOI: 10.1016/j.joms.2003.08.015.
6. Muradin MSM, Seubring K, Stoelinga PJW, Bilt A, Koole R, Rosenberg AJW. A prospective study on the effect o modified alar cinch sutures and V-Y closure versus simple closing sutures on nasolabial changes after Le Fort I intrusion and advancement osteotomies. *J Oral Maxillofac Surg.* 2011;69(3):870-6. DOI: 10.1016/j.joms.2010.03.008.
7. Talebzadeh N, Pogrel MA. Upper lip length after V-Y versus continuous closure for Le Fort I level maxillary osteotomy. *Oral Surg Oral Med Oral Pathol Oral Radiol Endod.* 2000;90(2):144-6. DOI: 10.1067/moe.2000.107836.
8. Brooks BW, Buschang PH, Bates JD, Adams TB, English JD. Predicting lip response to 4-piece maxillary LeFort I osteotomy. *Am J Orthod Dentofacial Orthop.* 2001;120(2): 124-33. DOI: 10.1067/mod.2001.115614.
9. Collins PC, Epker BN. The alar base cinch: A technique for prevention of alar base flaring secondary to maxillary surgery. *Oral Surg Oral Med Oral Pathol.* 1982;53(6):549-53. DOI: 10.1016/0030-4220(82)90338-3.
10. Stella JP, Streater MR, Epker BN, Sinn DP. Predictability of upper lip soft tissue changes with maxillary advancement. *J Oral Maxillofac Surg.* 1989;47(7):697-703. DOI: 10.1016/S0278-2391(89)80008-4.

FIGURES

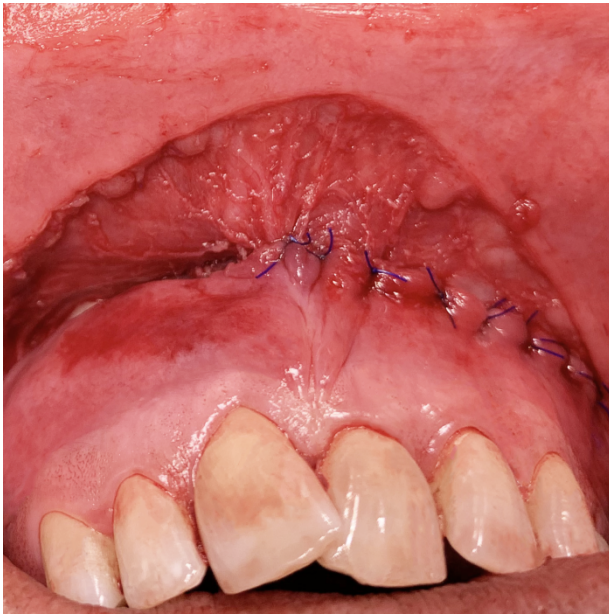

Figure 1. Clinical case of upper lip wound closure with the new technique in a OSA patient. Intraoperative wound closure by suturing the lower edge to the buccal space allowing mucosal metaplasia and vermillion elongation.

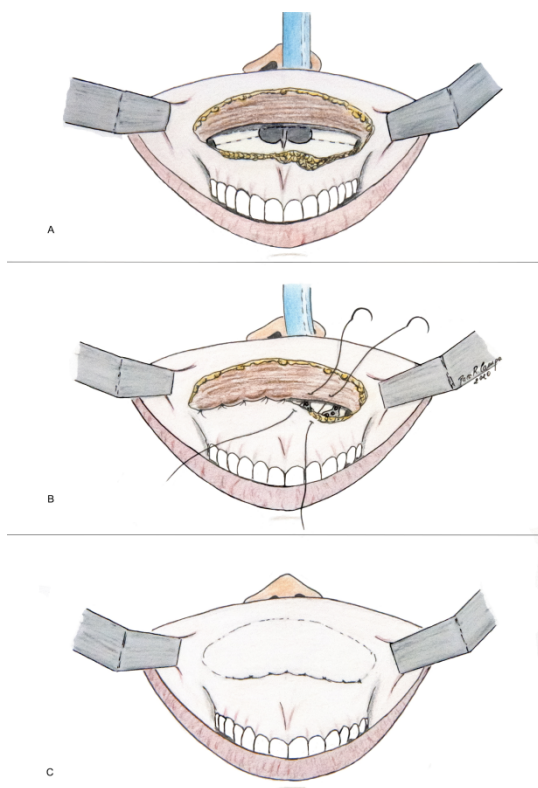


Figure 2. Diagram of the surgical technique. A: wound incision after maxillary osteotomy and fixation; B: wound closure by suturing the lower edge of the incision to the bottom of the buccal space; C: Final closure and mucosal metaplasia.

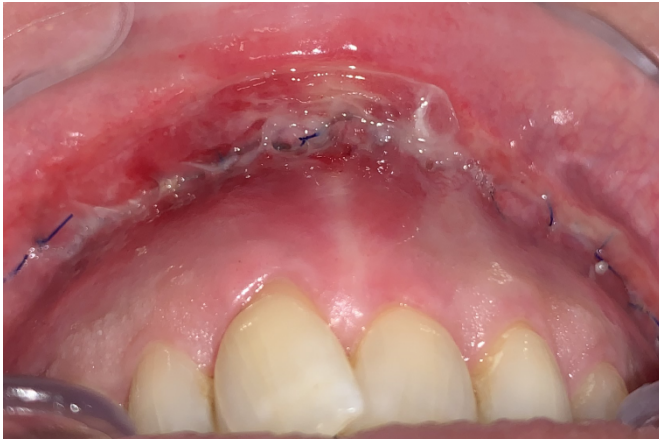

Figure 3. Clinical case of upper lip closure technique. Mucosal metaplasia of the lip mucosa after one-week of postoperative period. Upper lip vermilion elongation can be observed due to this suture.

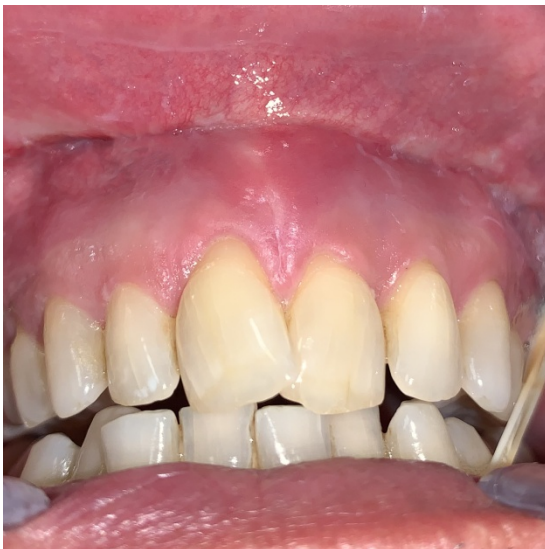

Figure 4. Upper lip metaplasia observed after one month of postoperative period.

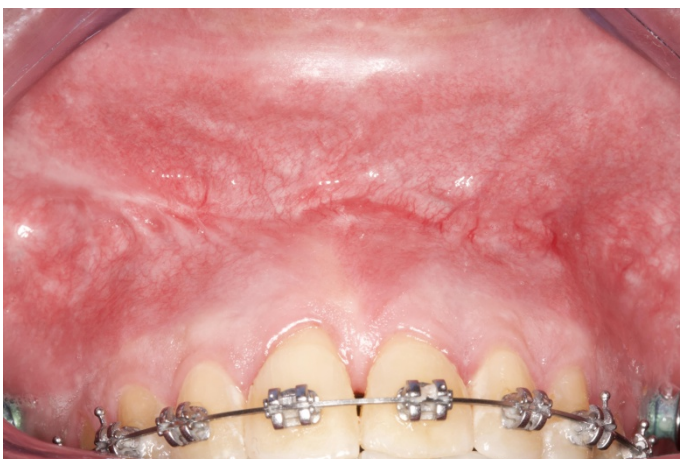

Figure 5. Final result and complete metaplasia one year after surgery. Patient underwent postsurgical orthodontic treatment after double-phase OSA procedure.