

Caso clínico

An unusually large peripheral giant cell granuloma: a case report

Daniela Muela Campos^a, Jorge Andrés Díaz Moreno^a, Hansel Gómez Arambula^b
and Mildred Gabriela Hernández Martínez^c

^aLaboratorio de Patología y Medicina Bucal, Facultad de Odontología, Universidad Autónoma de Chihuahua. Chihuahua, México.

^bServicio de Cirugía Maxilofacial, Hospital General "Dr. Salvador Zubirán Anchondo". Chihuahua, México. ^cCentre for eye research Ireland, Technological University Dublin. Dublín, Irlanda

INFORMACIÓN DEL ARTÍCULO

Historia del artículo:

Received: July 4, 2019

Accepted: October 24, 2019

Keywords:

Peripheral giant cell granuloma, multinucleated giant cells, pyogenic granuloma, giant cell epulis.

Palabras clave:

Granuloma periférico de células gigantes, células gigantes multinucleadas, granuloma piógeno, épulis de células gigantes.

A B S T R A C T

Peripheral giant cell granuloma (PGCG) is a benign reactive lesion of the oral cavity. Although PGCG is classified as a tumor-like lesion, it does not represent a true neoplasm, however it is often associated with a response of local irritation and trauma. Clinically, it appears as an exophytic growth with either sessile or pedunculated base, it can be located in gingiva or edentulous alveolar mucosa and usually does not exceed two cm in diameter. The following report describes the case of a 64-year-old female diagnosed with a PGCG of a particularly large size and rapidly evolving, located in the upper jaw area. The lesion was completely excised, and the diagnosis was confirmed by histopathology, there is no apparent recurrence in the area after 12 months of follow-up. A few cases of PGCG greater than 5 cm in diameter have been reported. Furthermore, exceptional cases might present an abnormal rapid growth as well. An opportune diagnosis based on clinical examination, radiographic and histopathological study are fundamental for a prompt and efficient treatment.

Granuloma periférico de células gigantes inusualmente grande: reporte de un caso

R E S U M E N

El granuloma periférico de células gigantes (GPCG) es una lesión reactiva benigna de la cavidad oral en respuesta a una irritación local o a un traumatismo crónico. Si bien es una lesión de aspecto tumoral, no constituye una verdadera neoplasia. Se manifiesta como un crecimiento exofítico de base sésil o pediculada, localizado en encía o procesos alveolares edéntulos y no suele sobrepasar los 2 cm de diámetro. El presente reporte describe el caso

*Autor para correspondencia:

Correo electrónico: dmuela@uach.mx (Daniela Muela Campos).

DOI: [10.20986/recom.2020.1083/2019](https://doi.org/10.20986/recom.2020.1083/2019)

1130-0558/© 2020 SECOM. Publicado por Inspira Network. Este es un artículo Open Access bajo la licencia CC BY-NC-ND (<http://creativecommons.org/licenses/by-nc-nd/4.0/>).

de un GPCG de tamaño anormalmente grande y rápida evolución localizado en la zona del maxilar superior en un paciente femenino de 64 años. La biopsia escisional de la lesión confirmó el diagnóstico de GPCG y a 12 meses de seguimiento no se ha presentado recidiva. Se han reportado algunos casos de GPCG de más de 5 cm de diámetro. Además, casos excepcionales también pueden presentar un crecimiento rápido anormal. Un diagnóstico oportuno basado en el examen clínico, radiográfico e histopatológico es fundamental para un tratamiento rápido y eficaz.

INTRODUCTION

The peripheral giant cell granuloma (PGCG) is considered a reactive lesion, characterized by mononuclear cells and osteoclast giant cells in a vascular stroma outside the bone¹. First described as giant cell reparative granuloma by Jaffe in 1953², PGCG is not considered as a true neoplasm but a hyperplastic reaction to a local irritant stimulus. These lesions occur over a wide age range, affecting mainly women between the fifth and sixth decade of life^{3,4}. PGCG is usually found on any part of the gingiva or alveolar mucosa more specifically in the incisive and canine region of the jaw. Clinically, it arises as an exophytic growth with sessile or pedunculated base, the color fluctuates from pale pink to bluish purple. There might be signs of slight erosion of the adjacent alveolar bone as well as ulceration of the mucosa^{1,4,5}.

The present case report describes the clinical, radiographic and histopathological characteristics of a large PGCG, treated with surgical excision and with no evidence of recurrence at 12 months.

CASE PRESENTATION

A 64-year-old female was referred to pathology service of the faculty of dentistry of the autonomous university of

Chihuahua, Mexico, complaining of having a “small lump for 4 weeks”. The patient mentioned she has been diagnosed with schizophrenia for 40 years, and she is at the moment controlled by multiple antipsychotic medications. She mentioned to have undergone a tooth extraction and after a week she noticed the area was swollen. After extraoral inspection a swelling of the anterior area of the maxilla was identified, which was associated to the previous tooth extraction.

The intraoral examination revealed a single irregularly shaped swelling lesion on the anterior portion of the maxilla of approximately 7 x 5 x 5 cm width-length, reddish in color, firm consistency, ulcerated surface, pedunculated base, defined edges and asymptomatic (Figure 1).

No sign of bone involvement was found in either orthopantomograph or lateral skull x-ray (Figure 1). Based on the clinical and radiographic findings, the following were proposed as a presumptive diagnosis: PGCG, pyogenic granuloma and peripheral ossifying fibroma. Excisional biopsy under general anesthesia was the treatment choice suggested by the surgeon.

There was abundant bleeding during the surgical procedure which was controlled by cauterization using an electrocautery. The adjacent bone showed slight erosion, therefore, conservative curettage was performed.

The histopathological report of the biopsied specimen (Figure 2) identified a benign lesion derived from the mesenchymal lineage, characterized by the diffuse and perivascu-

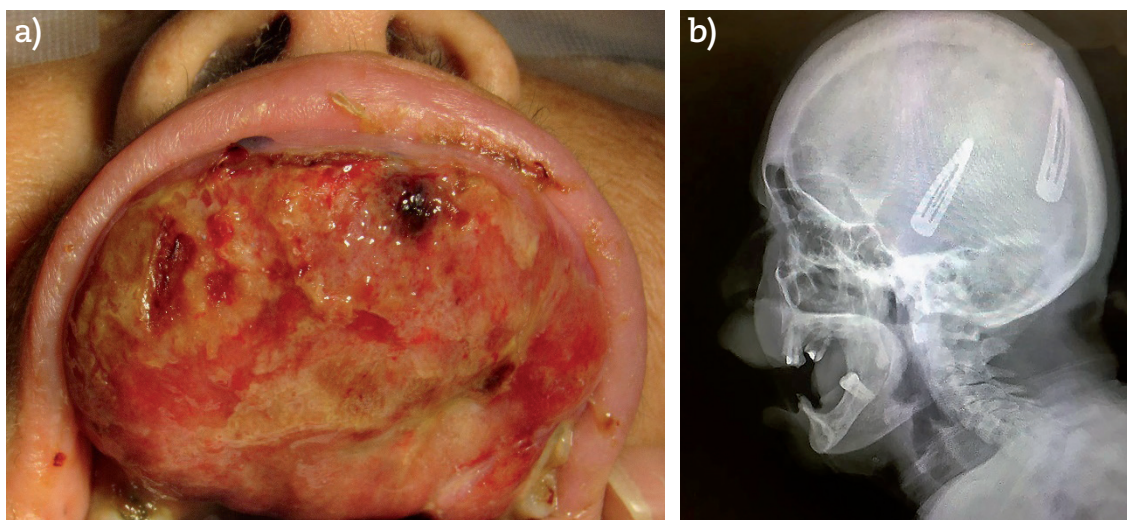


Figure 1. a) Clinical intraoral presentation of swelling site in the anterior area of the maxilla. b) X-ray lateral view of the skull. No evidence of bone involvement.

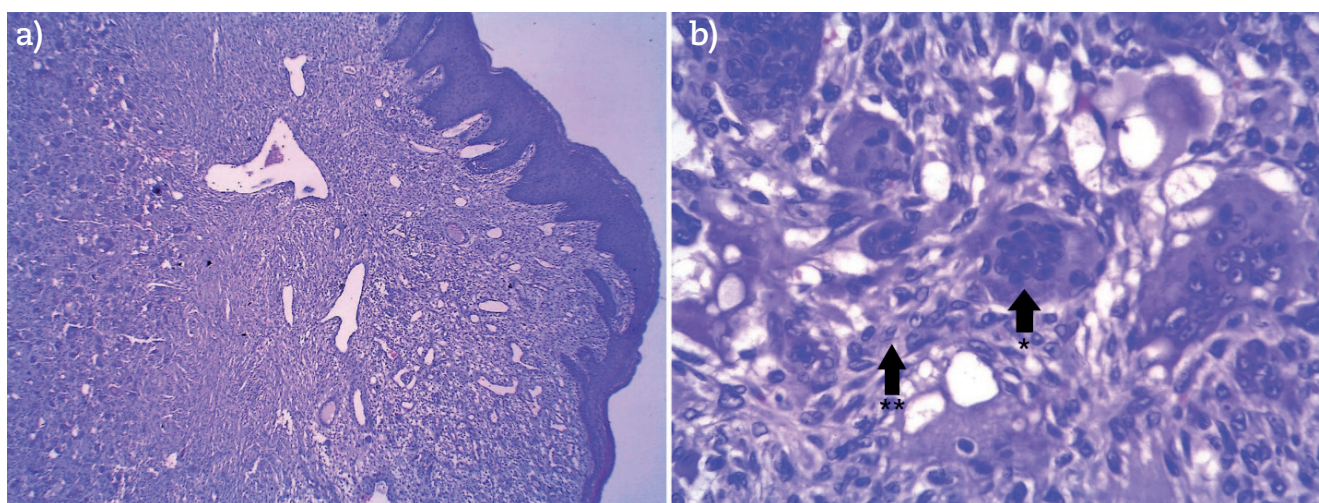


Figure 2. Histopathological micrograph of the PGCG. a) 40 X magnification, benign lesion of mesenchymatous strain. b) 400 × magnification, diffuse and perivascular proliferation of multinucleated giant osteoclast cells (*), arranged on a layer of spindle cells composed mostly of ovoid and fusiform mononuclear cells (**). The lesion had abundant blood vessels and was covered by stratified squamous epithelium.

lar proliferation of multinucleated giant cells (osteoclast-like-cells), arranged on a layer of numerous spindle cells. Additionally, abundant blood vessels were found covered by stratified squamous epithelium. The above histology findings confirmed the diagnosis of PGCG.

DISCUSSION

Due to the high vascularization of the lesion, the risk of bleeding and the mental condition of the patient, which could generate some complication of the procedure, the surgical team decides to perform the excisional biopsy through general anesthesia. In the surgical act, the bleeding control was properly carried out, so this led the surgeon to perform the removal of the lesion in a single surgical time^{3,6}.

Some of the aspects of the PGCG lesion described in this case report such as: age, gender, color and other visible features are very similar to the typical clinical and histological characteristics described elsewhere. However, there are several bone lesions associated with the presence of multinucleated giant osteoclast-like cells, such as central giant cell granuloma, brown tumor of hyperparathyroidism, aneurismatic bone cyst, among others. The main characteristic of these lesions is their intraosseous involvement. The present case showed no bone alteration and with this finding, as well as laboratory studies related to bone metabolism, intra-bone lesions could be ruled out. The PGCG may have bone resorption, but this is commonly limited to the periphery of the alveolar ridge^{5,7}.

There have only been a few reports of PGCG cases which have dimensions greater than 5 cm^{3,6}. For instance, Mannem and Chava described a very similar case in 2012, a 65-year-old patient with a swollen purple lesion located on the left side of the jaw. The reported dimensions were 6 x 5 x 5 cm. The chosen treatment was excisional biopsy during which an

unexpected hemorrhage occurred at the time of extirpation but was easily controlled with cauterization procedures to achieve hemostasis³.

On the other hand, in 2011, Khattry et al. reported a case of PGCG in a 30-year-old male patient, the dimensions of the lesion were 5 x 4.5 cm, in which no complications were encountered during surgical excision⁸.

The etiology of PGCG is still uncertain, however, there have been some factors outlined that are highly associated with its development and growth. In this specific case report, it is presumed that poor oral hygiene, hyposalivation, (which is believed to increase the growth and fast evolution of this lesion) added to various antipsychotic medications (which are known to reduce salivary flow) and the constant irritation of the mucosa caused by smoking, are crucial factors that might have boosted the development and fast growth of the lesion^{1,4,5,9}.

The first-choice treatment is surgical excision with curettage on the base of the lesion and elimination of local factors of irritation, as well as, an important improvement of oral hygiene. The reported recurrence varies from 12% to 16%, which suggests that curettage or conservative peripheral osteotomy should be performed in most of the cases to avoid recurrence of the lesion^{4,10,11}.

The peripheral granuloma of giant cells is a reactive lesion of rapid growth and ulcerated surface, these characteristics can be similar to neoplastic lesions, so the timely and early diagnosis of this type of lesions will allow an appropriate and less invasive management of adjacent tissues¹⁰.

CONFLICTS OF INTEREST

The present investigation has not received specific grants from agencies of the public sector, commercial sector or non-profit entities.

R E F E R E N C E S

1. Wright JM, Vereda M. Update from the 4th Edition of the World Health Organization Classification of Head and Neck Tumours: Odontogenic and Maxillofacial Bone and tumors. *Head Neck Pathol.* 2017;11(1):68-77. DOI: 10.1007/s12105-017-0794-1.
2. Jaffe HL. Giant-cell reparative granuloma, traumatic bone cyst, and fibrous (fibro-osseous) dysplasia of the jawbones. *Oral Surg Oral Med Oral Pathol.* 1953;6(1):159-75. DOI: 10.1016/0030-4220(53)90151-0.
3. Mannem S, Chava VK. Management of an unusual peripheral giant cell granuloma: A diagnostic dilemma. *Contemp Clin Dent.* 2012;3(1):93-6. DOI: 10.4103/0976-237X.94556.
4. Shadman N, Ebrahimi SF, Jafari S, Lick M. Peripheral Giant Cell Granuloma: A Review of 123 cases. *Dent Res J.* 2009;6(1):47-50.
5. Abu Gharbyah AZ, Assaf M. Management of a Peripheral Giant Cell Granuloma in the esthetic area of upper jaw: a case report. *Int J Surg Case Rep.* 2014;5(11):779-82. DOI: 10.1016/j.ijscr.2014.09.014.
6. Said Ahmed W. Efficacy of Ethanolamine Oleate Sclerotherapy in Treatment of Peripheral Giant Cell Granuloma. *J Oral Maxillofac Surg.* 2016;74(11):2200-6. DOI: 10.1016/j.joms.2016.04.025.
7. Maniegas Lozano ML, Giner Díaz J, Ordoñez Soblechero V, González Luque S, García Rielo JM, Martín-Granizo R. Peripheral granuloma of giant cells. *Rev Esp Cir Oral y Maxilofac.* 2006;28(4):231-6.
8. Khatry P, Pradhan P, Ghom S. Peripheral Giant Cell Granuloma: A Case Report and review of Literature. *J Indian Acad Oral Med radiol.* 2011;23(4):638-40. DOI: 10.5005/jp-journals-10011-1240.
9. MirandaRius J, Brunet-Llobet L, Lahor-Soler E, Farré M. Salivary secretory disorders, inducing drugs, and clinical management. *Int J Med Sci.* 2015;12(10):811-24. DOI: 10.7150/ijms.12912.
10. Chrcanovic BR, Gomes CC, Gomez RS. Peripheral giant cell granuloma: An updated analysis of 2824 cases reported in the literature. *J Oral Pathol Med.* 2018;47(5):454-9. DOI: 10.1111/jop.12706.
11. Lester SR, Cordell KG, Rosebush MS, Palaiologou AA, Maney P. Peripheral giant cell Granulomas: A series of 279 cases. *Oral Surg Oral Med oral Pathol oral radiol.* Elsevier INC. 2014;118(4):475-82. DOI: 10.1016/j.oooo.2014.06.004.