

## Original

# Effectiveness of an alveolar molder for correction of nasal collapse in patients with cleft lip

Jessika Arlina González Macías<sup>1</sup>, Marco Antonio Metlich Medlich<sup>2</sup>, Eduardo García García<sup>3</sup>, Ricardo Martínez Rider<sup>4</sup>, Amaury de Jesús Pozos Guillen<sup>5</sup>, Miguel Ángel Noyola Frías<sup>1</sup> y Marco Felipe Salas Orozco<sup>\*6</sup>

<sup>1</sup>Oral and Maxillofacial Surgery Service. Central Hospital Dr. Ignacio Morones Prieto. San Luis Potosí, México. <sup>2</sup>Plastic and Reconstructive Surgery Service. Central Hospital Dr. Ignacio Morones Prieto. San Luis Potosí, México. <sup>3</sup>Maxillofacial Prosthesis Department, Faculty of Stomatology. Autonomous University of San Luis Potosí. San Luis Potosí, México. <sup>4</sup>Maxillofacial Surgeon Department. Faculty of Stomatology. Autonomous University of San Luis Potosí. San Luis Potosí, México. <sup>5</sup>Basic Sciences Laboratory, Faculty of Stomatology. Autonomous University of San Luis Potosí. San Luis Potosí, México. <sup>6</sup>Dental Sciences Department, Faculty of Stomatology. Autonomous University of San Luis Potosí. San Luis de Potosí, México

## INFORMACIÓN DEL ARTÍCULO

Historia del artículo:

Recibido: 09-01-2024

Aceptado: 08-04-2024

Keywords:

Alveolar molder, cleft lip, nasal correction.

## A B S T R A C T

**Objective:** To propose the use of a post-surgical alveolar molder in patients under 4 years of age who have undergone cheiloplasty, aiming for better aesthetic and functional outcomes, using nasal morphometric and photogrammetric studies as measurement references.

**Materials and methods:** This is a before-and-after pilot study conducted at the Oral and Maxillofacial Surgery Service and the Plastic and Reconstructive Surgery Service of Dr. Ignacio Morones Prieto Central Hospital. Patients included in the study were those diagnosed with Cleft Lip and Palate (CLP), presenting clinical data of nasal asymmetry, and aged between 0 and 4 years. An alveolar molder was fabricated using orthodontic wire and self-polymerizing acrylic/monomer according to the size and shape of the patient's nose. The device consists of a wire device with double hooks and a double "V" that will be placed in the frontal region. The evaluation of nasal shape and symmetry was carried out through a photogrammetric study and clinical measurement of nasal height and width.

**Results:** The study included 18 patients, aged between 4 and 39 months, of which 10 presented left-sided clefts, 5 right-sided, and 3 bilateral. The study demonstrated that the use of an alveolar molder in patients with cleft lip and palate resulted in significant improvements in nasal symmetry and morphology, evidenced by increases in vertical and angular dimensions; specifically, the PnC-SarSal distance increased from  $18.61 \pm 1.78$  mm to  $20.50 \pm 1.64$  mm and the height of the right nasal fossa from  $6.97 \pm 1.49$  mm to  $8.22 \pm 1.68$  mm, with notable angular improvements in the Nlr-Midline and Nll-Midline distances.

**Conclusions:** The alveolar molder proposed in this study proved to be a useful tool for improving nasal symmetry and morphology in these types of patients.

\*Correspondence:

E-mail: [marco-salas@hotmail.com](mailto:marco-salas@hotmail.com) (Marco Felipe Salas Orozco).

<http://dx.doi.org/10.20986/recom.2024.1499/2024>

## Efectividad de un moldeador alveolar para corrección de colapso nasal en pacientes con labio hendido

### R E S U M E N

#### Palabras clave:

Moldeador alveolar, labio hendido, corrección nasal.

**Objetivo:** Proponer el uso de un moldeador alveolar postquirúrgico en pacientes menores de 4 años que han sido sometidos a queloplastia, buscando mejores resultados estéticos y funcionales, utilizando estudios morfométricos y fotogramétricos nasales como referencia de medición.

**Materiales y métodos:** Este es un estudio piloto de antes y después, realizado en el Servicio de Cirugía Oral y Maxilofacial y el Servicio de Cirugía Plástica y Reconstructiva del Hospital Central Dr. Ignacio Morones Prieto. Los pacientes incluidos en el estudio fueron aquellos diagnosticados con labio y paladar hendido (LPH), que presentaban datos clínicos de asimetría nasal y tenían entre 0 y 4 años. Se fabricó un moldeador alveolar utilizando alambre ortodóntico y acrílico/monómero autopolimerizante según el tamaño y la forma de la nariz del paciente. El dispositivo consta de un dispositivo de alambre con doble gancho y doble "V" que se colocará en la región frontal. La evaluación de la forma y simetría nasal se llevó a cabo a través de un estudio fotogramétrico y la medición clínica de la altura y el ancho nasal.

**Resultados:** Se incluyeron 18 pacientes, con edades comprendidas entre 4 y 39 meses, de los cuales 10 presentaban hendiduras del lado izquierdo, 5 del derecho y 3 bilaterales. El estudio demostró que el uso de un moldeador alveolar en pacientes con labio y paladar hendido generó mejoras significativas en la simetría y morfología nasal, evidenciadas por el aumento en las dimensiones verticales y angulares; específicamente, la distancia PnC-SarSal incrementó de  $18,61 \pm 1,78$  mm a  $20,50 \pm 1,64$  mm y la altura de la fosa nasal derecha de  $6,97 \pm 1,49$  mm a  $8,22 \pm 1,68$  mm, con mejoras angulares notables en las distancias Nlr-Midline y Nll-Midline.

**Conclusiones:** El moldeador alveolar, propuesto en este estudio, demostró ser una herramienta útil para mejorar la simetría y la morfología nasal en este tipo de pacientes.

## INTRODUCTION

Within congenital malformations, cleft lip and palate are the third most common in Mexico. This alteration can cause problems in chewing, swallowing, speaking, aesthetics, social adaptation, and even the psychological development of the patient<sup>1,2</sup>. In patients who have had their cleft lip repaired, the nose, rather than the lip, reflects most of the original deformity despite attempts to address it during primary surgical intervention<sup>3</sup>. The challenge of treating the associated nasal defect has motivated the introduction of many non-surgical procedures before and after surgery to redirect the growth of the structures involved in the malformation and shape them to facilitate plastic repair. Although there is no established specific type, the nasal stent has been successfully used to prevent secondary deformity due to scarring, which tends to collapse the nasal framework before it consolidates. These conditions frequently occur in craniofacial deformities, nasal trauma, and pathological reconstructions<sup>4</sup>.

Evaluation of nasal shape and symmetry is essential and requires meticulous inspection; different evaluation methods have been described, including photogrammetry and the use of Farkas & Posnick body marking techniques in 1991<sup>5</sup>. Additionally, nasal shaping is based on the plastic-

ity and elasticity of the patient's cartilage in the first few months of life<sup>6</sup>. The use of Koken conformer, which comes in different sizes to choose the ideal one according to the patient's age and size, is commercially available in certain countries, but obtaining it is not easy or cheap in Latin-American countries<sup>7,8</sup>.

The present study was carried out to propose the use of an alveolar molder after cheiloplasty, either immediately or long-term after the initial surgical treatment, in patients under 4 years old, seeking better aesthetic and functional results evaluated using nasal morphometric and photogrammetric studies.

## MATERIALS AND METHODS

The study design was a pilot study of before and after. The study was carried out in the Oral and Maxillofacial Surgery Service and the Plastic and Reconstructive Surgery Service of the Central Hospital Dr. Ignacio Morones Prieto. Approval was obtained from the ethics and research committee of the Central Hospital Dr. Ignacio Morones Prieto, registration number 79-15. This study was conducted according to the World Medical Association Declaration of Helsinki. The study subjects were patients diagnosed with Cleft Lip and Palate (CLP) with clinical data of nasal asymmetry,

and aged 0-4 years during the period from December 2014 to January 2016. The inclusion criteria were patients of any sex diagnosed with uni or bilateral CLP, patients who have undergone cheiloplasty (the cheiloplasties were performed by different maxillofacial surgeons), and patients under 4 years of age whose legal representative accepted the treatment. The exclusion criteria were: patients without CLP diagnosis, patients with isolated palatal cleft, patients over 4 years of age, and patients whose legal representative does not accept the treatment. The elimination criteria were: patients who decided to abandon the treatment and patients with an anaphylactic response to the components of the nasal molder.

**Alveolar molder**

A clinical history was elaborated for the study participants with the evaluation of the type of CLP, and legal guardians or representatives signed an informed consent form. The participant’s patient data and anatomical evolution were recorded on a data collection sheet according to the nasal marking of Krisztián Nagy (Figure 1 and Table I)<sup>9</sup>. After the initial patient evaluation, a photographic series was taken, including frontal, lateral, and caudal-cephalic facial photos. After clinical measurement of nasal height and width, the photogrammetric study was performed by digital placement of a protractor and specific lines that helped us analyze the nasal structures in terms of size and angles (Figure 2.A and Figure 1). The morphology of the nostrils was evaluated considering vertical, horizontal, and angular parameters based on those proposed by Krisztián Nagy et al. and described in Table I and Figure 1.

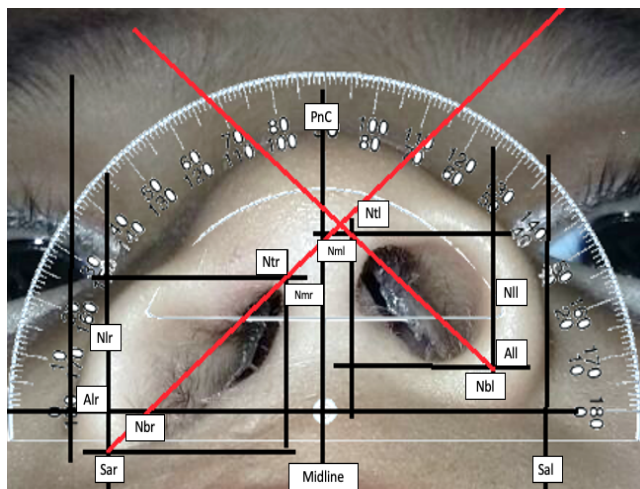


Figure 1. Reference points and intranasal constructs (nasal fossae).

PnC: pronasal construct. Alr: right ala. All: left ala. Sar: right sub-ala nasal. Sal: left sub-ala nasal. Nbr: right nasal base. Nbl: left nasal base. Nmr: right medial nasal fossa. Nml: left medial nasal fossa. Nlr: right lateral nasal fossa. Nll: left lateral nasal fossa. Midline: midline.

**Table I. Measurements taken to evaluate the efficacy of the alveolar molder.**

Vertical parameters	
PnC-SarSal	Projection of the nasal tip, distance between the PnC and the line connecting the Sa points on the right and left sides of the nose (perpendicular to the SarSal line)
Ntr-Nbr	Height of the right nasal fossa, distance from the tip of the nasal fossa to the base of the nasal fossa
Ntl-Nbl	Height of the left nasal fossa, distance from the tip of the nasal fossa to the base of the nasal fossa
Horizontal parameters	
Alr-All	Total width of the nose. Inter-alar distance, line connecting the alar points on the right and left sides of the nose
Sar-Sal	Width of the base of the nose. Distance between the alar insertion points on the right and left sides of the nose
Alr-Midline	Distance from the lateral edge of the right nasal fossa to the midline
All-Midline	Distance from the lateral edge of the left nasal fossa to the midline
Nmr-Nlr	Width of the right nasal fossa, distance between the medial and lateral walls of the right nasal fossa
Nml-Nll	Width of the left nasal fossa, distance between the medial and lateral walls of the left nasal fossa
Angular parameters	
Nlr-Midline	Distance of the right nasal fossa to the midline
Nll-Midline	Distance of the left nasal fossa to the midline

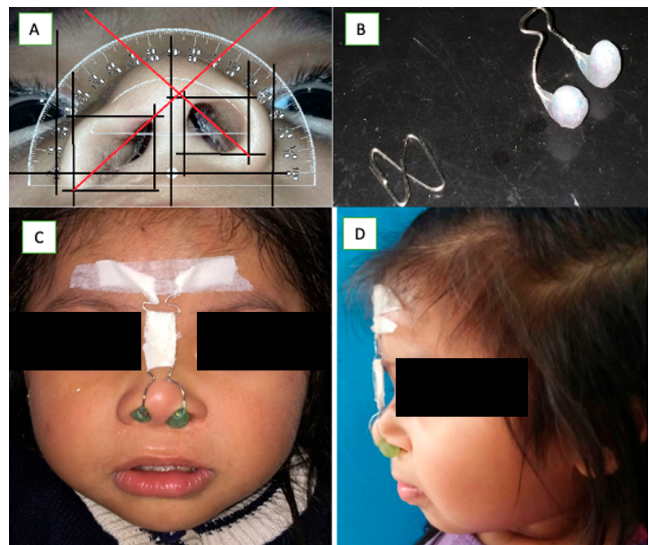

Figure 2. A: Digital marking. B: alveolar molder and frontal traction attachment. C and D: alveolar molder in position and function during frontal traction.

The patient was scheduled to receive the alveolar mold one week later (Figure 2.B). The alveolar mold was elaborated using orthodontic wire #38 and self-polymerizing acrylic/monomer (NIC/TONE) according to the size and shape of the patient's nose. The device consists of a double hook adequately covered with acrylic to avoid injuring the nasal dome, as well as a double "V" wire device, which will be placed in the frontal region. The size of the nasal bulbs was determined after measuring the height and width of the patient's affected nostril, forming an acrylic sphere that is thinned and surrounds the area corresponding to the upper edge of the nostril to avoid compression with the wire (Figure 2.C and D).

### Placement of the alveolar mold

The nasal and frontal area were aseptically prepared, and then benzoin tincture was applied to the patient's forehead. Once dry, the double "V" device was placed with 3M skin adhesive tape in the center of the forehead. Another adhesive tape was placed on the bottom of the device and fixed to the nasal hook by applying traction, which was fixed when nasal dome elevation was noticed without presenting ischemia. This initial placement was performed by explaining step by step to the patient's legal guardians so that they could change the adhesives and clean the nasal area and the device. Benzoin tincture was used to keep the frontal adhesive in place for 7 days. The adhesive tape should be removed by moistening to avoid damaging the patient's skin. Patients were instructed to remain without the device for 12 hours and then replace it. In addition, patients were instructed to remove the device during the night. Monthly follow-up was conducted for 4 months to evaluate results using control photos, modifying the device, if necessary, with increases in acrylic and/or modification of the hook angle, as well as replenishing benzoin tint or adhesive tape to those patients who no longer had enough to continue treatment. After 4 months, the alveolar mold was removed and the patient was scheduled for another appointment 3 months later to evaluate the permanence of nasal adaptation, through a new photographic session to collect data and compare the initial data and the changes after the period of device use. The morphometric and photogrammetry evaluation, nasal molding, and follow-ups were performed by the same maxillofacial surgeon.

### Statistical analysis

Analyses were performed in three vectors: horizontal, vertical, and angular, which were captured at the beginning of the study and the end of the 3-month control period. Continuous qualitative variables will be reported using the mean and standard deviation. The normality of the data was determined using the Shapiro-Wilks test. Significant differences between the measurements before and after were analyzed using the Wilcoxon rank test. Statistical significance was determined as  $p < 0.05$ .

## RESULTS

The study included 18 patients, 9 of whom were female and 9 males. In terms of cleft lip and palate incidence, 10 were left-sided, 5 were right-sided, and 3 were bilateral. The age range of

the patients was 4 to 39 months, with a mean of 15.9 months and a median of 9 months. The vertical parameters PnC-SarSal and Ntr-Nbr had a statistically significant difference at the end of the treatment period. Likewise, the results of these parameters had an effect size of -0.96 and -0.43, respectively, indicating a moderate and large clinical effect.

The angular parameters Nlr - Midline and Nll - Midline, which evaluate the distance from the nostrils to the midline, also showed a significant increase at the end of the treatment, likewise, these results had an effect size of -0.77 and -0.71, respectively, which also indicates a large clinical effect. The results of the measurements and analysis of the horizontal, vertical, and angular vectors are summarized in Tables II, III and IV.

**Table II. Vertical evaluation of nasal cavities.**

Vertical evaluation from nasal tip to base				
N	PnC-SarSal (Initial)	PnC-SarSal (Final)	p	Effect size
18	18.61 ± 1.78	20.50 ± 1.64	0.003*	-0.96
Vertical evaluation of height of right nostril				
N	Ntr-Nbr (Initial)	Ntr-Nbr (Final)	p	Effect size
18	6.97 ± 1.49	8.22 ± 1.68	0.03*	-0.43
Vertical evaluation of height of left nostril				
N	Ntl-Nbl (Initial)	Ntl-Nbl (Final)	p	Effect size
18	6.5 ± 2.45	7.44 ± 1.76	0.08	---

\*p values < 0.05.

**Table III. Horizontal Evaluation of the Nasal Cavities.**

Alr-All			
N	Initial	Final	p
18	35.47 ± 3.71	35.25 ± 3.73	0.82
Sa-Sal			
N	Initial	Final	p
18	29.11 ± 4.28	28.64 ± 4.66	0.73
Alr-Midline			
N	Initial	Final	p
18	18.0 ± 1.91	17.78 ± 1.84	0.82
All-Midline			
N	Initial	Final	p
18	18.14 ± 1.94	18.42 ± 2.04	0.726
Nmr-Nlr			
N	Initial	Final	p
18	9.67 ± 2.63	9.30 ± 2.29	0.59
Nml-Nll			
N	Initial	Final	p
18	11.22 ± 2.56	10.92 ± 2.54	0.81

\*p values < 0.05

**Table IV. Angular evaluation, axis of right and left nasal cavity.**

Right Nasal Cavity				
N	Nlr-Midline (Initial)	Nlr-Midline (Final)	p	Effect size
18	45.28 ± 11.03	60.0 ± 11.01	0.002*	-0.77
Left Nasal Cavity				
N	Nll-Midline (Initial)	Nll-Midline (Final)	p	Effect size
18	45.28 ± 11.03	53.83 ± 8.43	0.01*	-0.71

\*p values < 0.05

Of the 18 patients who participated in this study, none had an allergic reaction to the adhesive or nasal ulcers from contact with the acrylic. Only 3 patients had lacerations on the edge of the nostril due to contact and pressure with the wire, which was immediately covered with acrylic, leading to improvement. It was not difficult for the caregivers to learn how to manage the alveolar mold from its placement to the way of cleaning. Frontal adhesion was highly beneficial, as none of the devices were lost in case of nasal dislodgment, and the patients showed rapid acceptance of it.

## DISCUSSION

Nasal deformity has stimulated a lot of interest in the literature due to the difficult task of achieving a good result with normal function and development. Treatment regimens have ranged from non-surgical means to extensive surgical procedures. Non-surgical treatment to reorient nasal cartilage and soft tissues through the use of nasal conformers has been reported by Matsuo and Hirose<sup>10</sup>. Primary nasal correction is considered the standard of care by many surgeons, but the debate on how and when to apply it continues. Wolfe et al. stated in 2000 that achieving an anatomically and symmetrically correct nasal correction would be difficult. On one hand, there seems to be agreement on the benefits of primary nasal correction in cleft patients among experienced surgeons. However, there is no agreement on a standard for reporting the aesthetic results of nasal surgery; therefore, it remains difficult to compare results from studies with different methodologies and thus, it cannot be identified if one method is more effective than another<sup>9,11</sup>. Therefore, despite years of research and different surgical techniques as well as non-surgical techniques using nasal conformers, a gold standard has not been found to date to achieve proper nasal conformation and symmetry. Throughout history, we have found numerous types of conservative techniques to achieve the optimal result, configured from various materials, from acrylics, silicones, and expansion screws; to spongy materials used at different stages of the patient's life<sup>12</sup>.

This study included patients born in our hospital, a reference center for CLP (cleft lip and palate), or referred from regional hospitals, mainly from the endemic region of the Huasteca, covering states such as Tamaulipas, Hidalgo, Veracruz, Querétaro, Puebla, and San Luis Potosí. Factors such as

consanguinity, lack of gynecological care, early alcoholism, and age disparity between parents contribute to a high incidence of CLP in this jungle and remote area. The most used cleft lip repair techniques in our hospital are Tenison-Randall and Millard, preferring Millard for cases with a small lip volume for its flexibility in flap extension, though with higher risks if improperly designed. Millard is also easier for trainee surgeons to learn. We use passive nasal conformers immediately after cleft lip repair, followed by active conformers starting from the first year of life. Our treatment protocol begins with cleft lip repair at 2 months of age, followed by soft palate correction between 5 and 8 months, and finally, palatoplasty from 18 months onwards.

The use of nasal stents to maintain the new morphology achieved with primary rhinoplasty is a common procedure in many centers for the treatment of cleft patients. Its use also ensures proper positioning of the cartilage during the scar contraction phase in the immediate postoperative period<sup>13,14</sup>. Cenzi and Guarda used the application of a nasal splint immediately after primary cheilorhinoplasty, but in these cases, the device was too large and expansion was obtained by using a periodically activated omega-shaped spring. Pediatric patients were unable to tolerate the device and continuously attempted to remove it. Therefore, it was decided to limit the use of the nasal splint to a later age period, after secondary surgery had taken place, such as columella elongation, starting at the age of 4 or 5, when the patient was more cooperative. This dynamic nasal splint has been used for more than 7 years in Italy, without producing any type of complication or pressure ulcers<sup>15</sup>.

Cobley et al. (2000) reported the manufacture of preformed splints from a silicone elastomer produced in various sizes (Koken splints). Parents reported a tendency for these splints to loosen and fall off, as well as to retain dry and unhygienic mucous secretions. Therefore, a modification was made by using a mold to form two butterfly wings attached to the columellar bridge and fixed by suture or adhesive tape, reporting successful results<sup>16</sup>. Bezuhy, in 2014, reported that the use of a nasal conformer made from oxygen cannula nasal tips arose from dissatisfaction with the conformers available on the market. This conformer was used after primary lip surgery and nasal repair and served to maintain the correction of the alar rim by preventing contraction during the healing process<sup>17</sup>.

This study arose from the observation of nasal collapse on the affected side in patients after primary cheiloplasty, with the nasal fossa appearing flattened and poorly permeable for the patient's breathing. Seeking to improve permeability and increase the longitudinal and angular dimension of the affected nostril, whether unilateral or bilateral labial-nasal defect, the idea of an attachment to increase the height, and permeability, and improve the angular axis was developed. According to the literature, the pediatric age of less than 5 years is often complicated by a lack of patient cooperation and a tendency to remove the attachment; therefore, a way to make it fixed or difficult to remove was sought. Hence, the idea of attaching it to the forehead with adhesives and giving sufficient tension to correct the nasal defect emerged, which was subjective, as the parameter used was that the conformer should fit and cause elevation of the nostril without causing ischemia<sup>18</sup>.

Although most studies suggest 4 to 6 months of continuous use<sup>19</sup>, other authors like Bezuhy reported that even 1 month of conformer use can be sufficient to allow for adequate healing and maintain the new morphology of the nasal fossa<sup>17</sup>. However, this study showed better results at each follow-up, so one month may be insufficient to achieve better nasal contour. Furthermore, considering Grayson's theory, 4 months of nasal conformer use were sufficient to modify and maintain the nasal anatomical changes. Additionally, the fact that it was solely a cephalic traction conformer favored not depressing the nasal floor, as observed in other studies where dynamic devices with screws were used, which depressed it<sup>20</sup>. However, more studies with larger sample size and longer follow-ups are needed to recommend the use of this type of nasal conformer in the medium and long term.

Using a nasal conformer temporarily (12 hours a day) presents several advantages. Firstly, it allows for intermittent periods where the patient is not subjected to the device, potentially reducing the risk of discomfort or irritation that might be associated with continuous wear. This part-time approach can facilitate better tolerance in patients, especially young children, who may find a permanent device obstructive or uncomfortable.

Additionally, wearing the conformer for half a day may align better with the patient's natural cycles of activity and rest. During waking hours, the conformer can aid in maintaining the desired nasal shape post-surgery when the patient is more active and the risk of disrupting the surgical site is greater. At night, the absence of the conformer may allow for less restricted breathing during sleep, which is crucial for the patient's overall well-being and recovery<sup>10,21</sup>.

However, there are potential concerns regarding respiratory alterations due to the use of nasal conformers. For instance, if the conformer obstructs the nasal passages, it may force the patient to breathe through the mouth, which can lead to dry mouth, increase the risk of respiratory infections, and disrupt sleep. Moreover, in young patients, any obstruction in the nasal airway could be more problematic as they predominantly breathe through their noses. Therefore, it is important to monitor for any respiratory alterations during the use of nasal conformers. If such issues are identified, adjustments should be made, either in the design of the conformer, its wear schedule, or through alternative measures to ensure the patient's airway is not compromised. The benefits of using the conformer should be weighed against the risks of potential respiratory difficulties, and the device should be customized to meet the individual needs of each patient<sup>22,23</sup>. In this study, the parents of the infants included in the research did not report any respiratory anomalies.

The use of alveolar molders in both the pre-surgical and post-surgical context has emerged as an innovative strategy in the management of patients with cleft lip and palate (CLP), offering a comprehensive approach to addressing the deformities associated with this condition. The pre-surgical application of these devices aims to align and prepare the alveolar and nasal tissues for surgical intervention, potentially reducing the complexity of surgical correction and improving aesthetic and functional outcomes. On the other hand, post-surgical use focuses on preserving the results achieved through surgery, minimizing the recurrence of deformities by maintaining proper

nasal symmetry and morphology during the healing and subsequent growth processes. Additionally, it is important to highlight that, although alveolar molders offer significant benefits, they do not replace the need for surgical interventions in cases of CLP. Instead, they should be considered as part of a multidisciplinary approach that includes surgery, orthodontics, and speech therapy, among other treatments, to achieve the best possible outcomes for the patient<sup>24,25</sup>.

This study provides initial insights into the benefits of using post-surgical alveolar molders for young patients with cleft lip and palate, highlighting improvements in nasal symmetry and morphology. However, its findings are tempered by several limitations, including a small and diverse sample size that may affect the generalizability of the results, a before-and-after design without a control group that limits causal inferences, and a short-term follow-up that doesn't fully capture the long-term effectiveness and need for additional treatments. These limitations underscore the necessity for further research with larger samples, more rigorous designs, and extended monitoring to assess the alveolar molder's role more definitively as a supportive treatment for CLP patients.

---

## CONCLUSION

This study provides an alternative technique for the development of a nasal conformer for use after primary cheiloplasty to prevent nasal retractile sequelae. The results of this study indicate that the use of this nasal conformer during the immediate pediatric period after primary cheiloplasty for a period of 4 months was effective in showing a significant increase in height and angulation of the nasal cavities. Therefore, this front-traction nasal conformer showed good short-term results, and patients did not show collapse after the conformer was removed. However, a 100 % correction was not achieved, and patients would need to be re-evaluated in the long term. Therefore, the purpose of this technique is not to replace future surgical procedures, but it can be used as an auxiliary method to improve early nasal conditions and provide better anatomical conditions for future surgical procedures.

---

## CONFLICT OF INTEREST

The authors declare that there is no conflict of interest.

---

## FUNDING

This study was funded by the National Council for Humanities, Science, and Technology (CONAHCYT) of Mexico.

---

## REFERENCES

1. Pannaci T, Arteaga VL, Agell-Sogbe A, Kassam SN, Scott M. Cleft Dental Treatment and Naso-Alveolar Molding. *Global Cleft Care in Low-Resour Settings*. Springer; 2021. p. 353-75.

2. Núñez Martínez JM, Toranzo Fernández JM, Metlich Medlich MA. Férula nasal dinámica en la nariz leporina. *Rev Asoc Dent Mex*. 1999;56(1):5-7.
3. Raymond WT, Ettinger RE, Sitzman TJ, Mercan E. Revisiting the unrepaired unilateral cleft lip and nasal deformity using 3D surface image analysis: a data-driven model and its implications. *J Plast Reconstr Aesthet Surg*. 2021;74(10):2694-704. DOI: 10.1016/j.bjps.2021.03.026
4. Mahajan N, Puri A, Singla A, Kumar D, Sharma S, Sureka S, et al. Nasoalveolar molding: A review. *Int J App Dent Sci*. 2022;8(2):451-4. DOI: 10.22271/oral.2022.v8.i2g.1541
5. Farkas LG, Hajniš K, Posnick JC. Anthropometric and anthroposcopic findings of the nasal and facial region in cleft patients before and after primary lip and palate repair. *Cleft Palate Craniofac J*. 1993;30(1):1-12. DOI: 10.1597/1545-1569\_1993\_030\_0001\_aaafot\_2.3.co\_2
6. He X, Shi B, Kamdar M, Zheng Q, Li S, Wang Y. Development of a method for rating nasal appearance after cleft lip repair. *J Plast Reconstr Aesthet Surg*. 2009;62(11):1437-41. DOI: 10.1016/j.bjps.2008.05.018
7. Shetye PR. Post-surgical nostril retainer in orofacial clefts. En: *Cleft and Craniofacial Orthodontics* [Internet]. John Wiley & Sons, Ltd; 2023 [citado 17 de febrero de 2023]. p. 158-64. Disponible en: <https://onlinelibrary.wiley.com/doi/abs/10.1002/9781119778387.ch12>
8. Arias Candia LF, Florez Valbuena PA, Gomez Pedraza KY, Suarez Rojas V. Eficacia del uso de conformadores nasales en LPH. Revisión temática. Universidad El Bosque; 2022.
9. Krisztián N, Mommaerts MY. Analysis of the cleft-lip nose in submental-vertical view, Part I—reliability of a new measurement instrument. *J Cranio-Maxillofac Surg*. 2007;35(6-7):265-77. DOI: 10.1016/j.jcms.2007.04.010
10. Matsuo K, Hirose T. Preoperative non-surgical over-correction of cleft lip nasal deformity. *Br J Plast Surg*. 1991;44(1):5-11. DOI: 10.1016/0007-1226(91)90168-J
11. Wolfe SA, Podda S, Mejia M. Correction of nostril stenosis and alteration of nostril shape with an orthonostric device. *Plast Reconstr Surg*. 2008;121(6):1974-7. DOI: 10.1097/PRS.0b013e3181712350
12. Wadde K, Chowdhar A, Venkatakrishnan L, Ghodake M, Sachdev SS, Chhapane A. Protocols in the management of Cleft Lip and Palate: A Systematic Review: Running Title: Management of Cleft Lip and Palate. *J Stomatol Oral Maxillofac Surg*. 2022; DOI: 10.1016/j.jormas.2022.11.014
13. Nakajima T, Yoshimura Y, Sakakibara A. Augmentation of the nostril splint for retaining the corrected contour of the cleft lip nose. *Plast Reconstr Surg*. 1990;85(2):182-6. DOI: 10.1097/00006534-199002000-00003
14. Méndez R, López-Cedrún J, Tellado M, Somoza I, Liras J, Sánchez-Abuín A, et al. Conformadores nasales en la rino-plastia primaria del paciente fisurado. *Cir Pediatr*. 2005;18:200-3.
15. Cenzi R, Guarda L. A dynamic nostril splint in the surgery of the nasal tip: technical innovation. *J Cranio-Maxillofac Surg*. 1996;24(2):88-91. DOI: 10.1016/S1010-5182(96)80018-7
16. Cogley T, Orlando A, Page K, Mercer N. Modification of the Koken nasal splint. *Cleft Palate Craniofac J*. 2000;37(2):125-6. DOI: 10.1597/1545-1569\_2000\_037\_0125\_motkns\_2.3.co\_2
17. Bezuhly M. Rapid intraoperative fabrication of an inexpensive, reliable nasal stent for use after primary cleft nasal repair. *Cleft Palate Craniofac J*. 2014;51(5):e110-2. DOI: 10.1597/13-205
18. Padovano WM, Skolnick GB, Naidoo SD, Snyder-Warwick AK, Patel KB. Long-term effects of nasoalveolar molding in patients with unilateral cleft lip and palate: a systematic review and meta-analysis. *Cleft Palate Craniofac J*. 2022;59(4):462-74. DOI: 10.1177/10556656211009702
19. Namdar P, Lal Alizadeh F, Etezadi T, Sadri L, Shiva A. Effect of nasoalveolar molding on nasal symmetry in patients with cleft lip and palate: a systematic review. *J Pediatr Rev*. 2020;8(2):79-92. DOI: 10.32598/jpr.8.2.79
20. Grayson BH, Santiago PE, Brecht LE, Cutting CB. Presurgical nasoalveolar molding in infants with cleft lip and palate. *Cleft Palate Craniofac J*. 1999;36(6):486-98. DOI: 10.1597/1545-1569\_1999\_036\_0486\_pnmiiw\_2.3.co\_2
21. Lee S, Fernandez J, Mirjalili SA, Kirkpatrick J. Pediatric paranasal sinuses—Development, growth, pathology, & functional endoscopic sinus surgery. *Clin Anat*. 2022;35(6):745-61. DOI: 10.1002/ca.23888
22. Coelho TL, Neves JF, Caiado R, Silva LF. Nasal obstruction in a newborn. *NASCER E CRESCER-BIRTH GROWTH Med J*. 2021;30(4):246-8.
23. Alvo A, Villarroel G, Sedano C. Neonatal nasal obstruction. *Eur Arch Otorhinolaryngol*. 2021;278:3605-11. DOI: 10.1007/s00405-020-06546-y
24. España-López AJ, Martínez-Plaza A, Fernández-Valadés R, Guerrero-López C, Cortés-Sánchez R, Medina BG. Tratamiento ortopédico con moldeador nasoalveolar prequirúrgico en la fisura labiopalatina unilateral. *Rev Esp Cir Oral Maxillofac*. 2012;34(4):166-71. DOI: 10.1016/j.maxilo.2012.03.001
25. Murthy PS, Deshmukh S, Bhagyalakshmi A, Srilatha K. Pre surgical nasoalveolar molding: changing paradigms in early cleft lip and palate rehabilitation. *J Int Oral Health JIOH*. 2013;5(2):70.