

Caso clínico

Nasal floor suspension in secondary bone grafting in unilateral cleft repair: technical note

Mercedes Martín Pérez¹, Marta María Pampín Martínez^{1*}, Víctor Dueso Delgado¹,
Elena Gómez García¹ y José Luis Cebrián Carretero²

¹Hospital Universitario La Paz. Madrid, España. ²Hospital La Luz. Madrid, España

ARTICLE INFORMATION

Article history:

Received: 9 de junio de 2021

Accepted: 26 de octubre de 2021

Keywords:

Nasal floor suspension, alveolar cleft, secondary bone grafting.

A B S T R A C T

Introduction: One of the most important surgical steps in secondary alveolar bone grafting of the repair of the nasal floor. Proper separation of the nasal and oral mucosa is of utmost importance in order to provide sufficient and adequate space for the bone graft to be placed. A “pocket” is created where the nasal mucosa represents the “roof” and the oral mucosa the “floor”. This pocket will host the bone graft which will regenerate bone in the cleft in order to offer proper bony support for future orthodontic treatment and rehabilitation. Watertight and accurate suture of the nasal mucosa is a decisive step in this surgical technique, so as to avoid prolapse of the nasal floor into the graft space which will hamper bone graft intake. **Technical note:** We present a technical modification where the nasal mucosa is sutured to the maxillary bone with absorbable sutures to keep the nasal floor in proper suspension and avoid prolapse into the graft.

Conclusions: This is a simple technique that helps improve the symmetry of the nasal fossa and maintains the nasal floor in proper tension to avoid prolapse of soft tissue within the graft, enhancing bone formation. It is important to use this technique alongside with a membrane.

Técnica de suspensión de la fosa nasal en injerto óseo secundario en fisura alveolar unilateral: nota técnica

R E S U M E N

Introducción: Uno de los pasos quirúrgicos más importantes en el injerto óseo alveolar secundario es la reparación de la fosa nasal. La separación adecuada de la mucosa nasal y oral es de suma importancia para proporcionar un espacio suficiente y adecuado para la colocación del injerto óseo. Se crea un “bolsillo” donde la mucosa nasal representa el “techo” y la mucosa oral

Palabras clave:

Suspensión fosa nasal, hendidura alveolar, injerto óseo secundario.

*Correspondence:

E-mail: mpampin@ucm.es (Marta María Pampín Martínez).

DOI: [10.20986/recom.2021.1295/2021](https://doi.org/10.20986/recom.2021.1295/2021)

1130-0558/© 2021 SECOM CyC. Publicado por Inspira Network. Este es un artículo Open Access bajo la licencia CC BY-NC-ND (<http://creativecommons.org/licenses/by-nc-nd/4.0/>).

el “suelo”. Este bolsillo albergará el injerto óseo que regenerará el hueso en la hendidura para ofrecer un soporte óseo adecuado para futuros tratamientos de ortodoncia y rehabilitación. La sutura hermética y precisa de la mucosa nasal es un paso decisivo en esta técnica quirúrgica, para evitar el prolapso del suelo nasal hacia el espacio del injerto, lo que dificultará la supervivencia del injerto óseo.

Nota técnica: Presentamos una modificación técnica donde se sutura la mucosa nasal al hueso maxilar con suturas reabsorbibles para mantener el suelo nasal en suspensión adecuada y evitar el prolapso hacia el injerto.

Conclusiones: Se trata de una técnica sencilla que ayuda a mejorar la simetría de la fosa nasal y mantiene el suelo de la fosa en la tensión adecuada para evitar el prolapso de tejido blando dentro del injerto, favoreciendo la formación ósea. Es importante utilizar esta técnica junto con una membrana.

INTRODUCTION

The primary goal of cleft care is to find balance between optimal functional results and aesthetics while minimizing surgical interventions and complications. Early treatment of cleft anomalies is associated with an improvement in swallowing, hearing and speech impediments compared to other cleft patients¹, but can be linked to facial bony growth disturbances. The timing of the alveolar bone graft is quite variable but is most often related to the development of the maxillary canine root².

Secondary alveolar bone grafting (SABG) was first described by Boyne and Sands in 1972³ and has since become a standard procedure in most centers. The alveolar cleft is repaired by reconstructing both the nasal and oral mucosal linings to create space for a cancellous bone graft and close the oronasal fistula.

One of the most feared complications of SABG is wound dehiscence and bone graft exposure, which can hamper graft survival. Thus, the surgical technique should focus on creating a watertight bone graft pocket to avoid bone contamination.

In this technical note we describe a new bone-anchored suspension of the nasal floor in SABG that aims to enhance bone graft uptake by ensuring a watertight closure, whilst minimizing the risk of secondary fistula and improving symmetry of both nasal fossa.

TECHNICAL NOTE

First the incision is marked and mucoperiosteal flaps are raised. The tissue within the alveolar cleft is dissected separating the nasal and palatal mucosa junction, creating a space for the bone graft. The nasal floor mucosa is identified and used to reconstruct the nasal plane that will become the roof of the pocket. It is dissected and reflected into the nose, out of the cleft and closure of the nasal floor and oral mucosa is performed using simple interrupted absorbable 4-0 polyglactin suture. This suture should be accurate and tension-free.

Once the pocket is ready, the bony defect is packed with cancellous bone chips from a donor site previously harvested (generally iliac crest). Finally, the periosteum of the lateral

mucoperiosteal flap is scored to allow a tension-free advancement and hermetic closure without tension.

We propose the following technical modification where the nasal mucosa is suspended to the anterior maxilla to keep adequate tension. First, a hole is made with a towel clip (Figure 1) in the bone segment either medial or lateral to the cleft, above the root apex and 3 to 4 mm from the cleft edge. Then an absorbable 3.0 suture is passed from the most anterior part of the bigger segment of the previously sutured nasal floor mucosa flap to the hole in the bone, including the previous suture in the loop, and knotted (Figures 2 and 3). Then, a collagen membrane is placed and the gap is filled with the cancellous bone graft under a thin cortical plate. A postoperative CBCT is always performed to assess the result of the SABG.

DISCUSSION

Secondary alveolar bone grafting aims to close the oronasal fistula and obtain anatomical tissue continuity in the alveolar process of the maxilla, which allows the dental arch to be stabilized⁴.

The success rate reported for the alveolar bone graft is 84-91 % among different authors⁵ and has been associated to the eruption status of the canine at the cleft, being greatly improved when the surgery is performed before the dental

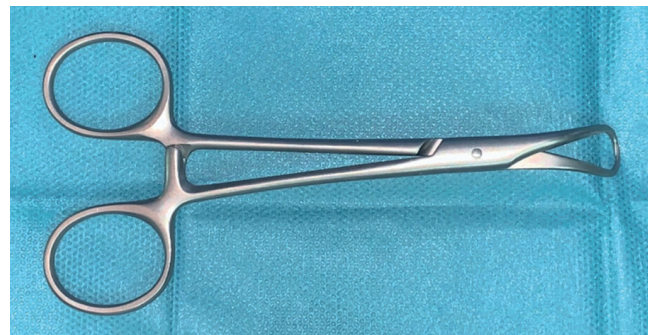

Figure 1. Towel clip used to perforate the bone.

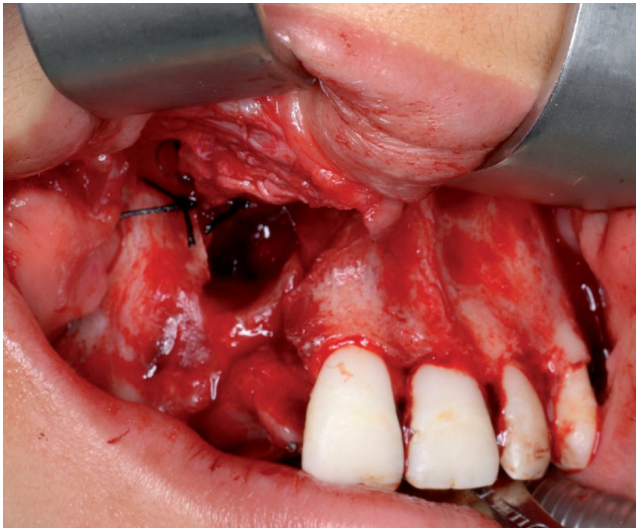


Figure 2. Bone-suture technique.

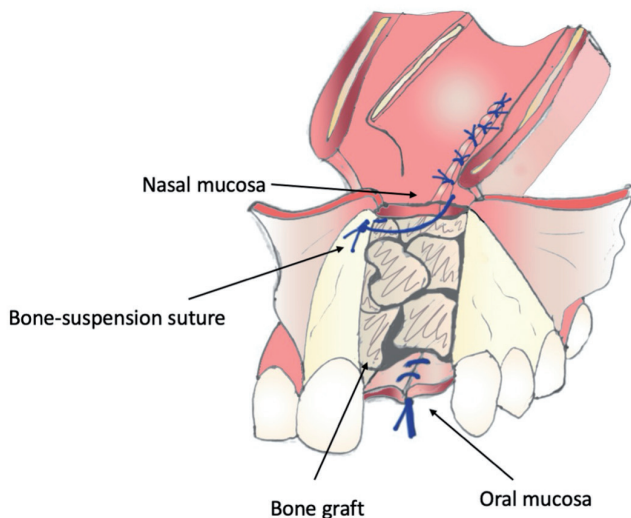


Figure 3. Sketch of the bone-suture technique for nasal floor suspension.

eruption. The study by Jia et al.⁶ showed no significant difference between unilateral and bilateral cleft as long as it was performed previous to dental eruption.

From a technical standpoint, closure of the nasal mucosa in the roof of the pocket is the most demanding part of secondary alveolar bone grafting. Without bone grafting, the nasal floor would prolapse and contact with the palatal mucosa floor. Furthermore, a water-tight isolation of the graft from the nasal and oral cavities is needed to improve graft survival and reduce complications and fistula formation.

The addition of a thin piece of cortical bone at the level of the nasal floor during the alveolar cleft repair has been previously reported and allows separating the nasal mucosa from the cancellous bone graft⁷. This offers support to the nasal plane and avoids displacement of the cancellous bone graft in the nasal cavity.

In this technical note we propose a bone-suspension technique of the nasal floor to the anterior maxilla to keep adequate tension of the nasal plane and improve graft survival. Thus, the nasal floor is elevated to reach a symmetric height to the contralateral side and the alveolar cavity is ready to allow the placement of a thin cortical bone to become the roof of the bone graft, which helps protect its integrity.

With this technical modification we move the nasal floor suture away from the graft to minimize the risk of postoperative dehiscence and the consequent fistula, which can ultimately lead to contamination and loss of the graft. Also, by applying proper tension to the nasal floor, soft tissue redundancy and prolapse into the cleft is reduced and nasal fossa symmetry is improved. With the conventional technique prolapse of the nasal floor can hamper graft survival and reduce the likelihood of success.

With this bone-anchored suspension, we believe we can improve results in secondary alveolar bone grafting. We also suggest that it is important to combine this technique with the use of a collagen membrane for further isolation of the graft and the use of a cortical plate for better nasal floor projection.

Although sometimes there can be a higher amount of fibrous tissue within the cleft, our philosophy is to be conservative with the amount of resected tissue which will become the oral and nasal lining. Additionally, resection or electrocautery of the ipsilateral inferior turbinate may sometimes be necessary to allow proper elevation of the nasal floor without increasing the risk of nasal congestion or future nasal respiratory difficulties.

A very similar procedure was previously reported by an Iranian group as a maneuver to provide a stable base for local nasal flaps in cases with anatomical difficulties involved and wider nasal mucosa defects, around 8.4 % of the cases described⁸. The reasoning behind our bone suture note would be about restoring symmetry and rejecting soft-tissue invasion rather than a maneuver designed to provide tissue to cover a defect when necessary.

As of limitations to this technique, the bone-anchoring nasal floor suspension may limit the overall vertical dimension of the graft if excessive tension is applied. Also, the conclusions drawn in this paper are merely clinical since no observational study has been performed. A clinical series comparing this new technique to the conventional one should be performed to analyze different outcomes such as volume of graft survival, bone resorption, the presence of postoperative fistula and the need for a second SABG procedure to establish firm conclusions.

We believe nasal floor suspension in SABG is a simple and feasible technical modification that can offer better results and should be considered to enhance bone regeneration and minimize the risk of oronasal fistula formation. Further studies and case series are needed to establish its validity.

REFERENCES

- Hopper RA, Tse R, Smartt J, Swanson J, Kinter S. Cleft Palate Repair and Velopharyngeal Dysfunction. *Plast Reconstr Surg.* 2014;133(6):852-64. DOI: 10.1097/PRS.0000000000000184.

2. Cho Lee GY, Garcia Diez EM, Nunes RA, Martí-Pagés C, Sieira-Gil R, Rivera-Baró A. Review of secondary alveolar cleft repair. *Ann Maxillofac Surg.* 2013;3(1):46-50. DOI: 10.4103/2231-0746.110083.
3. Boyne PJ, Sands NR. Secondary bone grafting of residual alveolar and palatal clefts. *J Oral Surg.* 1972;30(2):87-92.
4. Stasiak M, Wojtaszek-Slominska A, Racka-Pilszak B. Current methods for secondary alveolar bone grafting assessment in cleft lip and palate patients: A systematic review. *J Craniomaxillofac Surg.* 2019;47(4):578-85. DOI: 10.1016/j.jcms.2019.01.013.
5. Rawashdeh MA, Al Nimri KS. Outcome of Secondary Alveolar Bone Grafting Before and After Eruption of the Canine in Jordanian Patients With Cleft Lip and Palate. *J Craniofac Surg.* 2007;18(6):1331-7. DOI: 10.1097/scs.0b013e31814e059b.
6. Jia YL, Fu MK, Ma L. Long-term outcome of secondary alveolar bone grafting in patients with various types of cleft. *Br J Oral Maxillofac Surg.* 2006;44(4):308-12. DOI: 10.1016/j.bjoms.2005.07.003.
7. Precious DS. A new reliable method for alveolar bone grafting at about 6 years of age. *J Oral Maxillofac Surg.* 2009;67(10):2045-53. DOI: 10.1016/j.joms.2009.04.102.
8. Rahpeyma A, Khajehahmadi S. The last resort for reconstruction of nasal floor in difficult-to-repair alveolar cleft cases: a retrospective study. *J Craniomaxillofac Surg.* 2014;42(6):995-9. DOI: 10.1016/j.jcms.2014.01.022.