

Caso clínico

Epidermoid cyst of the tongue: two new cases of an extremely uncommon entity

Luiza Roberta Bin*, Jean Carlos Della Giustina y Evelyn Estefani Cristaldo Acosta

Oral and Maxillofacial Surgeon, UOPECCAN. Cascavel Cancer Hospital. Santo Onofre, Cascavel, Parana, Brazil

ARTICLE INFORMATION

Article history:

Received: 08 de noviembre de 2022

Accepted: 23 de enero de 2023

Keywords:

Epidermoid cyst, oral cavity, oral surgery.

ABSTRACT

Epidermoid cyst (EC) is a benign lesion that emerges as a painless and fluctuating increase of volume. EC is a rare injury in the oral cavity and its diagnostic through clinical exams and conventional radiography provides limited results. Thus, the purpose of the current work is to report two cases of rare tongue lesions diagnosed as EC in two adult patients treated surgically. A 65-year old man and a 40-year old woman were complaining of a "little ball" in their tongue. The patients presented tongue lesions in anatomical sites with distinct clinical presentations. The adopted treatment was a resection of the lesion and, after a histopathological analysis, the final diagnostic pointed to an epidermoid cyst. In the current cases, the lesion occurred in the belly and dorsum of the tongue, and both were treated surgically. And so they became the 14th and 15th cases of EC in tongues found in the literature, thus confirming the relevance of the current work.

Quiste epidermoide de la lengua: dos nuevos casos de una entidad extremadamente infrecuente

RESUMEN

El quiste epidermoide (QE) es una lesión benigna que emerge como un aumento indoloro y fluctuante del volumen. Es una lesión rara en la cavidad oral y su diagnóstico a través de exámenes clínicos y radiografía convencional proporciona resultados limitados. Por lo tanto, el propósito del presente trabajo es reportar dos casos de lesiones raras de la lengua diagnosticadas como QE en dos pacientes adultos tratados quirúrgicamente. Un hombre de 65 años y una mujer de 40 años se quejaban de una "bolita" en la lengua. Los pacientes presentaron lesiones en la lengua en sitios anatómicos con distintas presentaciones clínicas. El tratamiento adoptado fue una resección de la lesión y, tras un análisis histopatológico, el diagnóstico final apuntó a un quiste epidermoide. En los casos actuales, la lesión ocurrió en el vientre y el dorso de la lengua, y ambos fueron tratados quirúrgicamente. Así, se convirtieron en los casos 14 y 15 de QE en lenguas encontradas en la literatura, confirmando así la relevancia del trabajo actual.

Palabras clave:

Quiste epidermoide, cavidad oral, cirugía oral.

*Correspondence:

Correo electrónico: luizarbin@protonmail.com (Luiza Roberta Bin).

<http://dx.doi.org/10.20986/recom.2023.1409/2022>

1130-0558/© 2022 SECOM CyC. Publicado por Inspira Network. Este es un artículo Open Access bajo la licencia CC BY-NC-ND (<http://creativecommons.org/licenses/by-nc-nd/4.0/>).

INTRODUCTION

Dermoid cyst (DC) is a rare development derived injury, arising from epithelial rests resulting from the union of the first and second gill arches, and histologically it may be classified as true dermoid cyst, epidermoid cyst (EC), and teratoma¹⁻⁴. When it occurs on the head and neck, it corresponds to up to 7 % of the cases^{1,2,4-6}, and in only 1.6 % of the cases it appears in the oral cavity, and the floor of the mouth is the most affected area^{1,4,5,7}. If compared to all oral cavity cysts, they account for less than 0.01 %³⁻⁷ of the cases.

EC is a benign lesion². It presents non-pathognomonic clinical signs, basically involving an increase of volume^{4,6,7}. They present slow, painless, and fluctuating growth masses⁵. The diagnostic of such lesions through clinical exams and conventional radiography is difficult¹. It is necessary to correctly plan an intervention, with complimentary exams, such as ultrasound (US), computerized tomography (TC), magnetic resonance (RM), and a histopathological exam^{1,6}. Fine needle aspiration cytology (FNAC) is a safe and economic alternative for the pre-surgery diagnostic of CE's; however, it is not possible to determine histological subtypes⁵. Differential diagnostic includes infectious processes, cyst in the thyroglossal duct, cystic hygromas, accumulation of adipose tissue, and neurofibroma and hemangioma⁶.

Treatment involves enucleation, and it may be performed intra- or extraorally, with low recurrence rates³⁻⁵. In addition to that, few cases have been reported in the literature, especially those affecting the tongue⁷. The tongue is a structure that is

difficult to evaluate^{8,9}. Thus, the purpose of the current work is to report a case of rare tongue injury diagnosed as an EC in an adult patient treated surgically.

CASE REPORTS

Case Report 1

A 65-year old man came to the oral and maxillofacial surgery service of Uopecan\Cascavel, complaining about a "little ball" on his tongue. A reddish nodular lesion on the left lateral edge of the tongue was clinically observed, hard to palpation, with a painful symptomatology that had been evolving for 90 days. As diagnostic hypotheses, a squamous cell carcinoma and a traumatic fibroma were suggested. After an incisional biopsy and a histopathological analysis, the result was a non-specific mild chronic inflammatory process, negative for malignancy. It was then decided to perform a full surgical resection of the lesion, under general anesthesia and nasotracheal intubation. The incision was marked (Figure 1A), and an ellipse type incision was performed, approximately 5 x 2 cm long, running from the mucosa up to the upper longitudinal muscle of the tongue (Figure 1B). A dissection of the remaining tissues was performed and then the site was sutured using a Vicryl 3.0 thread, and closed through first intention (Figure 1C). The specimen was sent to histopathological analysis. The histological samples were stained using the hematoxylin and eosin technique (HE). The most relevant microscopic findings are shown below (Figure 2 A, B and C). The final diagnostic pointed to an epidermoid cyst.

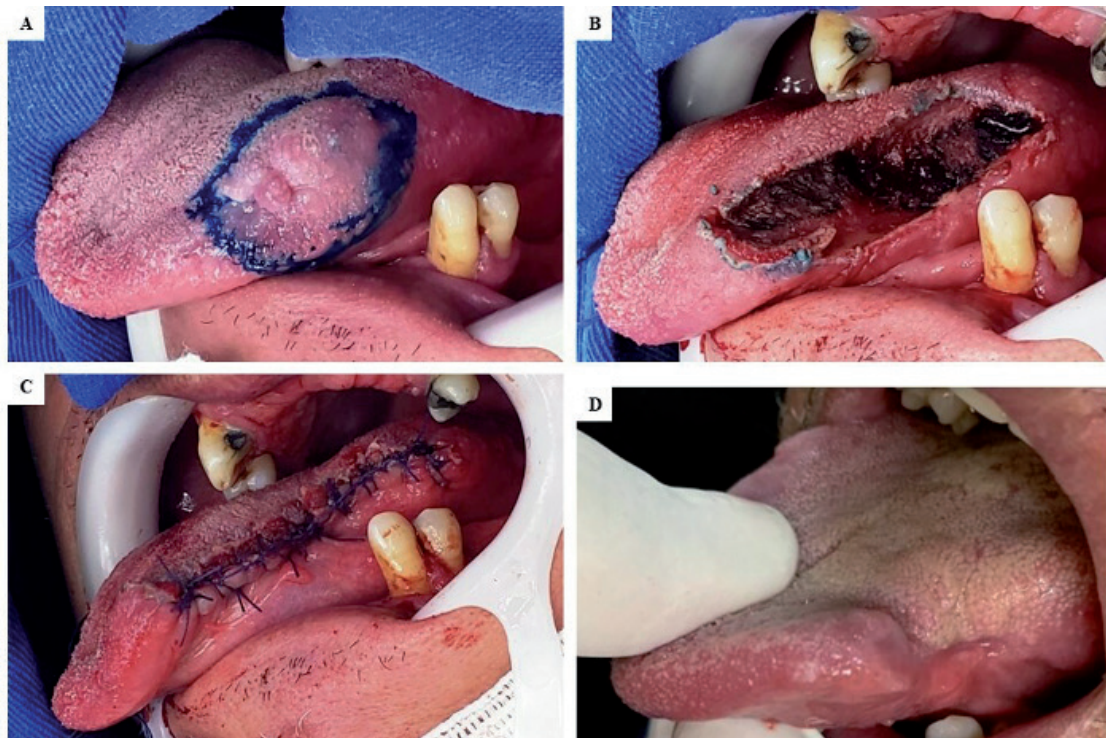


Figure 1. A: marking of the wedge type incision. B: remaining tongue tissue after the excision of the lesion. C: immediate post-surgery state. D: post-surgery state after 1 year.

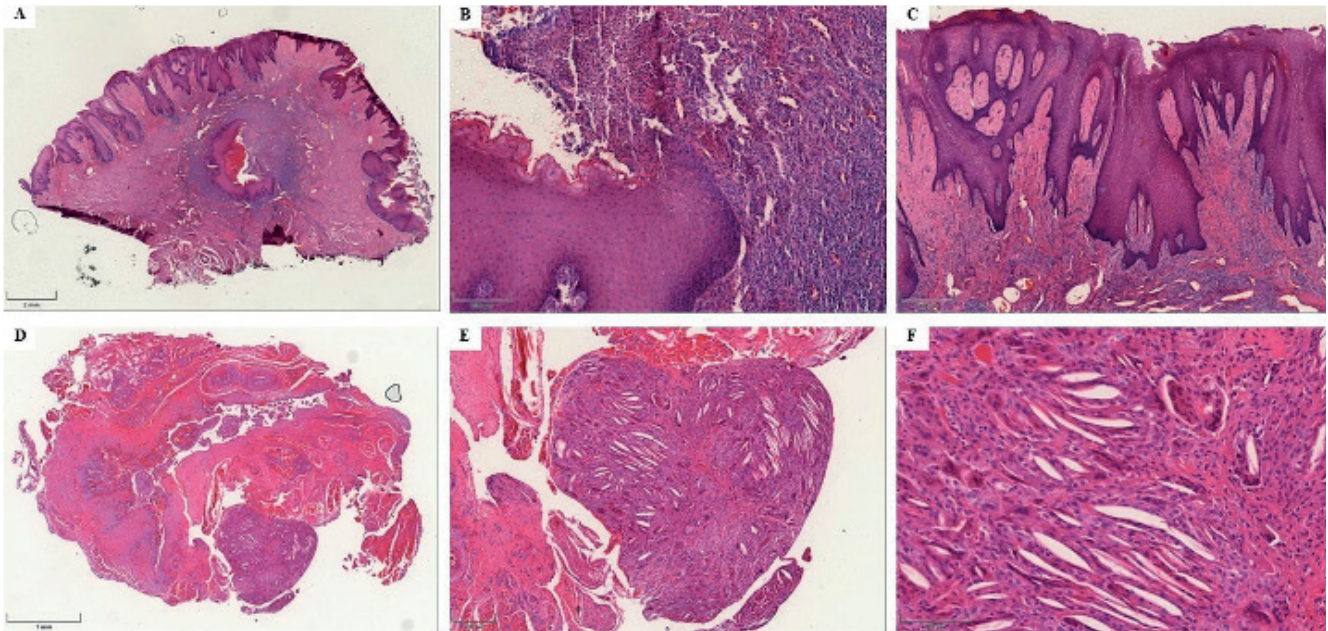


Figure 2. A: panoramic view (focus 8.7) of the central area with partially torn and sore epithelial cyst. B: greater detail (focus 28.5) of the epithelial inclusion cyst, with the cyst transition area and a torn and sore area. C: detail (focus 38.8) of the cyst surface epithelium, with irregular acanthosis. D: panoramic view (focus 26.5), with a fibrous tissue that comprises muscle fibers and pseudocystic spaces in the center, while in the periphery there is a foreign body type granuloma with cholesterol crevices. E: greater detail (focus 75) of the area with a foreign body type granuloma. F: greater detail (focus 249) of the area with a foreign body type granuloma. There are giant foreign body type cells and cholesterol crevices.

During the post-surgery period, the patient did not present any complication and at the 1-year follow-up exam did not make any complaint (Figure 1D). Patient gave informed consent.

Case Report 2

A 40-year old woman came to the oral and maxillofacial surgery service of Uopecan\Cascavel, complaining about a “little ball” on her tongue that had been evolving for 3 months. The clinical exam pointed to a painless increase of volume in the belly of tongue and soft to palpation (Figure 3 A). The patient was submitted to a FNAP (Fine Needle Aspiration Puncture) during which a yellowish liquid was found compatible with the cystic lesion. The liquid was sent to a histopathological exam, which resulted in a cystic content. The patient was submitted to cystic enucleation under general anesthesia (Figure 3 B). The specimen was sent to histopathological analysis (Figure 3 C). The histological samples were stained using the hematoxylin and eosin technique (HE). The most relevant microscopic findings are shown below (Figure 2 D, E and F), and an Epidermoid Cyst was diagnosed. The patient has been under a 3-year follow-up regime, without any complaint (Figure 3 D). Patient gave informed consent.

DISCUSSION

EC is a rare injury in the oral cavity^{7,10}, and it is even much rarer in the tongue^{2,7,10}. Ueno et al. (2018) performed a literature review with the published cases of EC in the tongue and found

just 12 cases of EC, plus the case they were reporting. We have observed that, after that publication, there has been another report of this lesion and its location, by Jain (2019). Thus, the current cases have become the 14th and 15th cases of EC in the tongue found in the literature, thus confirming the relevance of the current work.

Since it involves a lesion without specific characteristics, the diagnostic of this lesion depends on histopathological analysis and may be supported by US in order to determine its location, extension, and relationship with the adjacent structures⁷. In the current case, the patient was submitted to an incisional biopsy and presented a histopathological condition involving a mild non-specific chronic inflammatory process, negative for malignancy, and was then submitted to a full resection of the lesion, with a final result of the histopathological analysis indicating an EC in the tongue.

This pathology might affect children and adults, and in the study undertaken by Ueno et al. (2018) and Jain (2019), these authors found a higher prevalence of occurrences in children, with 9 cases out of the 13 studied ones. The highest manifestation in children might be related to the congenital etiological theory, according to which the surface ectoderm fails to separate from the subjacent neural tube, or from the surface ectoderm invagination along the embryological fusion sites during the embryonic stage^{1,2,5,10}. Our patient is an exception, considering that he was a 65-year old adult. The age of the patient has also led us to correlate the etiology of his lesion as possibly being a trauma, pointing to the acquired type theory, which is related to traumas^{5,7,10}. However, there is no clinical or histopathological difference between both types¹⁰.

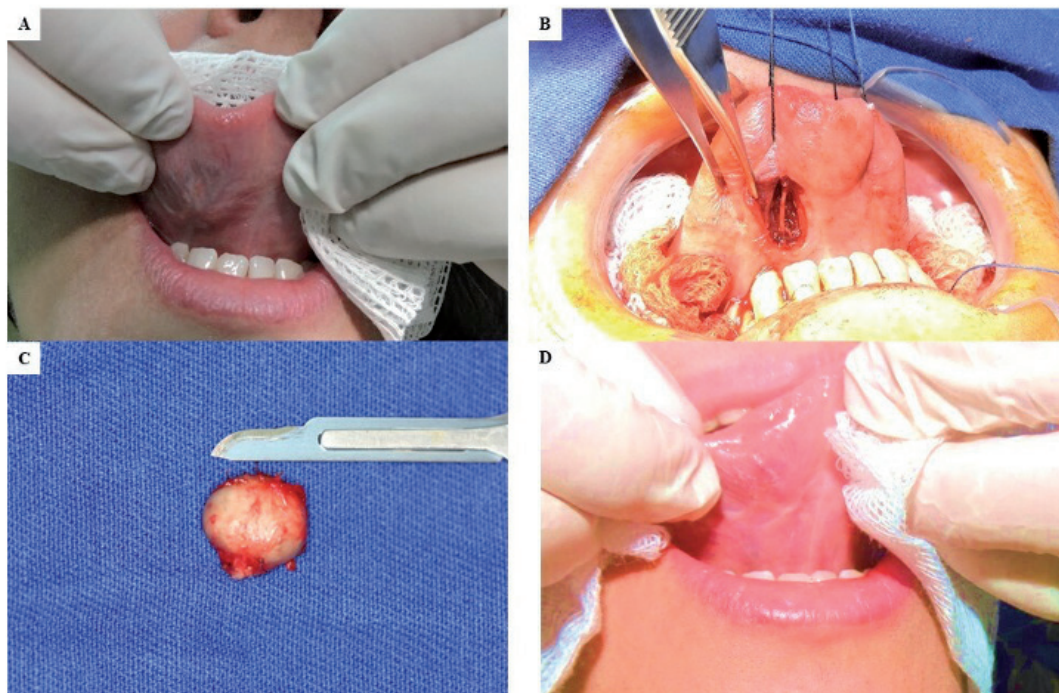


Figure 3. A: initial clinical aspect, pointing to an increase of volume in the ventral surface of the tongue. B: transurgical moment, with removal of the lesion and preservation of noble anatomical structures. C: specimen. D: 3-year follow-up, without any lesion recurrence sign.

Treatment is based on surgical excision^{3,4}. It is important to perform it, since the growth of the lesion might lead to an obstruction of air passages², making it difficult to breathe^{2,6,7}, including dysphonia, dysphagia, dysarthria, with interference on chewing, moving the tongue, and speech⁴⁻⁷. And 5 % of the lesions might become malign lesions^{1,3,4}. Thus, the indication to fully remove it was rather correct, since the lesion had been growing and thus causing increasing distress to the patient, which might evolve into the above mentioned consequences.

CONCLUSION

Epidermoid cyst in the oral cavity is a rare disease, which may clinically manifest itself in many different forms. Although image exams help to diagnose it, incisional biopsy and/or FNAP are highly valuable to ensure a definitive diagnostic. The standard golden treatment is a full surgical resection of the lesion. In the current cases, the lesion occurred in an uncommon age group, and was treated surgically.

DISCLOSURE OF FUNDING

The authors disclosed receipt nonfinancial support for the research, authorship, and/or publication of this article.

PUBLICATION ETHICS

The authors confirm that they have the informed consent of the patients.

REFERENCES

- Sahoo NK, Choudhary AK, Srinivas V, Tomar K. Dermoid cysts of maxillofacial region. *Med J Armed Forces India*. 2015;71(0):S389-94. DOI: 10.1016/j.mjafi.2013.11.004.
- Akinbami BO, Omitola OG, Obiechina AE. Epidermoid Cyst of the Tongue Causing Airway Obstruction. *J Maxillofac Oral Surg*. 2011;10(4):349-53. DOI: 10.1007/s12663-010-0167-8.
- Anantanarayanan P, Manikandhan R, Bhargava D, Sivapathasundaram B. Sub-lingual epidermoid cyst. *Head Neck Pathol*. 2010;4(2):136-8. DOI: 10.1007/s12105-010-0164-8.
- Kandogan T, Koç M, Vardar E, Selek E, Sezgin Ö. Sublingual epidermoid cyst: A case report. *J Med Case Rep*. 2007;1:1-4. DOI: 10.1186/1752-1947-1-87.
- Puranik S, Puranik R, Prakash S, Bimba M. Epidermoid cyst: Report of two cases. *Journal of Oral and Maxillofacial Pathology*. 2016;20(3):546. DOI: 10.4103/0973-029X.190965.
- Saxena V, Majithia IP. A rare case of epidermoid cyst of tongue. *Med J Armed Forces India*. 2015;71:S564-7. DOI: 10.1016/j.mjafi.2014.01.005.
- Jain M. Epidermoid Cyst of the Tongue — A Rare Case. *Int J Clin Pediatr Dent*. 2019;12(1):80-2. DOI: 10.5005/jp-journals-10005-1594.
- Hiiemae KM, Palmer JB. Tongue Movements in Feeding and Speech. *Crit Rev Oral Biol Med* Downloaded. 2003;14(6):413-29. DOI: 10.1177/154411130301400604.
- Sanders I, Mu L. A 3-Dimensional Atlas of Human Tongue Muscles IRA. *Anat Rec (Hoboken)*. 2013;296(7):1102-14. DOI: 10.1002/ar.22711.
- Ueno T, Takayama R, Osada SI, Saeki H. Epidermoid cyst arising on the body of the tongue: Case report and literature review. *Journal of Nippon Medical School*. 2018;85(6):343-6. DOI: 10.1272/jnms.JNMS.2018_85-56.