

Caso Clínico

Oral carcinoma cuniculatum (OCC): a rare case in a pediatric patient

Álvaro Bretons^{1,2}, Irene Elizalde-Bonafaux³, Jordi Temprana^{4,5}, Jordi Giralt^{6,7},
Montserrat Munill^{1,2}, Jorge Pamias-Romero^{1,2} y Coro Bescós-Atín^{*1,2,8}

¹Servei de Cirurgia Oral i Maxil·lofacial. Vall d'Hebron Hospital Universitari. Vall d'Hebron Barcelona Hospital Campus. Barcelona, Spain. ²CIBBIM-Nanomedicine, Noves Tecnologies i Microcirurgia Craniofacial, Vall d'Hebron Institut de Recerca (VHIR). Vall d'Hebron Hospital Universitari. Vall d'Hebron Barcelona Hospital Campus. Barcelona, Spain. ³Servicio de Medicina Interna. Hospital Universitario de Navarra. Pamplona, Navarra, Spain. ⁴Servei d'Anatomia Patològica. Vall d'Hebron Hospital Universitari. Vall d'Hebron Barcelona Hospital Campus. Barcelona, Spain. ⁵Patologia Molecular Translacional. Vall d'Hebron Institut de Recerca (VHIR). Vall d'Hebron Hospital Universitari. Vall d'Hebron Barcelona Hospital Campus. Barcelona, Spain. ⁶Servei d'Oncologia Radioteràpica. Vall d'Hebron Hospital Universitari. Vall d'Hebron Barcelona Hospital Campus. Barcelona, Spain. ⁷Grup d'Oncologia Radioteràpica. Vall d'Hebron Hospital Universitari. Vall d'Hebron Barcelona Hospital Campus. Barcelona, Spain. ⁸Profesora associada. Facultat de Medicina. Universitat Autònoma de Barcelona. Campus Vall d'Hebron. Barcelona, Spain

INFORMACIÓN DEL ARTÍCULO

Historia del artículo:

Recibido: 05-02-2025

Aceptado: 18-04-2025

Keywords:

Oral carcinoma cuniculatum,
pediatric patient, tongue cancer.

Palabras clave:

Carcinoma cuniculatum oral,
paciente pediátrico, cáncer oral.

ABSTRACT

Oral carcinoma cuniculatum (OCC) is a rare and often misdiagnosed variant of squamous cell carcinoma, with very few cases described in the paediatric population. We report the case of an 11-year-old girl who presented with a progressively enlarging lesion on the right margin of the tongue. Imaging revealed a locally advanced tumour, and histopathological analysis confirmed the diagnosis of OCC. The patient underwent extensive surgical treatment, including subtotal glossectomy, bilateral neck dissection, and reconstruction with a microvascular anterolateral thigh flap. This case highlights the importance of recognizing OCC in young patients, the role of accurate histopathological diagnosis, and the potential for curative treatment with surgery alone, even in advanced cases.

Carcinoma cuniculatum oral (CCO): un caso poco habitual en un paciente pediátrico

RESUMEN

El carcinoma cuniculatum oral (CCO) es un tipo de carcinoma escamoso oral poco habitual y frecuentemente mal diagnosticado, del que se han descrito muy pocos casos en la población pediátrica. Presentamos el caso de una niña de 11 años con una lesión de crecimiento

*Autor para correspondencia:

Correo electrónico: mariasocorro.bescos@vallhebron.cat (Coro Bescós-Atín).

<http://dx.doi.org/10.20986/recom.2025.1607/2025>

1527-2024/© 2024 SECOM CyC. Publicado por Inspira Network. Este es un artículo Open Access bajo la licencia CC BY-NC-ND (<http://creativecommons.org/licenses/by-nc-nd/4.0/>).

progresivo en el margen derecho de la lengua. Mediante las pruebas de imagen se detectó un tumor localmente avanzado, y el análisis histopatológico confirmó el diagnóstico de CCO. La paciente se sometió a tratamiento quirúrgico extenso, que incluyó una glosectomía subtotal, disección bilateral del cuello y reconstrucción con un colgajo microvascular del muslo anterolateral. Este caso resalta la importancia de reconocer el CCO en los pacientes jóvenes, así como el papel que desempeña un diagnóstico histopatológico apropiado y el potencial del tratamiento curativo por medios exclusivamente quirúrgicos, incluso en casos avanzados.

INTRODUCTION

Oral carcinoma cuniculatum (OCC) is a rare variant of oral squamous cell carcinoma (OSCC) with a low grade of malignancy. It accounts for approximately 2.7 % of all OSCC cases¹ and is often underdiagnosed due to its similarity to verrucous carcinoma. Unlike OSCC, OCC has no clear association with common risk factors such as tobacco use, alcohol consumption, or human papillomavirus (HPV). Clinically, OCC presents with symptoms similar to OSCC, including pain, ulcers, oedema, and mucosal induration². Histopathological examination is essential for diagnosis, characterized by well-differentiated squamous cells and keratin-filled crypts resembling burrows³. Surgical resection with clear margins is the preferred treatment, with no established benefits from chemotherapy (CT) or radiotherapy (RT). Here, we present a rare case of OCC in a paediatric patient, highlighting its clinical presentation, diagnostic challenges, treatment, and follow-up.

CASE PRESENTATION

An 11-year-old girl with no toxic habits presented with a tumour on the right lingual margin, persisting for one month.

The lesion exhibited slow growth, no ulceration, and no response to anti-inflammatory treatment. Given the persistent and progressive nature of the lesion, an MRI was performed, revealing a 4.2 cm lesion in the right hemitongue. A biopsy conducted in two separate hospitals confirmed a keratinized invasive SCC, well- to moderately differentiated. However, due to the unusual clinical presentation and histopathological findings, further investigation was warranted.

Further histopathological analysis by our pathology department identified a “tumour composed of well-differentiated squamous epithelium with keratin-filled cysts and polymorphonuclear cells inside”, leading to a diagnosis suggestive of OCC. Additional investigations included a second MRI, PET-CT to rule out metastasis, and genetic screening for Fanconi anaemia, dyskeratosis congenita, and Li-Fraumeni syndrome. MRI (Figure 1) showed an infiltrative tumour measuring 3 × 2 × 4 cm, crossing the midline with involvement of the right tongue base. PET-CT detected small metabolic lymph nodes in bilateral level IIa, raising suspicion of nodal involvement. The case was staged as cT4aN2cM0.

Following discussion in the Multidisciplinary Head and Neck Tumour Board, the treatment plan included surgery with bilateral supraomohyoid neck dissection (SOHND). Informed consent was obtained from the patient's family, considering the complexity and potential complications of

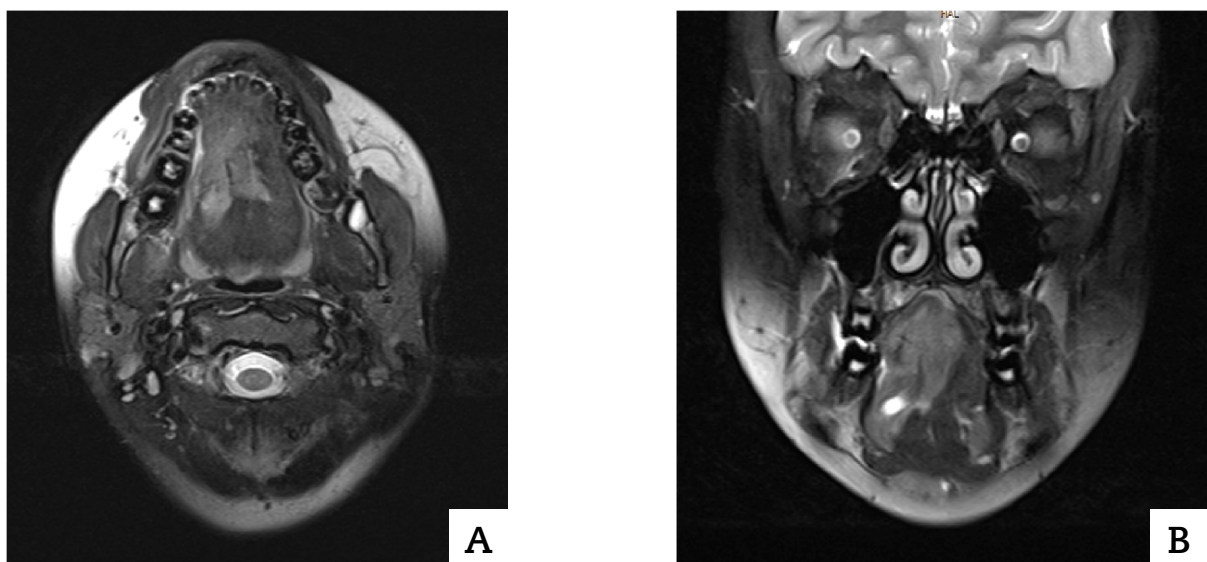


Figure 1. MRI done in our hospital. Axial (a) and coronal (b) cuts of the primary lesion.

the procedure. Ethical and institutional guidelines were followed, with approval from the Institutional Review Board.

Two days before surgery, a tracheostomy and percutaneous gastrostomy were performed to ensure postoperative airway and nutritional support. The surgical procedure involved degloving, lingual pull-through, subtotal glossectomy, preservation of the left tongue base, bilateral floor of mouth resection, and bilateral SOHND. Reconstruction was achieved using an anterolateral thigh (ALT) microvascularized flap (Figure 2), which provided adequate bulk and functionality for oral rehabilitation. Oral feeding resumed 20 days postoperatively.

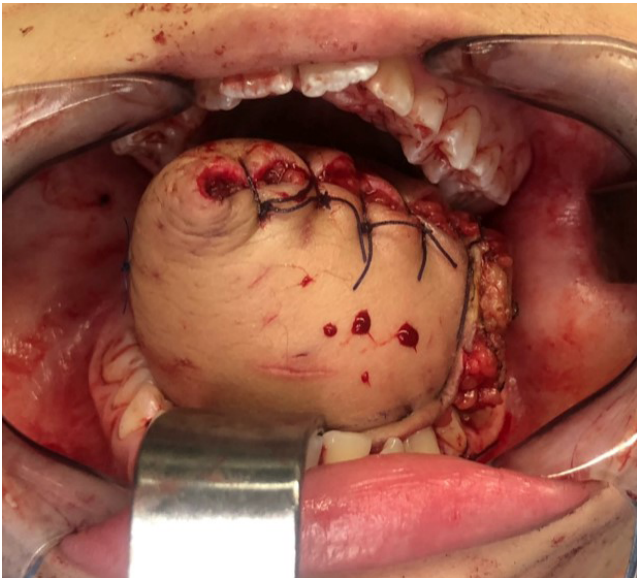


Figure 2. Immediate postoperative stage, where the ALT flap may be seen in its final position.

During hospitalization, the patient experienced complications, including a submental abscess requiring surgical drainage. Additionally, obstructive sleep apnoea developed, for which nighttime continuous positive airway pressure (CPAP) was required. Despite these setbacks, the patient showed gradual improvement, and she was discharged after 50 days.

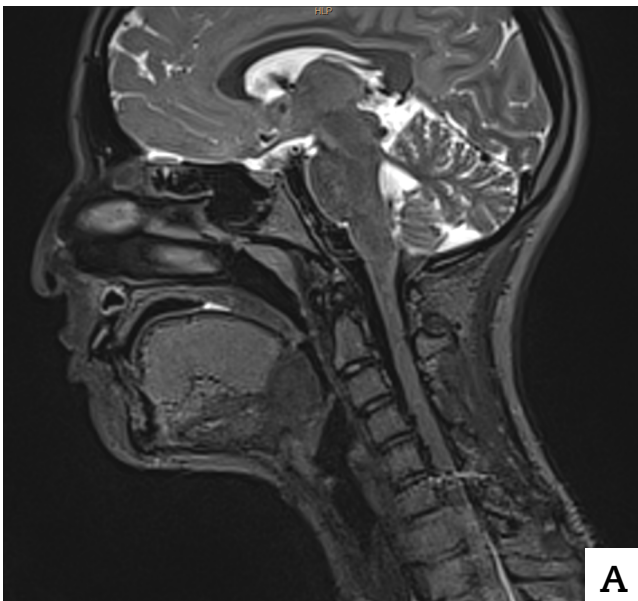
Definitive pathology confirmed the presence of an OCC ($5 \times 4 \times 4.2$ cm) with a 24 mm depth of invasion (DOI), p16-negative, with no perineural or vascular invasion, and no lymph node involvement (0/66). The closest surgical margin was < 1 mm, raising concerns about potential local recurrence. The final staging was pT4aN0M0. Despite recommendations for adjuvant RT due to close margins, the patient and family declined this option, opting for close follow-up instead.

The patient, who lives in another continent, has been followed up remotely via periodic MRI scans and clinical evaluations. After three years, no recurrence has been detected, and she maintains good quality of life with normal oral feeding, speech intelligibility, and social and academic activities. MRI (Figure 3) confirms volume preservation with the ALT flap, and Figure 4 illustrates post-treatment metaplastic changes. The long-term follow-up underscores the potential for surgical management alone in select OCC cases.

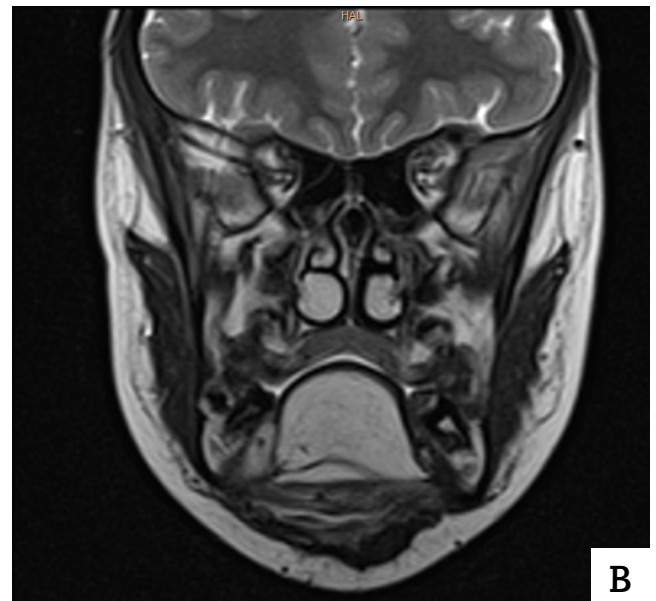
DISCUSSION

OCC is an uncommon OSCC variant, with only 80 cases reported worldwide⁴. Paediatric occurrences are exceptionally rare, with only four previously documented cases⁵⁻⁸. This case represents the fifth paediatric OCC case in the literature, contributing to the understanding of its clinical behaviour in young patients.

OCC is characterized by slow, local invasion with low metastatic potential². It predominantly affects the gingiva, while



A



B

Figure 3. Postop MRI. Sagittal cut (a); Coronal cut (b). Tongue volume obtained by reconstruction with microvascular ALT flap.

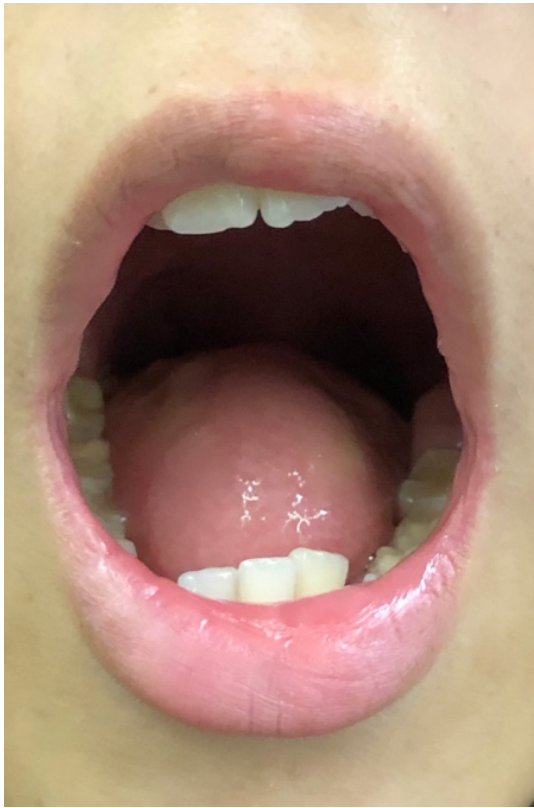

Figure 4. The flap after 24 months, when epithelial metaplasia may be observed.

tongue involvement, as seen in our patient, accounts for only around 20 % of cases³. Unlike OSCC, OCC lacks associations with known risk factors, including tobacco, alcohol, HPV, or premalignant oral lesions^{2,4}. This highlights the need for alternative etiological considerations in paediatric patients.

Histopathological differentiation from chronic inflammatory lesions, OSCC, verrucous carcinoma, and papillary carcinoma is crucial¹. OCC exhibits squamous epithelial proliferation into interconnected, keratin-filled crypts (cuniculatum). Unlike verrucous carcinoma, which has an exophytic growth pattern, OCC usually presents an endophytic or mixed growth pattern, aiding diagnosis³.

Surgical resection with clear margins remains the mainstay of OCC treatment⁹. Elective neck dissection (END) has not demonstrated prognostic benefits and is reserved for cases with suspected nodal involvement⁴. Our decision for bilateral neck dissection was guided by PET-CT findings suggestive of lymph node involvement.

Adjuvant RT or CT has shown no survival benefit^{1,9}. Historically, RT was avoided due to concerns about anaplastic transformation, a misconception stemming from earlier classification overlaps between OCC and verrucous carcinoma¹⁰. In this case, adjuvant RT was proposed due to the close margin, but long-term disease-free survival supports the decision to

forgo additional treatment. OCC has a favourable prognosis compared to OSCC, with minimal risk of distant metastasis. However, in cases where metastasis occurs, prognosis is worse than that of OSCC².

CONCLUSION

OCC is a rare OSCC subtype with distinct clinical and pathological features. Accurate differentiation from verrucous carcinoma is critical due to prognostic implications. Surgical resection with clear margins remains the standard treatment, with neck dissection reserved for clinically suspicious lymph nodes. Adjuvant RT or CT has not demonstrated efficacy. This paediatric case highlights the importance of multidisciplinary management and long-term follow-up, reaffirming the favourable prognosis of OCC when appropriately treated. Continued documentation of OCC cases, particularly in paediatric patients, will be essential in refining diagnostic and therapeutic strategies for this rare malignancy.

REFERENCES

1. Sun Y, Kuyama K, Burkhardt A, Yamamoto H. Clinicopathological evaluation of carcinoma cuniculatum: A variant of oral squamous cell carcinoma. *J Oral Pathol Med*. 2012;41(4):303-8. DOI: 10.1111/j.1600-0714.2011.01116.x.
2. Morouzis C, Toursounidis I, Eftychiadis C, Rallis G. Management and treatment of four cases of oral carcinoma cuniculatum. *J Korean Assoc Oral Maxillofac Surg*. 2024;50(1):35-40. DOI: 10.5125/jkaoms.2024.50.1.35.
3. Farag AF, Abou-Alnour D, Abu-Taleb NS. Oral carcinoma cuniculatum, an unacquainted variant of oral squamous cell carcinoma: A systematic review. *Imaging Sci Dent*. 2018;48(4):233-44. DOI: 10.5624/isd.2018.48.4.233.
4. Yadav S, Bal M, Rane S, Mittal N, Janu A, Patil A. Carcinoma cuniculatum of the oral cavity: A series of 6 cases and review of literature. *Head Neck Pathol*. 2022;16(1):213-23. DOI: 10.1007/s12105-021-01340-6.
5. Flieger S, Owiński T. [Epithelioma cuniculatum an unusual form of mouth and jaw neoplasm]. *Czas Stomatol*. 1977;30(5):395-401.
6. Hutton A, McKaig S, Bardsley P, Monaghan A, Parmar S. Oral carcinoma cuniculatum in a young child. *J Clin Pediatr Dent*. 2010;35(1):89-94. DOI: 10.17796/jcpd.35.1.9qt8601640386651.
7. Lee NV, Ben Kang ET, Senger C, Poh CF. Oral cancer in a 5-year-old boy: A rare case report and review of literature. *Oral Surg Oral Med Oral Pathol Oral Radiol*. 2020;130(1):e10-9. DOI: 10.1016/j.oooo.2019.12.005.
8. Niklander S, Sernuda LM, Martinez R. Unusual case of carcinoma cuniculatum affecting the oral cavity of an 11-year-old boy. *An Bras Dermatol*. 2021;96(6):799-801. DOI: 10.1016/j.abd.2020.08.029.
9. Suzuki J, Hashimoto S, Watanabe K, Takahashi K, Usubuchi H. Carcinoma cuniculatum mimicking leukoplakia of the mandibular gingiva. *Auris Nasus Larynx*. 2011;39(3):321-5. DOI: 10.1016/j.anl.2011.06.004.
10. Delahaye JF, Janser JC, Rodier JF, Auge B. [Carcinoma cuniculatum: 6 cases and review of the literature]. *J Chir (Paris)*. 1994;131(2):73-8.